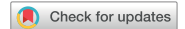

ARTICLE



## Histopathological evaluation of the effect of hyperbaric oxygen therapy on capsule occurrence around silicone breast prosthesis: an experimental study

Serhat Yazar<sup>a,b</sup>, Abdullah Arslan<sup>c</sup>, Bilsev Ince<sup>b</sup>, Mehmet Emin Cem Yildirim<sup>b,d</sup>, Pembe Oltulu<sup>e</sup>, Ilker Uyar<sup>b,f</sup> and Mehmet Dadaci<sup>b</sup>

<sup>a</sup>Konya Numune Hospital, Plastic Reconstructive and Aesthetic Surgery Clinic, Konya, Turkey; <sup>b</sup>Department of Plastic, Reconstructive and Aesthetic Surgery, Meram Faculty of Medicine, Necmettin Erbakan University, Konya, Turkey; <sup>c</sup>Konya Education Research Hospital, Underwater Medicine and Hyperbaric Medicine Clinic, Konya, Turkey; <sup>d</sup>Bilecik State Hospital, Plastic Reconstructive and Aesthetic Surgery Clinic, Bilecik, Turkey; <sup>e</sup>Department of Pathology, Meram Faculty of Medicine, Necmettin Erbakan University, Konya, Turkey; <sup>f</sup>Tokat State Hospital, Plastic Reconstructive and Aesthetic Surgery Clinic, Tokat, Turkey

### ABSTRACT

**Background:** In general, capsular contracture is the underlying cause of complications such as pain, stiffening, breast asymmetry, and animation deformity that are seen in the late postoperative period due to the use of silicone breast prostheses. Considering the positive effects of HBO therapy on wound healing, the objective of this study was to investigate the effect of HBO therapy on capsule reaction occurring due to silicone implants.

**Material and Methods:** Rats were divided into four groups. 1 cm × 1 cm silicone implants with rough surface were inserted in subcutaneous plane on the m spinotrapezius muscle fascia at just right of the dorsal region midline in rats in Group 1, while implants with same properties were inserted beneath m spinotrapezius muscle in rats in Group 2.

Implants with the same properties were inserted in the subcutaneous area on the m spinotrapezius muscle in rats in Group 3 and into the area under the muscle in rats in Group 4. Beginning from the first postoperative day, rats in Groups 3 and 4 received HBO therapy for 90 min under 2.5 ATM pressure as one session a day over 15 days.

**Results:** The mean capsule thickness was statistically significantly lower in the groups treated with HBO compared to the control groups. Fibroblast, neutrophil and macrophage counts were statistically significantly lower in the groups treated with HBO compared to the control groups.

**Conclusion:** We believe that HBO therapy can be used as an adjuvant treatment options to decrease capsule contraction occurring after silicone implant application.

### ARTICLE HISTORY

Received 9 March 2020  
Revised 23 September 2020  
Accepted 14 October 2020

### KEYWORDS

Implants; plastic surgery

### Introduction

Silicone breast prostheses are being used more commonly in breast reconstruction after breast augmentation or mastectomy. In general, capsular contracture is the underlying cause of complications such as pain, stiffening, breast asymmetry, and animation deformity that are seen in the late postoperative period because of the use of silicone breast prostheses [1]. It is a known fact that after foreign bodies are inserted into the body, capsule reaction occurs around them over time. There are many mechanisms and theories in the literature which were revealed about the process of capsule reaction. The most common theory of capsular reaction is a foreign body reaction which is a natural tissue response. Macrophages, T cells, and a variety of cytokines accumulate around a foreign body (implant) as an immune response. Then, the number of proinflammatory cells decreases, and the number of fibroblasts increases around the implant. Thus, a fibrous capsule occurs [2].

According to this principle, it is known that the capsule becomes thick around the silicone implant and is contracted around silicon, causing distortion of the implant [3]. Although several factors such as bacterial colonization, occurrence of

hematoma, implant surface properties, mobilization, and radiation have been proposed as the causes of capsular contracture, its etiology and pathogenesis are still not fully understood [4]. However, it has been argued in the literature that capsule contracture develops by reorganization of collagen around the implant. Many different methods have been tested to prevent development of capsule contracture including irrigation of the pouch with various agents, antibiotherapy, the use of fibrin glue, prevention of possible hematoma, lining the external silicone surfaces with materials of different properties, insertion of the prosthesis in different anatomic localization and even fat grafts, and application of acellular dermal matrix [5,6]. There are studies in the literature that suggest drugs such as triamcinolone, rifampicin, verapamil, and zafirlukast decrease capsule contracture [7–9].

Hyperbaric oxygen (HBO) therapy is a medical treatment that is based on the patient's 100% oxygen inhalation intermittently in a closed-pressure chamber at pressures higher than sea level (1 atmosphere absolute [ATA] = 760 mmHg). Besides positive effects of HBO therapy on wound healing, its anticarcinogenic effects, antibacterial effects, and positive impact on cardiovascular system

have also been reported [10,11]. Oxygen is needed at all stages of wound healing and collagen synthesis.

There is no study in the literature about the effect of HBO therapy on capsule contracture. Considering the positive effects of HBO therapy on wound healing, the objective of this study was to investigate the effect of HBO therapy on capsule reaction that occurred because of silicone implants.

## Material and methods

The study included 60 Wistar Albino female rats of 5 months weighing between 350 and 400g between 2016 and 2017. This study was approved by Necmettin Erbakan University, Meram Faculty of Medicine, Experimental Medicine Research and Training Center Ethics Committee. Rats were divided into four groups. Silicone-textured implants of 1 × 1 cm were placed in subcutaneous plane on the spinotrapezius muscle fascia at just right of the dorsal region midline in Groups 1 and 3, while implants with same properties were placed under the muscle in rats in Groups 2 and 4.

Rats in Groups 3 and 4 were received HBO therapy for 90 min under 2.5 ATM pressure as one session a day over 15 days from the first postoperative day. Groups 1 and 2 were taken as control groups. However, the control groups (Groups 1 and 2) were kept in the HBO chamber for the same time with Groups 3 and 4 without turning on the machine.

All surgical procedures were performed under anesthesia. All rats were housed in separate cages and supplied with rat food and tap water.

All rats were sacrificed with high-dose anesthetic on the post-operative 60th day. All rats were developed capsule reaction around silicone implants, and silicones and capsules were excised en bloc and sent for histopathological examination.

Histopathologically, foreign body reaction, inflammation, granulation tissue, capsule thickness, neutrophil–fibroblast counts, and angiogenesis were evaluated. Five sections were taken from each tissue samples with three being for immunohistochemical studies (leukocyte common antigen (LCA), CD34, and CD68), one for histochemical examination (TRIPLE), and one for hematoxylin and eosin (H&E). The stained slides (LCA, CD34, CD68, TRIPLE, and H&P) were covered with coverslips and examined under light microscope (Olympus Bx51, Melville, NY, USA). Fibrosis, inflammation, and granulation tissue were evaluated with H&E staining. Fibrous tissue was evaluated with Triple method, and capsule thicknesses were measured with a micrometer. Number of vessels per mm<sup>2</sup> were determined with CD34. Inflammatory cell counts were determined with LCA (in ×400 area). Percentages of inflammatory cell types were separately calculated. Macrophage and tissue cells were determined with CD68, and their counts were recorded.

## Statistical analysis

Generalized linear methods were used for the analysis. Statistical analysis was performed using SAS University Edition 9.4 software. The value of  $p < 0.05$  was considered statistically significant.

## Results

The mean capsule thickness was  $186.43 \pm 8.29 \mu\text{m}$  in Group 1,  $159.29 \pm 9.3 \mu\text{m}$  in Group 2,  $65 \pm 5.03 \mu\text{m}$  in Group 3, and  $90.71 \pm 7.05 \mu\text{m}$  in Group 4 after histopathologic examination.

**Table 1.** Cellular and vascular structures of all groups.

	Group 1	Group 2	Group 3	Group 4
Capsule thickness ( $\mu\text{m}$ )	186	159	65	90
Number of neutrophils <sup>a</sup>	6.43	10.14	1.63	5.43
Number of Macrophages <sup>a</sup>	10.57	8.57	7.75	6.71
Number of fibroblast <sup>a</sup>	45.	45	18	16
Angiogenesis <sup>b</sup>	8.71	8.43	14.50	16.71

<sup>a</sup>The mean number of cellular structures seen in a unit microscopic imaging area at 20× magnification.

<sup>b</sup>The mean number of vascular structures in a unit microscopic imaging area at 20× magnification.

The mean fibroblast count was  $45.14 \pm 4.68$  in Group 1,  $45.1429 \pm 4.43$  in Group 2,  $18.75 \pm 5.25$  in Group 3, and  $16.85 \pm 5.4$  in Group 4. The mean macrophage count was calculated as  $10.57 \pm 2.45$  in Group 1,  $8.57 \pm 2.54$  in Group 2,  $7.75 \pm 2.72$  in Group 3, and  $6.71 \pm 2.36$  in Group 4.

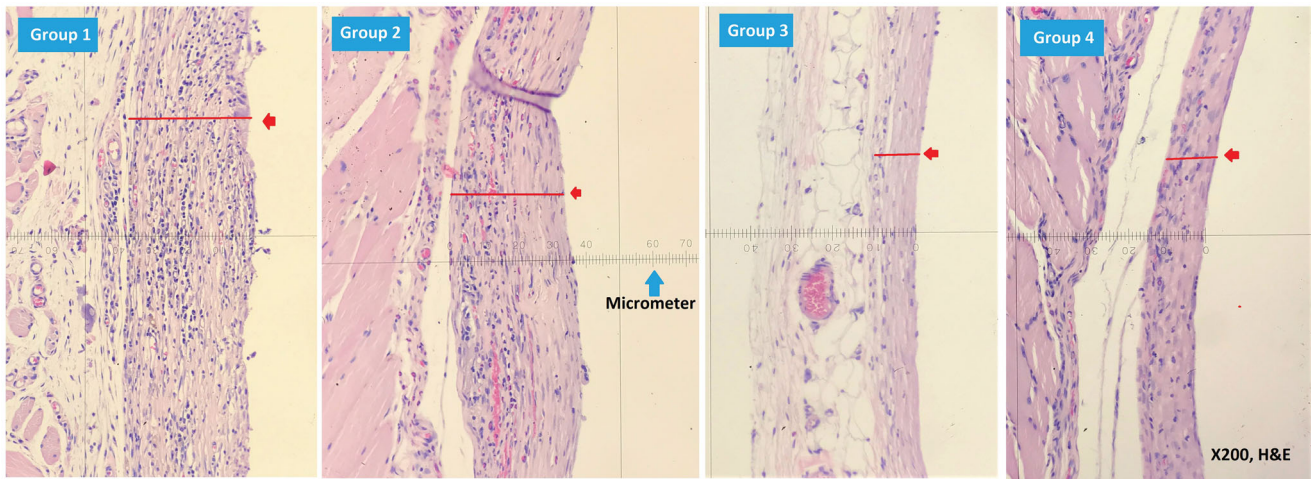
The mean neutrophil count was calculated as  $6.43 \pm 1.94$  in Group 1,  $10.14 \pm 2.27$  in Group 2,  $1.63 \pm 0.87$  in Group 3, and  $5.43 \pm 1.65$  in Group 4. Neovascularization score measured from different areas within the tissue section was calculated as  $8.71 \pm 2.26$  in Group 1,  $8.42 \pm 2.22$  in Group 2,  $14.5 \pm 3.1$  in Group 3, and  $16.71 \pm 3.28$  in Group 4.

The mean capsule thickness was found to be statistically significantly lower in the groups treated with HBO compared to the control groups ( $p < 0.0118$ ) (Figure 2). Fibroblast, neutrophil, and macrophage counts were statistically significantly lower in the groups treated with HBO compared to the control groups ( $p < 0.0002$ ). Neovascularization was found to be statistically significantly higher in the groups treated with HBO compared to the control groups ( $p < 0.0045$ ). However, no significant difference was found between the treatment and control groups in terms of capsule thickness, neovascularization, and cell counts according to the localization of the implant insertion ( $p > 0.05$ ) (Table 1 and Figure 1).

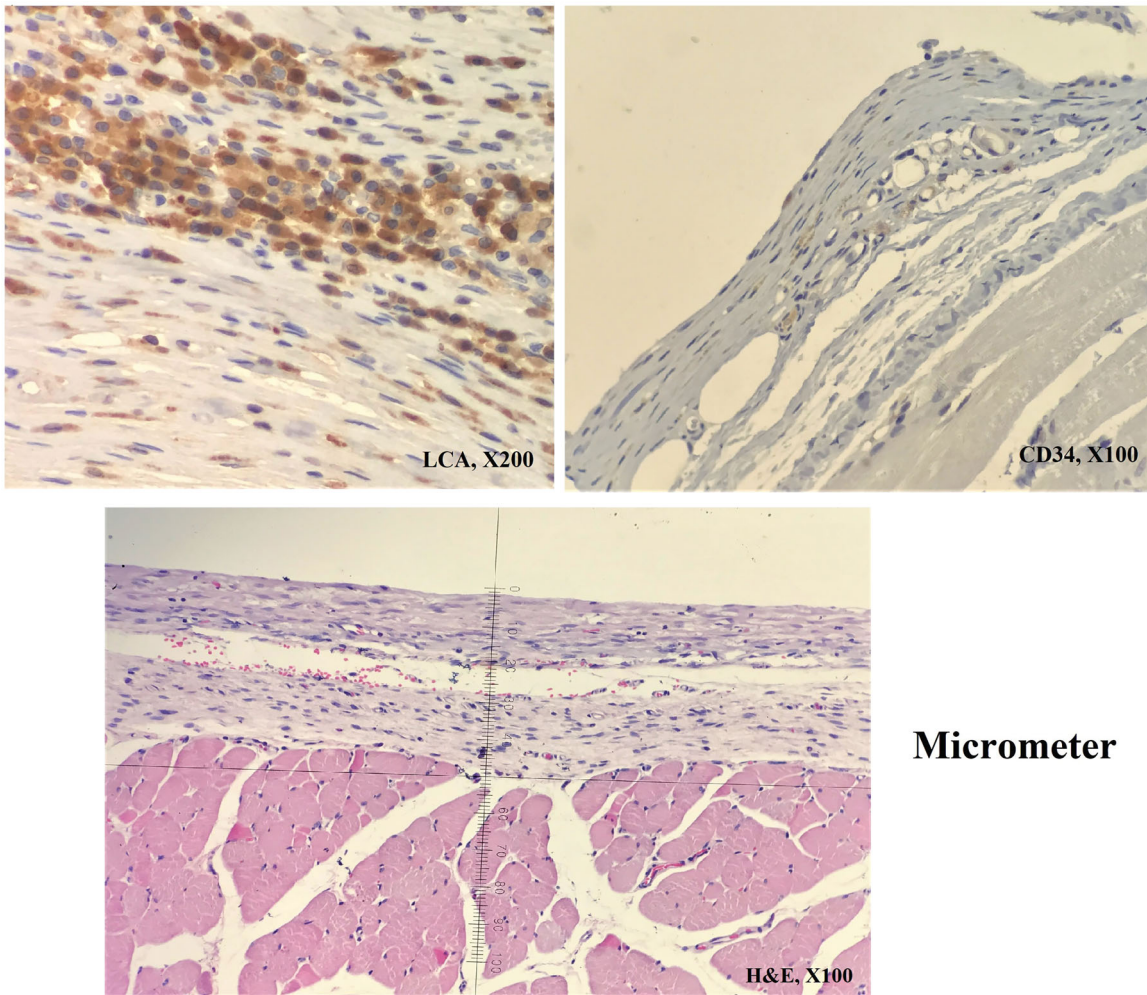
## Discussion

The number of studies conducted on prevention of implant complications increased with the increased use of implants. Capsule, the most important one of these complications, is defined as a scar tissue against foreign body with contraction feature [3]. Fibroblasts found in the capsule tissue, which occur around implants that are not absorbed in the body, are cells that play a role in the release of collagen, glycosaminoglycans, and fibronectin. In 2012, Wolfram *et al.* revealed the types of lymphocytes concentrated around the implant and demonstrated that CD4 cells were more intense around the implant compared to peripheral blood. The authors also suggested that the production of T cells, IL-6, 8, 17, and TGF- $\beta$ 1 increases around the implant [8]. High amount of CD3/CD68<sup>+</sup> histiocytes were found around the implant, and these histiocytes were demonstrated to synthesize growth factors and fibroblast-stimulating cytokines [12].

Rates of capsule contractures have been reported between 1.3% and 30% in the literature. The longer the implants are found in the body, the greater the cumulative risk of developing contractures of which approximately 92% will occur within the first 12 months of the surgery [13,14]. The risk of capsular contraction was reported to be higher when the implant was inserted in the subglandular area than in the submuscular plane [15]. These data are consistent with the assumption that anatomic localization is a risk factor for developing capsular contraction [9,16,17].



**Figure 1.** Comparison of capsular thicknesses, hematoxylin eosin (upper left: Group 1, upper right: Group 2, lower left Group 3, lower right: Group 4). Images were acquired by 20× magnification, and existing thickness values were multiplied with 5, and ractual thickness values were recorded in micrometers.



**Figure 2.** View of the measurement of capsule thickness, inflammatory cells and capillary vessels. In this example: the capsule thickness, 45 micrometer; inflammatory cell count, >50; capillary vessel: 24..

Intraluminal methylprednisolone therapy had been performed in rats in order to reduce capsule formation, and capsule was found thinner in the treatment group compared to the controls. The reduction of noncollagenous proteins found in the capsular

structure had been proposed as a mechanism of action for this situation [18].

Viriden *et al.* reported that 56% of patients with capsular contraction were culture positive with *Staphylococcus epidermidis* [19].



However, when the implant pouch was irrigated with 5% povidone-iodine and cephalosporin with bacitracin, the desired permanent result could not be achieved [6,20].

Irkören *et al.* argued that botulinum toxin A (BTXA) decreased capsule thickness, reducing capsular contraction [21]. Another study reported that capsule thickness was found to be reduced on MRI imaging in patients who had undergone subpectoral breast augmentation by the injection of BTXA into the pectoralis muscle [22]. Systemic enalapril therapy had been proposed in an experimental study to decrease inflammatory and fibrotic processes in the periprosthetic tissue of both rough and smooth implants [23]. Gancedo *et al.* reported that systemic treatment with pirfenidone (PFD) decreased TGF- $\beta$ 1 levels and capsular thickness.

Many phases of wound healing depend on oxygen. Cells around the wound need energy to proliferate and make protein synthesis. Collagen is the most important element of connective tissue and wound healing. Collagen accumulation on wound surface is associated with oxygen pressure. Tissue hypoxia secondary to low oxygen pressure reduces collagen synthesis from fibroblasts. The modification of collagen occurs with hydroxylation of protein debris with prolyl hydroxylase enzyme, which is an oxygen-dependent enzyme. Connective tissue strengthens with cruciate ligaments that form between collagen fibers [10,11] as a result of hydroxylation. The positive effects of HBO therapy on wound healing are well known. We found this positive effect in Groups 3 and 4, and believed that HBO therapy could decrease foreign body reactions in the body.

Capsule thickness was found to be lower in our study both in submuscular and supramuscular planes in the groups that received HBO treatment. Positive effect of HBO therapy on capsule thickness was found to be higher in the subcutaneous supramuscular group (Group 3). Capsule thickness was found to be lower in Group 3 compared to Group 4, but the difference was not statistically significant ( $p > 0.05$ ). Capsule thickness was also found to be lower in Group 3 that received HBO therapy compared to the control groups. While there was already a strong circulation in submuscular plane, circulation which was lower in supramuscular plane was increased by HBO therapy. Lower capsular thickness was attributed in Groups 3 and 4 compared to Groups 1 and 2 to positive effects of HBO therapy on inflammatory process in the early period and on collagen synthesis and sequencing in the intermediate and late periods.

In this experimental study, we determined that HBO therapy decreased capsular thickness and tissue reaction and increased angiogenesis around the breast implant. In this context, we believe that HBO therapy can be used as a preventive treatment option to decrease capsule contraction that occurred after silicone implant.

### Disclosure statement

No potential conflict of interest was reported by the authors.

### References

- [1] Gabriel SE, Woods JE, O'Fallon WM, et al. Complications leading to surgery after breast implantation. *N Engl J Med.* 1997;336(10):677–682.
- [2] Bachour Y, Verweij SP, Gibbs S, et al. The aetiopathogenesis of capsular contracture: a systematic review of the literature. *J Plast Reconstr Aesthet Surg.* 2018;71(3):307–317.
- [3] Skillman JM, Ahmed O, Rowsell AR. Incidental improvement of breast capsular contracture following treatment of arthritis with glucosamine and chondroitin. *Br J Plast Surg.* 2002; 55(5):454.
- [4] Lipa JE, Qiu W, Huang N, et al. Pathogenesis of radiation-induced capsular contracture in tissue expander and implant breast reconstruction. *Plast Reconstr Surg.* 2010; 125:437–445.
- [5] Wyatt LE, Sinow JD, Wollman JS, et al. The influence of time on human breast capsule histology: Smooth and textured silicone-surfaced implants. *Plast Reconstr Surg.* 1998; 102:1922–1931.
- [6] Burkhardt B, Dempsey P, Schnur P, et al. Capsular contracture: a prospective study of the effect of local anti-bacterial agents. *Plast Reconstr Surg.* 1986;77(6): 919–932.
- [7] Bastos EM, Neto MS, Alves MTS, et al. Histologic analysis of zafirlukast's effect on capsule formation around silicone implants. *Aesthetic Plast Surg.* 2007; 31(5):559–565.
- [8] Wolfram D, et al. T regulatory cells and TH17 cells in perisilicone implant capsular fibrosis. *Plast Reconstr Surg.* 2012; 129(2):327e–337e.
- [9] Pereira LH1, Sterodimas A. Transaxillary breast augmentation: a prospective comparison of subglandular, subfascial, and submuscular implant insertion. *Aesthetic Plast Surg.* 2009;33(5):752–759. Sep
- [10] Ince B, Arslan A, Dadaci M, et al. The effect of different application timings of hyperbaric oxygen treatment on nerve regeneration in rats. *Microsurgery.* 2016;36(7): 586–592.
- [11] Arslan A, Dikici f, Purisa S, et al. Investigation of the short-term effects of hyperbaric oxygen therapy in avascular necrosis of the femoral head. *Selcuk Med. J.* 2019;35(2): 77–82.
- [12] Kamel M, Protzner K, Fornasier V, et al. The peri-implant breast capsule: An immunophenotypic study of capsules taken at explantation surgery. *J Biomed Mater Res.* 2001; 58(1):88–89.
- [13] Handel N, Cordray T, Gutierrez J, et al. A long-term study of outcomes, complications, and patient satisfaction with breast implants. *Plast Reconstr Surg.* 2006; 117:757–767. discussion 768–772.
- [14] Araco A, Gravante G, Araco F, et al. A retrospective analysis of 3,000 primary aesthetic breast augmentations: postoperative complications and associated factors. *Aesth Plast Surg.* 2007;31(5):532–539.
- [15] Strasser EJ. Results of subglandular versus subpectoral augmentation over time: one surgeon's observations. *Aesthet Surg J.* 2006;26(1):45–50.
- [16] Stoff-Khalili MA, Scholze R, Morgan WR, et al. Subfascial periareolar augmentation mammoplasty. *Plast Reconstr Surg.* 2004;114:1280–1288. discussion 1289Y9.
- [17] Egeberg MD, Sørensen JA. MD the impact of breast implant location on the risk of capsular contraction Alexander, PhD. *Annals of Plastic Surgery.* 2016;77(2): 255–259.
- [18] Sieminski AL, Gooch KJ. Biomaterial-microvasculature interactions. *Biomaterials.* 2000;21(22):2233–2241.
- [19] Virden CP, Dobke MK, Stein P, et al. Subclinical infection of the silicone breast implant surface as a possible cause of capsular contracture. *Aesthetic Plast Surg.* 1992;16(2): 173–179.

- [20] Shah Z, Lehman JA, Stevenson G. Capsular contracture around silicone implants: the role of intraluminal antibiotics. *Plast Reconstr Surg.* 1982; 69(5):809–814.
- [21] Irkoren S, Ozkan HS, Ceylan E, et al. Effect of botox on the implant stabilization and capsular formation an experimental study. *Annals of Plastic Surgery.* 2015;75(1): 91–97.
- [22] Xiao Z. Effect of botulinum toxin type A on the capsule around a subpectoral implant for breast augmentation. *Aesth Plast Surg.* 2009;33(5):782–783. Y
- [23] Zimman OA, Tobllı J, Stella I, et al. The effects of angiotensin-converting-enzyme inhibitors on the fibrous envelope around mammary implants. *Plast Reconstr Surg.* 2007;120: 2025–2033.