

ARTICLE

## Lateral supramalleolar flap for soft-tissue coverage of ankle and foot defects

Thach Ngoc Nguyen<sup>a</sup>, Tuong Trong Mai<sup>a</sup>, Thi Cao<sup>b</sup> and Truc Thanh Thai<sup>c</sup>

<sup>a</sup>Microsurgery and Limb Reconstruction Department, Hospital for Traumatology and Orthopedics, Ho Chi Minh City, Ho Chi Minh City, Vietnam;

<sup>b</sup>Orthopedic and Rehabilitation Department, University of Medicine and Pharmacy at Ho Chi Minh City, Ho Chi Minh City, Vietnam;

<sup>c</sup>Department of Medical Statistics and Informatics, University of Medicine and Pharmacy at Ho Chi Minh City, Ho Chi Minh City, Vietnam

### ABSTRACT

The reconstruction of soft tissue defects in the foot and ankle remains a big challenge due to the anatomical characteristics of this area. This study evaluated the long-term effectiveness of covering by lateral supramalleolar flap in patients with soft tissue defects around the ankle and foot. We conducted a retrospective study from January 2017 to December 2020 at the Hospital for Traumatology and Orthopedics, Ho Chi Minh City, Vietnam. Data about patients' characteristics, detailed injuries, perioperative information, intraoperative dossier, and complications of this method were recorded and analyzed. There were 31 male and 17 female patients, with an average age of 39.8 (ranging from 11 to 77) years. The skin defects ranged from 8 cm<sup>2</sup> to 120 cm<sup>2</sup>. The blood supply for the flap included a mixed-flow pattern ( $n = 30$ ) and retrograde flow ( $n = 18$ ). The success rate was 94%. Forty-two patients had been successfully covered, five patients had partial flap necrosis (in which two cases needed skin graft afterwards and three cases got spontaneous healing), only one patient had total flap necrosis. In conclusion, the lateral supramalleolar flap can cover the soft tissue of ankle and foot defects in both mixed-blood supply pattern or retrograde pattern with high success rates. However, the risk of venous congestion should be considered, particularly when using the retrograde pattern flap.

### ARTICLE HISTORY

Received 27 June 2022  
Accepted 24 November 2022

### KEYWORDS

Pedicle flap; island flap;  
foot and ankle

### Introduction

In 1988, Masquelet was the first to describe a lateral supramalleolar flap, raised from the lateral side of the lower leg and used as a distally pedicled flap, thereby giving one more option of locoregional flaps for coverage of the ankle and foot [1,2]. The reconstruction of these areas remains a tough challenge for plastic surgeons due to the anatomical characteristics of this area, the poor soft-tissue mobility, and defects affecting joints, tendons, or even bone [3,4]. A previous study by Gong Xu et al. demonstrated that flaps used to cover these areas must satisfy several requirements such as skin matched with the recipient site, no loss of any major artery, and minimal effect on the donor site [5]. Basheer et al. reported that failure rates of free flap in the reconstruction of the lower limb are as high as 15–20% [6]. Teo et al. suggested using propeller flaps to cover the foot and ankle with a quicker operation and limited resources required than a free flap. However, this method has a rate of venous congestion and partial flap loss of up to 35% [7]. To optimize the reconstruction of soft tissue defects around one-third of the lower leg, some researchers have used the lateral supramalleolar flap with a high success rate [8]. Using this method, Hamdi followed eight patients up to 31 months and found no necrosis flap [9].

The lateral supramalleolar flap can be used for mixed flow and retrograde flow patterns due to anatomical characteristics of the blood supply. This is a fasciocutaneous flap that is vascularized by branches of the perforating branch of the peroneal artery. This perforating branch is a constant branch, emerging 5 cm above the lateral malleolus and has two or three ascending cutaneous branches and a deep descending branch [1]. These ascending branches perforate the fascia and supply the skin over the lateral

of the lower leg. With ascending branches, surgeons can design a mixed flow pattern flap. The descending branch runs distally under the deep fascia, anastomoses to the anterolateral malleolar branch of the tibialis anterior artery. Based on the descending branch, the flap can be used as a retrograde flow pattern.

In 1991, Valenti et al. modified the original flap as a skin flap with fasciocutaneous pedicle, including the deep fascia. This technical refinement helps design a flap more proximally on the lateral aspect of the leg and thus can cover further, distal on the foot with only a mixed blood supply pattern [10]. Jae-Hoon Lee and Young Ho Lee described a reverse lateral supramalleolar adipofascial flap and skin grafting to minimize the morbidity rate of the donor site [11,12]. In Vietnam, a local unpublished study from 1998 to 2007 investigated the clinical results and efficacy of lateral supramalleolar flap to cover soft-tissue defects around the ankle in 20 patients and reported good initial outcomes. In that study, there were 17 flaps designed as mixed flow, and 3 others as retrograde blood supply flow. There were three patients with partial necrosis (two patients in retrograde group and one patient in mixed pattern), 17 patients with successful outcomes [13]. This study evaluated the long-term effectiveness of covering by lateral supramalleolar flap in patients with soft tissue defects around the ankle and foot. Findings from this study can help surgeons in decision-making based on real-life clinical evidence to optimize the surgical outcomes.

### Materials and methods

#### Settings and participants

This retrospective study was conducted from January 2017 to December 2020 at the Hospital for Traumatology and

Orthopedics, Ho Chi Minh City, Vietnam. At the hospital, patients with soft tissue injuries, either with or without bone fractures, are admitted to the Microsurgery and Limb Reconstruction Department. The average number of lower limb reconstructive cases that needed to be covered by a flap is about 40 per month, of which one-third are soft tissue defects in the ankle and foot. The lateral supramalleolar flap has been used in the hospital since 2000 and has become a typical reconstruction method for recovering skin defects in the ankle and foot.

During the study period, we collected data from all 48 patients who underwent lateral supramalleolar flap surgery to cover soft-tissue defects around the ankle and foot. We included patients who had ulcers or an injury with exposure of bone, tendon, artery, and nerve, which needed to be covered by flaps. Patients with any peripheral vascular disease, diabetes, and extensive crush injury of the lateral part of the distal third of the leg were excluded.

### Study procedures

Ethical approval was granted by the University of Medicine and Pharmacy at Ho Chi Minh City (280/HĐĐĐ-ĐHYD) and the Hospital for Traumatology and Orthopedics at Ho Chi Minh City.

When patients with soft-tissue defects around the ankle and foot came to the hospital, they had initial treatment by general wound care and were treated with antibiotics. For those cases, superficial lacerations heal spontaneously, and a skin graft can be used for tiny wounds with suitable granulation. The damage with exposure of tendons, nerves, vascular, and bones was treated by a flap. The use of regional pedicle flaps was preferred versus free flaps because of more straightforward techniques, and in this region, we used the lateral supramalleolar flap.

### Measurement

Patient's characteristics including gender, age were collected. Details of injuries, perioperative data, intraprocedural dossier, and complications such as partial and complete flap loss were also recorded. Based on practice from previous studies, the success criterion used in this study was full coverage of the injury by a flap in only one procedure. Some successful cases might extend hospitalization time for post-operation wound care and minor surgery to close the edge of the flap with the recipient site. Failure criteria included total necrosis flap and partial necrosis cases which could not be surmounted by wound care and minor surgery and required a second operation using an alternative flap or skin graft (Figure 1).

### Operative technique

In this study, the lateral supramalleolar flap with mixed blood supply pattern was used (Figure 2). The skin defect was measured after debridement. The pivot point which is the emergence point of the perforating branch of the peroneal artery was marked on the surface of lateral lower leg site. In this study, we did not use the ultrasound or Doppler Echo device to identify this point. Instead, we followed guideline by Masquelet. As such, in our study, the emergence point of the perforating branch of the peroneal artery was about 5 cm superior to the lateral malleolus around the groove between the tibia and the fibular. A midline from the anterior tibial crest to the fibula's posterior margin as the axis of the flap was drawn. The distance from the pivot point to the closest edge of the skin defect to design the flap on the

skin surface of the donor site was calculated. The width of subcutaneous pedicle was at least 3 cm to optimize venous return by counting superficial veins.

An incision was made anterior and proximal edges of the flap up the fascia, which was then incorporated into the anterior border of the pedicle. Blunt dissection was conducted under the fascia until the perforating branch was identified distally. The flap was then raised in a retrograde position right after the posterior incision. Hemostasis was conducted carefully to avoid edema after the surgery. The flap was then transferred to the edges of the skin defect.

With respect to retrograde pattern, the surface landmark of pivot point was the intersection of the line connecting two malleoli and the fourth metatarsal axial in general. We could create a longer pedicle by continuing descending branch dissection, until this branch was anastomosed with the anterolateral malleolar artery. In these cases, the pivot point was ahead of the ankle or up to the tarsal region. The perforating branch was tied and split out of the peroneal artery and harvested the flap using the same technique as above (i.e. the mixed-blood supply pattern). To avoid stress on the under skin tunnel, we incised the ceiling skin of the tunnel and elevated 3 cm wide of subcutaneous pedicle with 1 cm of skin in the middle of the pedicle. When we set the pedicle to the incised tunnel, we sutured the ceiling skin to this 1 cm skin of pedicle to reduce stress and avoid skin graft on the subcutaneous pedicle.

The donor site could be sutured or applied with a split-thickness skin graft. The dressing was completed while maintaining an observation window over the flap. A plaster splint was prepared and used if necessary.

### Post operative follow up

We carefully observed the flap with every 8 h in the first 24 h. When there were any signs of venous congestion, we cut the flap setting suture up to a haft of flap circle and one side of ceiling tunnel skin suture to reduce the stress on the subcutaneous pedicle and the flap immediately. When there was no venous congestion, we changed gauze dressing daily and checked vital flap signs for 5 days. The patients were discharged after 5 days if they had the stable flap, and were followed up after 1 week. If the patients had flap necrosis, they underwent a second surgery to debride the necrotic part. Then, we did a skin graft.

### Data analysis

Qualitative data such as gender, leg site, associated injuries, location of the defect, causes of injury, blood supply pattern, the variant of blood supply, methods used to set pedicle, donor site intervention, flap outcomes were described using frequency and percentages. To describe quantitative data such as age, size of the injury, flap size, surgery duration, mean (standard deviation) or median (inter-quartile range) were used when appropriate. All data analyses were conducted using Stata, version 16.

### Results

Among 48 patients who underwent lateral supramalleolar flaps, nearly two-thirds were males, and the median age was 39.8 (ranging from 11 to 77) years (Table 1). There were various reasons for leg, ankle, and foot skin effects, including traffic accidents (41/48 = 86%), ulcers (4/48 = 8%), and daily accidents (3/48 = 6%). Associated injuries included fractures (18/48 = 37.5%), tendon

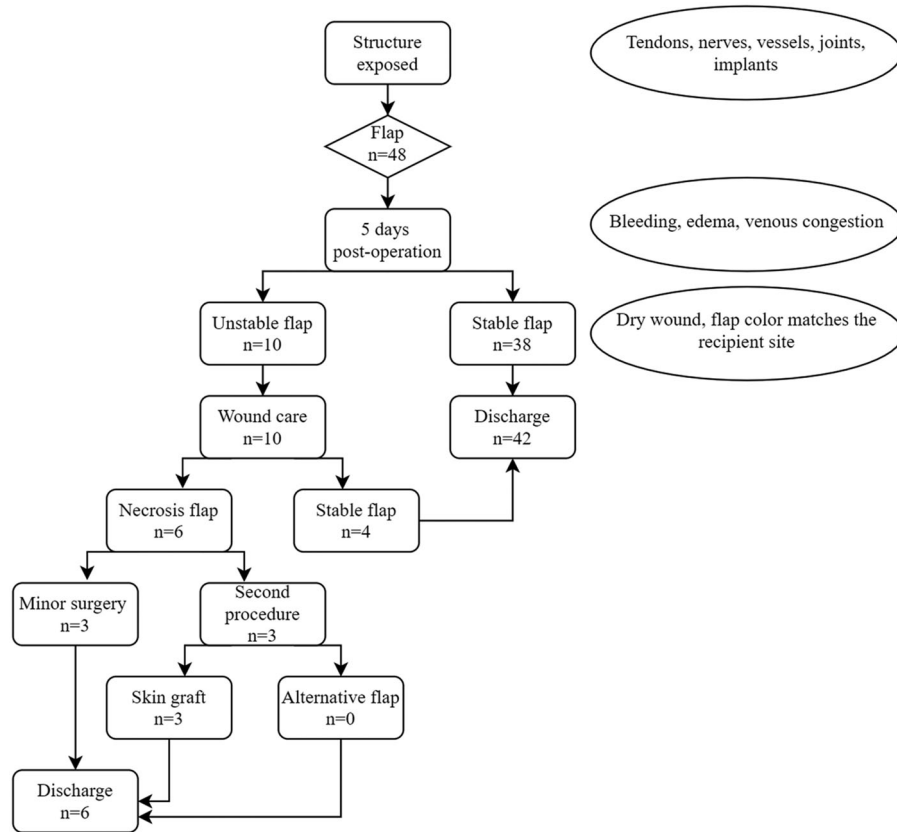


Figure 1. General algorithmic approach to cover soft tissue defects by lateral supramalleolar flap.

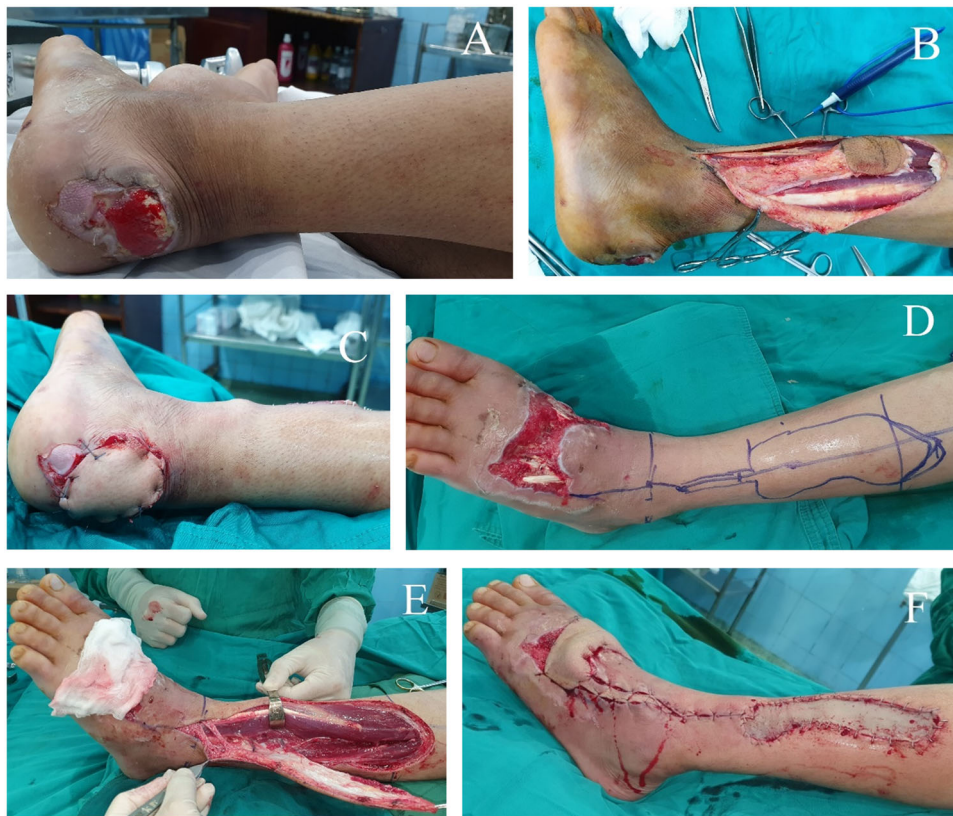

Figure 2. Intraoperative photographs of elevated flaps. (A–C) The mix blood supply pattern with subcutaneous pedicle, using under skin tunnel technique to inset the pedicle. (D–F) The retrograde manner with 3 cm wide subcutaneous pedicle, including 1 cm skin in the middle of the pedicle, incised ceiling skin tunnel to inset the pedicle.

**Table 1.** Characteristics of patients underwent lateral supramalleolar flap at Hospital in Traumatology and Orthopedic, Ho Chi Minh City in 2017–2020.

Variables	Total, <i>n</i> (%)	Defect location				
		Ankle <i>n</i> = 11, 22.9%	Heel <i>n</i> = 10, 20.8%	Midfoot <i>n</i> = 12, 25%	Forefoot <i>n</i> = 8, 16.7%	Mid-Forefoot <i>n</i> = 7, 14.6%
Age, year						
<20	7 (14.6)	0 (0.0)	2 (20.0)	3 (25.0)	0 (0.0)	2 (28.6)
20–60	36 (75.0)	9 (81.8)	7 (70.0)	8 (66.7)	7 (87.5)	5 (71.4)
>60	5 (10.4)	2 (18.2)	1 (10.0)	1 (8.0)	1 (12.5)	0 (0.0)
Gender						
Male	31 (64.6)	6 (54.5)	6 (60.0)	8 (66.7)	6 (75.0)	5 (71.4)
Female	17 (35.4)	5 (45.5)	4 (40.0)	4 (33.3)	2 (25.0)	2 (28.6)
Leg site						
Left	20 (41.7)	5 (45.5)	3 (30.0)	6 (50.0)	4 (50.0)	2 (28.6)
Right	28 (58.3)	6 (54.5)	7 (70.0)	6 (50.0)	4 (50.0)	5 (71.4)
Cause of injury						
Traffic	41 (85.4)	8 (72.7)	9 (90.0)	10 (83.3)	8 (100.0)	6 (85.7)
Daily activities	3 (6.3)	2 (18.2)	1 (10.0)	0 (0.0)	0 (0.0)	0 (0.0)
Ulcer	4 (8.3)	1 (9.1)	0 (0.0)	2 (16.7)	0 (0.0)	1 (14.3)
Injury size (cm <sup>2</sup> ) [Mean & SD]	28.4 (23.2)	19.1 (8.3)	16.8 (5.7)	35.7 (25.8)	20.3 (9.1)	56.2 (35.4)
Flap size (cm <sup>2</sup> ) [Mean & SD]	31.3 (17.3)	24.2 (10.5)	21.3 (6.5)	34.5 (19.9)	27.3 (12.3)	55.7 (14.2)
Blood pattern						
Mix	30 (62.5)	10 (90.9)	10 (100)	8 (66.7)	1 (12.5)	1 (14.3)
Retrograde	18 (37.5)	1 (9.1)	0 (0.0)	4 (33.3)	7 (87.5)	6 (85.7)
Pedicle inset						
Open	23 (47.9)	4 (36.4)	3 (30.0)	8 (66.7)	4 (50.0)	4 (57.1)
Tunneled	25 (52.1)	7 (63.6)	7 (70.0)	4 (33.3)	4 (50.0)	3 (42.9)
Donor site intervention						
Skin graft	39 (81.3)	9 (81.8)	7 (70.0)	9 (75.0)	8 (100)	6 (85.7)
Sutured	9 (18.8)	2 (18.2)	3 (30.0)	3 (25.0)	0 (0.0)	1 (14.3)
Surgery duration (minutes) [Mean & SD]	82.1 (26.7)	60.5 (15.6)	90.0 (38.9)	79.6 (20.1)	90.6 (19.5)	99.3 (16.9)
Flap outcome						
Survival	42 (87.5)	10 (90.9)	7 (70.0)	11 (91.7)	8 (100)	6 (85.7)
Partial necrosis	5 (10.4)	1 (9.1)	2 (20.0)	1 (8.3)	0 (0.0)	1 (14.3)
Complete necrosis	1 (2.1)	0 (0.0)	1 (10.0)	0 (0.0)	0 (0.0)	0 (0.0)

lesions (10/48 = 20.8%), and soft-tissue defects (20/48 = 41.7%). The average size of the injury was 28 cm<sup>2</sup> (ranging from 8 cm<sup>2</sup> to 120 cm<sup>2</sup>). The mean size of skin flap was 31 cm<sup>2</sup> (ranging from 10 cm<sup>2</sup> to 72 cm<sup>2</sup>). The mean surgical duration was 82 min (range from 30 to 180 min). The average follow-up period was 10.2 (range from 3 to 27) months.

In our study, there was only one patient who had total flap necrosis. This was a 77-year-old woman who had a traffic accident resulting in a heel defect and was treated with a sural flap. However, the sural flap was totally necrotic before going to our reconstruction department. The injury was then covered with a lateral supramalleolar flap and was total necrotic. The patients underwent a second operation to have a skin graft which was then fully healed (Figure 3).

There were five patients with partial flap necrosis, two of whom needed an alternative reconstruction method. The first patient was 43 years old with a heel defect from a traffic accident. After being treated by the lateral supramalleolar flap with a mixed blood supply pattern, the result was partial flap necrosis. The patient underwent a second operation for a split skin graft and had fully coverage afterward. The second patient was 41 years old man with an injury at his midfoot. He was first treated by the lateral supramalleolar flap with retrograde blood flow, resulting in partial flap necrosis. He had to undergo a quick operation to graft the split skin. The patient had a fully coverage result. The other three patients with partial flap necrosis were treated with wound care and minor surgery.

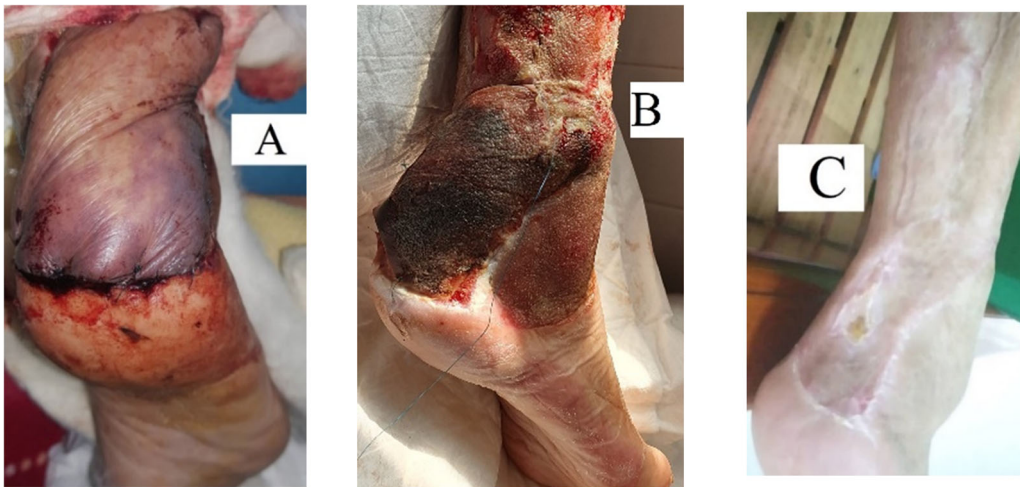
The overall success rate was 94% (*n* = 45/48). In terms of long-term outcome, the flaps had the same color as the skin nearby, and some cases (20/48 = 41.7%) had the same texture and thinness as the dorsal skin foot (Figure 4). The skin grafts in the donor site were healing spectacularly, and no tendon adhesion occurred.

Table 2 presents results from different blood supply patterns (i.e. mixed flow and retrograde flow). The success rate was not different between the mixed flow group (86.6%) and retrograde group (88.9%). Moreover, there were several variants of blood supply observed in this study (*n* = 3), two in the mixed flow group and one in the retrograde group.

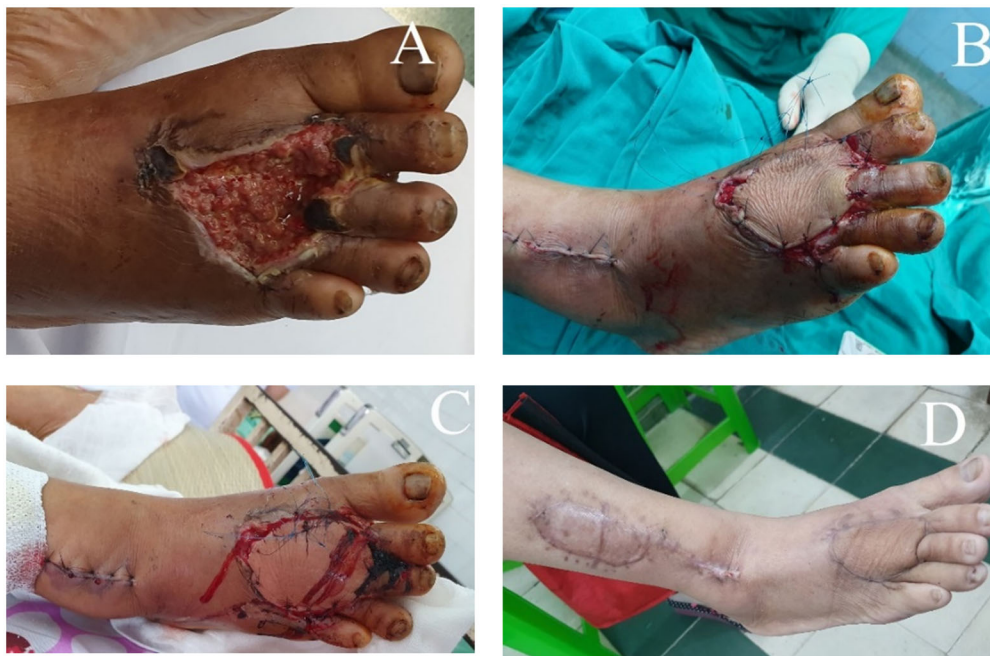## Discussion

The lateral supramalleolar flap can be used in two different patterns depending on the blood supply flow, including mixed and retrograde blood flow [1,14]. In our study, we applied both approaches. However, more patients were treated with mixed flow blood supply than retrograde flow blood supply because we had more patients with injuries in the ankle and heel than forefoot and mid-forefoot. This finding is reasonable since these injuries are more common and is consistent with what is reported in the literature. For example, Voche et al. reported significantly more mixed flow blood supply than retrograde blood flow flap [15]. This is similar in another study by Nambi et al. with only 3/20 (15%) patients treated with the retrograde flow blood supply approach [16]. Fortunately, in our study, we found a high rate of success, similar in both mixed and retrograde flow blood supply. One possible reason for this high success rate is the inclusion of patients with a relatively small defect size. Our results are encouraging compared to the study by Nambi et al. where all patients (*n* = 3) treated with retrograde flow blood supply in that study had total necrosis. Our findings indicate that retrograde flow blood supply is suitable to cover soft tissue defects in forefoot and mid-forefoot with a high successful rate. However, as reported in the literature, retrograde flow pattern is a complicated elevated procedure that requires isolating a deep descending branch reaching the anterolateral malleolar artery around the





**Figure 3.** The total necrosis of flap and healing outcome with the split skin graft procedure. (A) Unstable flap with venous congestion, (B) Necrosis of the flap, (C) Healing after skin graft.



**Figure 4.** The forefoot defect was treated by a retrograde flow pattern and got successfully. (A) a wound in the forefoot, (B) Flap inset given, (C) Flap stable in 3 days after the surgery, (D) Late postoperative view.

**Table 2.** Characteristic of the flap in two blood supply groups in patients who underwent lateral supramalleolar flap at Hospital in Traumatology and Orthopedic, Ho Chi Minh City in 2017–2020.

Characteristic flap	Size N (%)	Result					Variant of blood supply N (%)	Donor site		Intervention	
		100% Flap alive N (%)	100% Necrosis N (%)	Partial flap necrosis		Sutured N (%)		Skin graft N (%)	Emergency N (%)	Elective N (%)	
				Wound care N (%)	Skin graft N (%)						
Mixed flow	30 (62.5)	26 (86.6)	1 (3.3)	2 (6.6)	1 (3.3)	2 (6.6)	8 (26.6)	22 (73.3)	1 (3.3)	29 (96.7)	
Retrograde flow	18 (37.5)	16 (88.9)	0 (0.0)	1 (5.6)	1 (5.6)	1 (5.6)	1 (5.6)	17 (94.4)	0 (0.0)	18 (100)	

ankle and thus should only be used with a clear and careful operation plan.

The blood supplied to the lateral supramalleolar flap is often from the ascending branch of the peroneal artery, but is inconsistent. In our study, there were three patients whose blood supply for the flap was not the same as described by Masquelet [1]. Instead, the blood supply in our patients came from the anterior

tibialis artery branch. Two of them were treated by the mixed flow pattern, and one was treated by the retrograde flow pattern. In our study, when we observed the variants of blood supply to the flap, we used a bulldog to stop blood flow from the anterior tibialis artery and checked reverse flow from the anterolateral malleolar artery. When there were signs of good blood supply flow, we continued using the lateral supramalleolar flap as

planned. For example, one of our patients had a severely complicated defect and lost the soft tissues in the forefoot. Since the injury was from dorsal to palmar side, the coverage on one side would not be effective. Thus, we tried to cover the defect using the lateral supramalleolar flap that reached out to the anterior sole. The patient had good outcomes after only one operation. This result indicates the potential ability of the retrograde flow pattern to cover the forefoot defects, even in the presence of variants of blood supply. Despite a very high success rate found in our study (94%) which is consistent with a previous study by Voche et al. (98%) [15], several lessons can be learned from the failure cases. For example, two patients had partial necrosis flaps and needed a skin graft afterward. In these cases, the subcutaneous pedicles were tunneled. Although this method has advantages in aesthetic outcomes, this can restrict the flap vascularization. Therefore, surgeons should be cautious about the risk of blood flow reduction when using this method. Another example is the case where the lateral supramalleolar flap was completely necrotic. This old patient was referred to our hospital from a provincial hospital where she was treated with a sural flap. This flap was completely necrotic at hospital admission, and thus we used a lateral supramalleolar flap. However, this lateral supramalleolar flap was totally necrotic after 7 days. One possible reason for this is the poor flap vascularization in the elderly. Thus, more attention should be paid to this population, possibly by evaluating vascularization image before the surgery. Moreover, in our study, the donor site was covered by skin graft in 39 cases, and the region was prosperously covered in all patients without tendon adhesion. Voche et al. reported a longer duration for skin graft to heal in the donor site because the skin paddle was too distally elevated [15]. They needed to have skin grafted on the tendons. Therefore, the choice of pedicle, with a favor for subcutaneous pedicle to avoid skin graft on the surface of the tendons, should be considered.

There are several clinical implications and novelties from our study. First, in our study, we found a new variant of the blood supply to lateral supramalleolar flap. Because blood supply to lateral supramalleolar flap is a vital factor affecting the success of the surgery, knowledge about this could be beneficial for surgeons. All previous studies about the anatomy of the lateral supramalleolar flap reported the existence of a perforating branch of the peroneal artery which nourishes the flap through an ascending branch [14,18]. Recently, Kai Rong revealed that the vascular supply for this flap had two main types including (1) a collateral inferolateral branch anastomosed with the perforating branch of the peroneal artery and (2) the anastomosis of descending branch of the peroneal artery and anterior lateral malleolar artery [17]. However, in our study, we found that blood supply also came from a collateral inferolateral branch, a branch of an anterior tibialis artery ( $n=3$ ). Interestingly, the perforating branch of the peroneal artery was absent in these patients. Thus, further studies exploring the anatomy of blood supply to lateral supramalleolar flap are needed so that surgeons can have optimal design and elevation of the retrograde lateral supramalleolar flap. Second, the methods used to customize the elevation of subcutaneous pedicle in our study had potential benefits in flap outcomes. Technically, the biggest challenge with retrograde lateral supramalleolar flap is the risk of venous congestion, where compression of the subcutaneous pedicle in a tight tunnel causes partial or total flap necrosis. Previous studies recommended using a subcutaneous pedicle and incising skin tunnel. After passing the flap, the pedicle is then covered with a skin graft [16]. However, this technique still has risk of compression due to the gauze on

the surface of the skin graft. In our study, we had a new customization approach by dissecting a 3 cm width of subcutaneous pedicle with 1 cm skin in the middle as a tent roof. When the pedicle passed the incised skin tunnel, we spread the subcutaneous pedicle and sutured the tent roof. This customization of subcutaneous pedicle dissection minimized the compression and maximized the aesthetic results by matching the skin of the roof tent pedicle with the skin nearby.

This study had several limitations. First, our study was conducted on a relatively small number of patients, especially in the retrograde flow group. The main reason was the complexity of technique used to elevate the descending branch. However, with a high success rate, our study indicates the potentials of retrograde pattern in reconstructing defects in foot regions. Second, although the success rate was high, we did not have strong evidence of such success in some sub-populations. For example, in our study, there were only five patients aged more than 60 who might have a higher risk than the younger population. More studies with a diversity of patients' characteristics are needed.

## Conclusion

The lateral supramalleolar flap can cover the soft tissue of ankle and foot defects in both mixed-blood supply pattern or retrograde pattern with high success rates. It can cover the injuries in many subunits of the ankle and foot, even in hospitals with limited resources for microsurgery. However, the risk of venous congestion should be considered, particularly when using the retrograde pattern flap.

## Acknowledgement

The authors thank Khanh Hoa Vo, Hoang Minh The Nguyen, Tu Ngoc Nguyen, Vy Tuong Thi Nguyen and Grant & Innovation Center for their help during the study.

## Disclosure statement

No potential conflict of interest was reported by the author(s).

## ORCID

Truc Thanh Thai  <http://orcid.org/0000-0003-2512-8281>

## References

- [1] Masquelet AC, Beveridge J, Romana C, et al. The lateral supramalleolar flap. *Plast Reconstr Surg.* 1988;81(1):74–81.
- [2] Zayed EF. Lateral supramalleolar flap for reconstruction of the distal leg and foot, clinical experience with 25 cases. *Egypt, J Plast Reconstr Surg.* 2011;35(2):279–286.
- [3] Gir P, Cheng A, Oni G, et al. Pedicled-perforator (propeller) flaps in lower extremity defects: a systematic review. *J Reconstr Microsurg.* 2012;28(9):595–601.
- [4] Lin CH, Mardini S, Wei FC, et al. Free flap reconstruction of foot and ankle defects in pediatric patients: long-term outcome in 91 cases. *Plast Reconstr Surg.* 2006;117(7):2478–2487.
- [5] Xu G, Lai-Jin L. The coverage of skin defects over the foot and ankle using the distally based sural neurocutaneous flaps: experience of 21 cases. *J Plast Reconstr Aesthet Surg.* 2008;61(5):575–577.

- [6] Basheer MH, Wilson S, Lewis H, et al. Microvascular free tissue transfer in reconstruction of the lower limb. *J Plast Reconstr Aesthet Surg.* 2008;61(5):525–528.
- [7] Teo TC. Propeller flaps for reconstruction around the foot and ankle. *J Reconstr Microsurg.* 2021;37(01):022–031.
- [8] Goil P, Sharma P, Midya M, et al. The lateral supramalleolar flap: a reliable option for lower leg and foot reconstruction. *Int J Res Orthop.* 2018;4(5):715–719.
- [9] Hamdi MF, Khlifi A. Lateral supramalleolar flap for coverage of ankle and foot defects in children. *J Foot Ankle Surg.* 2012;51(1):106–109.
- [10] Valenti P, Masquelet AC, Romana C, et al. Technical refinement of the lateral supramalleolar flap. *Br J Plast Surg.* 1991;44(6):459–462.
- [11] Lee JH, Chung DW. Reverse lateral supramalleolar adipofascial flap and skin grafting for one-stage soft tissue reconstruction of foot and ankle joint. *Microsurgery.* 2010;30(6):423–429.
- [12] Lee YH, Rah SK, Choi SJ, et al. Distally based lateral supramalleolar adipofascial flap for reconstruction of the dorsum of the foot and ankle. *Plast Reconstr Surg.* 2004;114(6):1478–1485.
- [13] Dinh Nhat Vu NVN. Using lateral supramalleolar fasciocutaneous flap to cover soft tissue defects in one-third of the lower leg, around the ankle, dorsal foot, and heel. *J Pract Med.* 2009;6:22–24.
- [14] Beveridge J, Masquelet A, Romana M, et al. Anatomic basis of a fascio-cutaneous flap supplied by the perforating branch of the peroneal artery. *Surg Radiol Anat.* 1988;10(3):195–199.
- [15] Voche P, Merle M, Stussi JD. The lateral supramalleolar flap: experience with 41 flaps. *Ann Plast Surg.* 2005;54(1):49–54.
- [16] Nambi GI, Varanambigai TKA. Clinical study of the lateral supramalleolar flap in the soft tissue reconstruction around the ankle region. *Indian J Plast Surg.* 2020;53(1):83–89.
- [17] Rong K, Chen C, Hao LW, et al. Redefining the vascular classifications of the lateral supramalleolar flap. *Ann Plast Surg.* 2016;77(3):341–344.
- [18] Le Nen D, Beal D, Person H, et al. Anatomical basis of a fascio-cutaneous pedicle flap based on the infero-lateral collateral artery of the leg. *Surg Radiol Anat.* 1994;16(1):3–8; discussion 9. discussion 9.