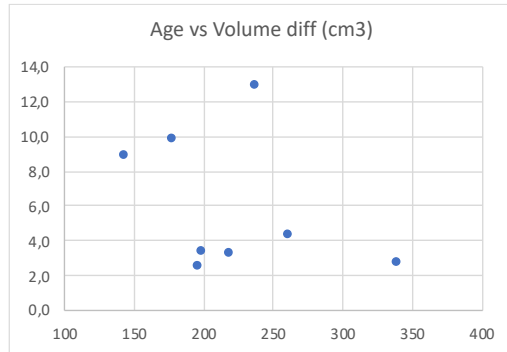
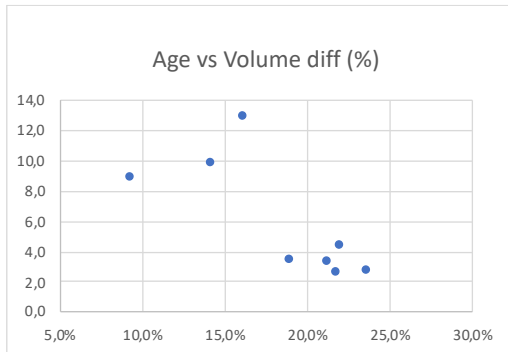


Supplementary material has been published as submitted. It has not been copyedited or typeset by Journal of Plastic Surgery and Hand Surgery.

Supplemental Digital Content

Spring-assisted Posterior Vault Expansion in Children over 2 Years of Age with Craniosynostosis

Karin Säljö, MD, PhD; Madiha Bhatti-Søfteland, PhD; Peter Tarnow, MD, PhD; Robert Olsson,
MD; Tobias Hallén, MD, PhD; Wen-Chih Chao, BSc; Lars Kölby, MD, PhD; Giovanni Maltese,
MD, PhD



Figure, Supplemental Digital Content 2. Dot plots of the relationship between age at surgery and post-surgical changes in volume (a, b).