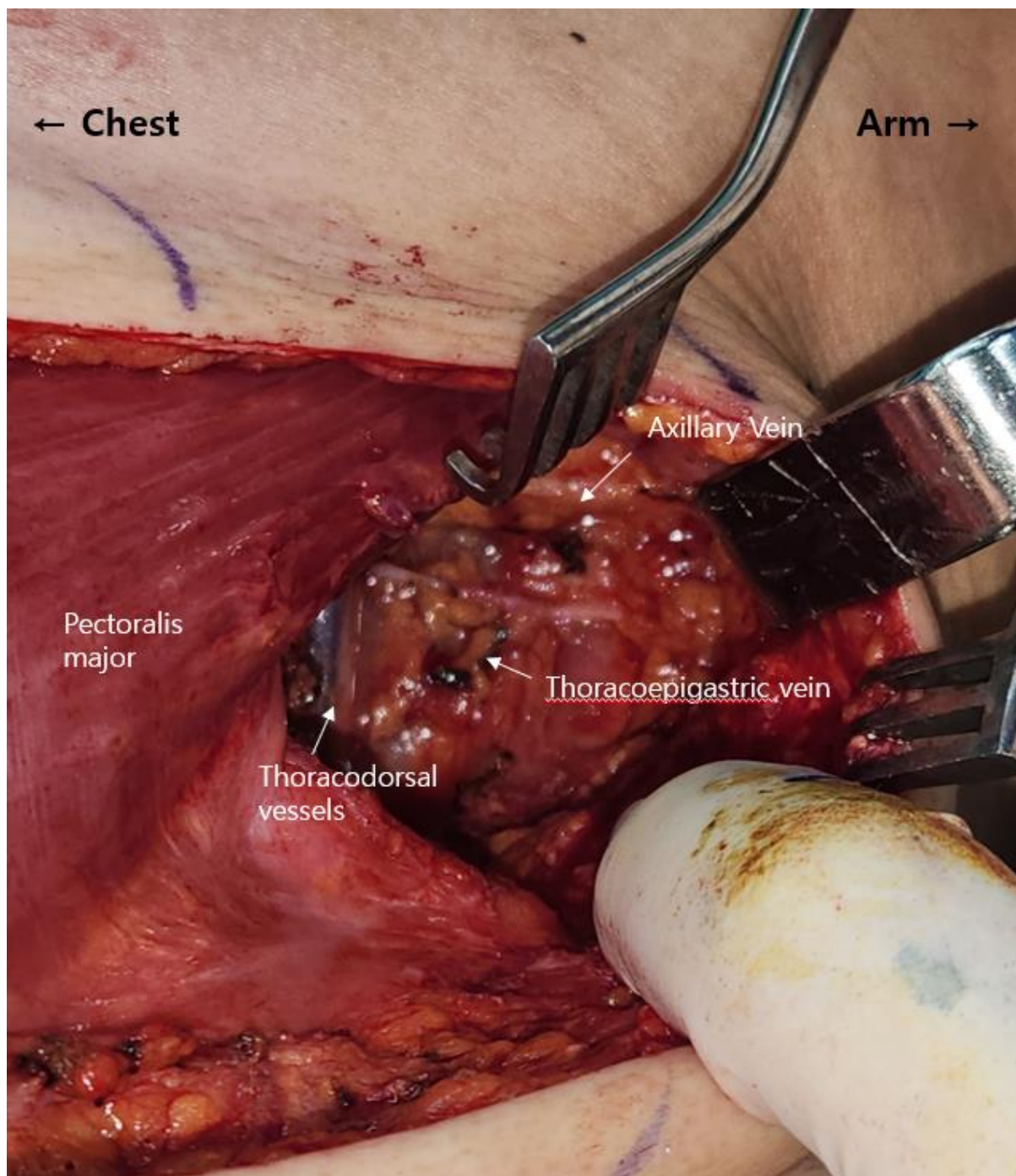


Supplementary material has been published as submitted. It has not been copyedited or typeset by Journal of Plastic Surgery and Hand Surgery.

Supplementary Fig 1. Intraoperative images before lymphovenous anastomosis



Supplementary Fig 2. Intraoperative images after anastomosis and ICG imaging.

