

Supplementary material has been published as submitted. It has not been copyedited or typeset by Scandinavian Journal of Urology

Appendix S1

Table 1. Characteristics of three patients with TSC-associated AML and rebleeding episodes after SAE.

	Rebleeding episodes			
	Patient 1	Patient 2	Patient 3	
Bleeding episode number	#1	#1	#1	#2
Tumor diameter at initial SAE	8.1	12.4	17.5	15.2
Technical success	Complete	Complete	Partial	Partial
Procedural response after SAE	-46%	N/A ¹	-13%	N/A ¹
Regrowth during follow-up	+36%	0%	0%	+29%
Tumor diameter at re-SAE, cm	6.6	12.4	15.2	19.6
Time from first SAE to rebleeding, years	6.9	1.7	0.9	5.2

¹No radiological follow-up between SAE and re-SAE.

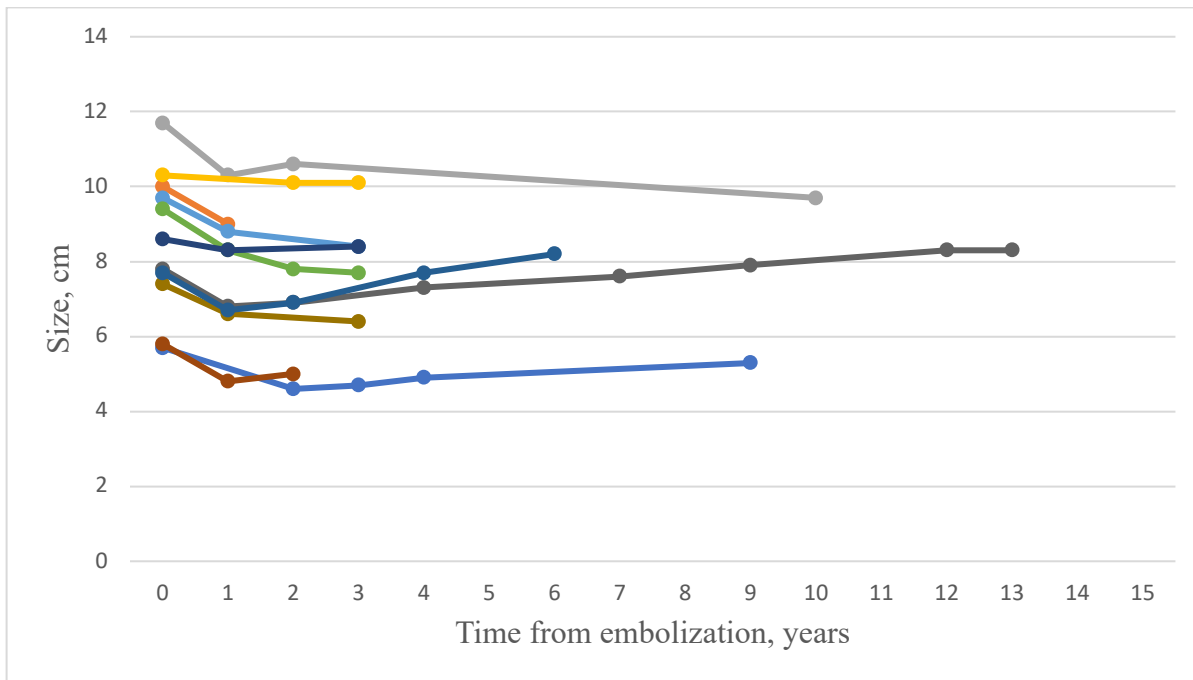
AML=angiomyolipoma

TSC=tuberous sclerosis complex

SAE=selective arterial embolization

Figure 1. Graphs displaying radiological response of individual tumors to selective arterial embolization in sporadic AML divided by **a)** minor response (1-19% reduction in diameter), and **b)** major response ($\geq 20\%$ reduction in diameter).

a)



b)

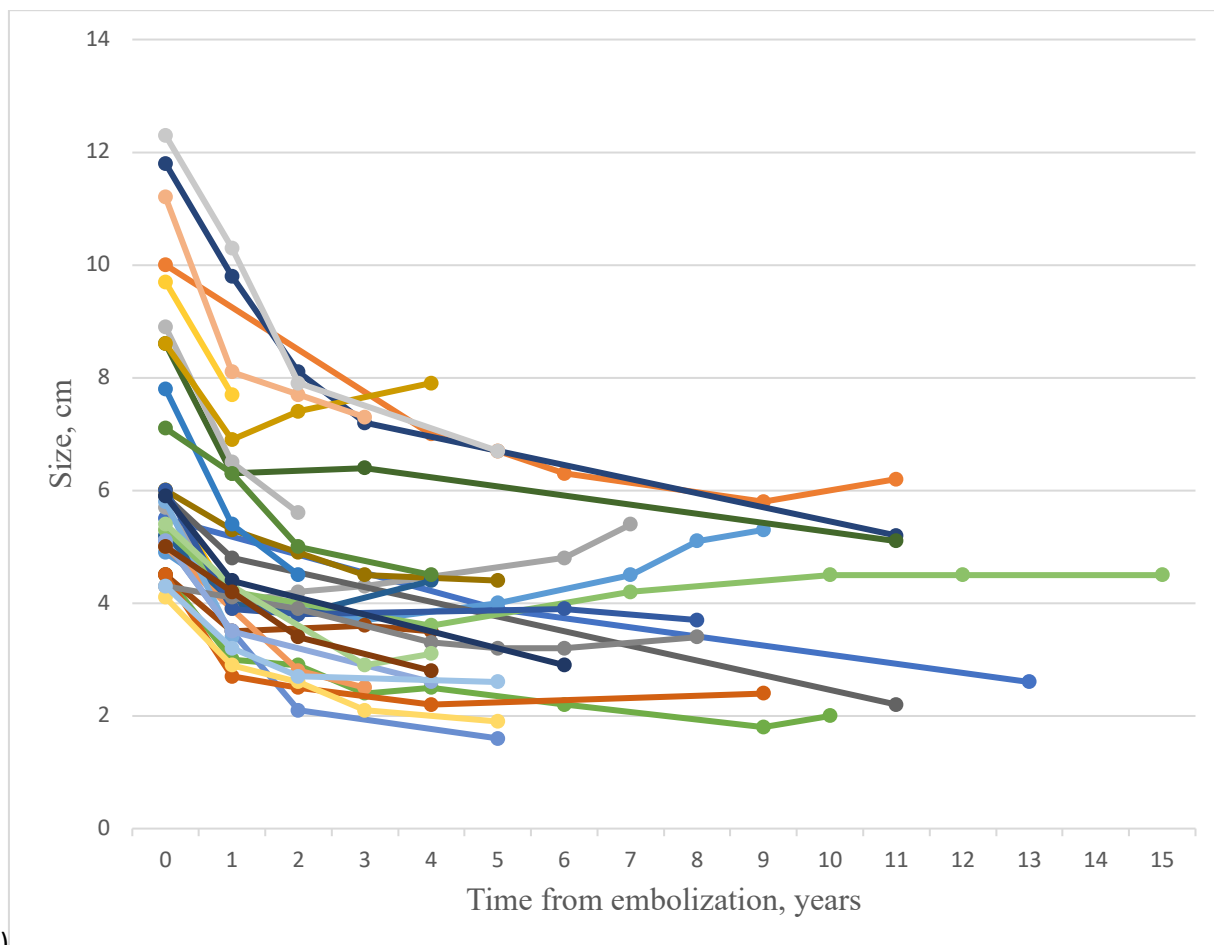


Figure 2. Graph displaying regrowth in individual sporadic AML and major progress (>20% increase in diameter).

