

DISCUSSION

The introduction of immunofluorescence techniques in dermatology has contributed favourably to the exact diagnosis of bullous disorders. It has also caused a certain amount of confusion in the old classification of these disorders. An example of this is the finding of linear IgA in dermatitis herpetiformis (DH), BP and chronic bullous dermatosis in childhood (1).

In our case the morphology of the eruption resembled BP, but the acute onset of the disease with high fever and its self-limiting nature was more compatible with a drug eruption or erythema multiforme. We have avoided the latter diagnosis because of the absence of typical lesions and the inconclusive histopathological findings. The immunopathological findings would strongly favour a diagnosis of DH, but the clinical course excludes this diagnosis. Linear IgA bullous dermatosis is considered by some authors to be a separate disease entity (1). It is, however, a clinically heterogeneous group of disorders, ranging from cases of typical DH to those of typical BP, including a spectrum of intermediate varieties, none of them resembling our case.

A definite relationship between the drug and the skin eruption was proven by re-introduction of the drug. Diclophenac has been reported to be well tolerated and to have a wide safety margin. In one report (2) only 2 out of 200 patients developed a rash which was considered to be related to the medication. There are few reports on the immunopathological findings in drug-induced dermatosis. Using the IF technique, van Joost (3) demonstrated circulating immunoglobulins with an affinity for basal cells. In one of his cases, IgG and C were detected by the DIF technique. Other authors have reported intercellular immunoglobulin deposition (4) and immunoglobulins bound to basal cells in lesional skin in toxic epidermal necrolysis (5). The exact mechanisms in these drug-induced disorders are not fully known at present. It is possible that more than one hypersensitivity mechanism is involved. The striking feature in our case is the finding of linear IgA along the basement membrane. This initially caused some confusion in the diagnosis and treatment of the illness, before the condition was subsequently shown to be a drug-induced bullous dermatosis with unusual immunopathological findings.

REFERENCES

1. Chorzelski, T. P., Jablonska, S. & Beutner, E. H.: Linear IgA bullous dermatosis. *In Immunopathology of the Skin*, 2nd ed. (ed. T. P. Chorzelski, S. Jablonska, S. F. Bean), pp. 315-323. Publisher 1979.
2. Abrams, G. J., Solomon, L. & Meyers, O. L.: A long-time study of diclophenac sodium in the treatment of rheumatoid arthritis and osteo-arthritis. *S A Med J* 53: 442, 1978.
3. van Joost, Th.: Incidence of circulating antibodies reactive with basal cells of skin in drug reactions. *Acta Dermatovener (Stockholm)* 54: 183, 1974.
4. Shelley, W. B., Schlappner, O. L. A. & Heiss, H. B.: Demonstration of intercellular immunofluorescence and epidermal hysteresis in bullous fixed drug eruption due to phenolphthalein. *Br J Dermatol* 86: 118, 1972.
5. Stein, K. M., Schlappner, O. L. A., Heaton, C. L. & Decherd, J. W.: Demonstration of basal cell immunofluorescence in drug-induced toxic epidermal necrolysis. *Br J Dermatol* 86: 246, 1972.

Physicochemical Properties of "Spun Glass" Hair

Howard P. Baden, Robert J. Schoenfeld,¹ James D. Stroud,¹ and Rudolf Happle²

Department of Dermatology, Massachusetts General Hospital, Harvard Medical School, Boston, Massachusetts 02114, and ¹Wayne State University, Detroit, Michigan, USA; ²Münster University, Münster, Federal Republic of Germany

Received January 19, 1981

Abstract. The amount of protein solubilized with a Tris-urea-mercaptoethanol buffer was markedly reduced in a patient with "spun glass" hair but normal in 3 other patients with similar appearing hair. Polyacrylamide gel electrophoresis showed that it was mainly the matrix component that was solubilized. X-ray diffraction and stress stain tests on the "spun glass" hair proved normal, as was the amino acid analysis. The cause of the insolubility has not been established.

A large number of hereditary disorders of the hair have been described, but in only a few have chemical abnormalities been identified in the structural proteins (2, 10). Stroud & Mehregan (12) reported on a patient with "Spun-glass" hair that tended to stick out and they noted that the hairs were crimped and had a triangular or kidney shaped cross-section. The hair in this patient would not lie flat when combed.

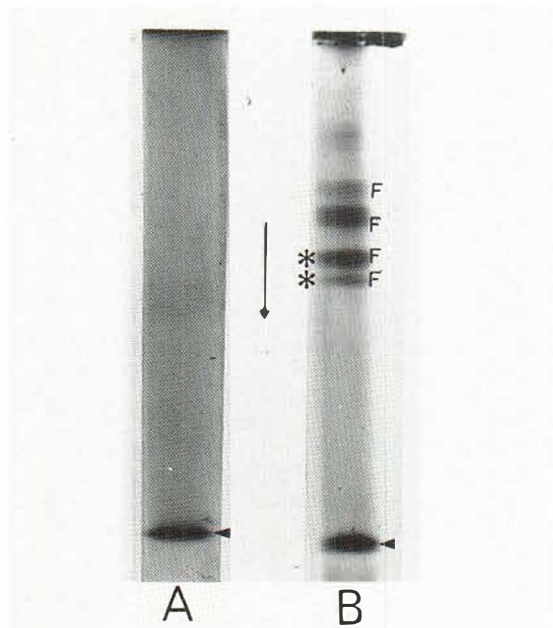


Fig. 1. Urea PAGE pattern of the SCM proteins of no. 1 (A) and normal hair (B). *F* are the four fibrous bands and the matrix band is indicated by ◀. Only the matrix band is seen in A but, with heavy loading, faint bands corresponding to the two fastest *F* bands * could be seen.

Histology of the follicle showed that the triangular hairs were surrounded by an inner root sheath of uniform thickness, with the outer root sheath filling in the irregularity to give a round follicular cross-section. Patients with similar appearing hair have been reported by other investigators (5, 6, 7, 11), who noted a triangular shape and canaliform longitudinal dystrophy by scanning electron microscopy.

This report describes the biochemical and physical characteristics of the hair from Stroud & Mehregan's patient and compares the results with those obtained from 3 additional patients with similar hair.

MATERIALS

The patients were selected for study because they all had hair that stood out and would not lie down after brushing or combing. Patient no. 1 was the patient of Stroud & Mehregan (12) and Schoenfeld & Lupulescu (11), the brothers 2 and 3 were patients of Schoenfeld & Lupulescu (11) and no. 4 is a new patient of Happle. No other abnormalities of the skin or other organs were observed in these patients. When studied by scanning electron microscopy, the hair from all these individuals showed a triangular

cross-section, a canaliform longitudinal dystrophy and no breaks. Schoenfeld & Lupulescu (11) also reported that the cuticular scales of cases 1, 2 and 3 were smaller and irregular in size and shape and had a disorganized pattern.

METHODS

Hair was clipped from affected individuals and mailed to the laboratory where it was stored at -70°C . Control samples handled this way showed no changes in their physical or chemical properties. The patients denied using bleaches and/or coloring agents and their hair had not been straightened or curled by chemical or physical means.

The hair was washed with petroleum ether, dried under vacuum and weighed. It was extracted with 8 M urea containing 0.2 M Tris, pH 9.5 and 0.1 M mercaptoethanol (TUM) under nitrogen for 1 h at 50°C and then homogenized. The extraction was then continued for 2 h. After centrifugation at 10000 *g* for 30 min the supernatant was treated with iodoacetic acid to give the S-carboxymethyl (SCM) derivatives of the fibrous and matrix proteins.

Protein was determined by the Bio-rad method and polyacrylamide gel electrophoresis was done by the Davis method (4) but with the addition of 8 M urea (3). Stress-strain analysis was done in water as previously described (9). The hair samples were hydrolysed for 24 h in 6 N HCl at 100°C under nitrogen and amino acid analysis was done in duplicate with the Beckman 116 amino acid analyser. X-ray diffraction analysis of whole hair was done as previously reported (2).

RESULTS

The amount of protein solubilized from hair no. 1 by treatment with TUM buffer at 50°C for 3 h was much less than that of the other patients, as shown in Table I. This was tested on two different samples taken in 1973 and 1979. The amount of protein solubilized from normal hair was never less than 25 g/100 g in the more than 500 samples we have studied.

The urea PAGE pattern of no. 1 showed mainly the matrix component and very weak bands corresponding to the first two fibrous polypeptides (Fig.

Table I. Amount of protein extracted by the Tris-urea-mercaptoethanol buffer

| Patient no. | Yield (g/100 g hair) |
|-------------|----------------------|
| 1 | 3 |
| 2 | 60 |
| 3 | 25 |
| 4 | 35 |

1). The other individuals listed in Table I had normal patterns.

Amino acid analysis results of the various hair samples are shown in Table II; they are not significantly different from normal. No unidentifiable peaks were observed on the runs.

Stress-strain analysis in water of hair from patient 1 showed a normal breaking strength (2.7×10^6 g/cm²), normal percentage extension at break (66%) and normal shape of the curve (Fig. 2). Each value given is the average of five determinations.

X-ray diffraction analysis showed reflections at 9.8 Å on the equator and 5.15 Å on the meridian for nos. 1, 2, 3 and 4, characteristic of normal filamentous protein.

DISCUSSION

Although the hair of these 4 individuals had a similar clinical appearance, the hair of patient 1 was unique in that it was markedly insoluble in the solvent which is ordinarily used to dissolve hair. The presence of stable cross-links is one possible explanation for the insolubility we observed, since they can produce insoluble protein aggregates. Treatment of hair with alkali (1) has been shown to induce unusual cross-links but the conditions for the reaction are much harsher than would be experienced by the patient in her hair care. The γ -(ϵ -lysine) glutamyl cross-link observed in hair is also a possible explanation, but most or all of the cross-link is in the medulla protein (8). The normal

Table II. Amino acid analysis of hair

The data are expressed in residue per 100 residues

| | No. 1 1973 | No. 1 1979 | No. 2 1979 | No. 3 1979 | No. 4 1979 |
|---------------|---------------|---------------|---------------|---------------|---------------|
| Lysine | 1.9 | 3.6 | 2.4 | 2.1 | 3.2 |
| Histidine | 0.4 | 1.0 | 0.5 | 0.5 | 0.8 |
| Arginine | 7.4 | 6.0 | 6.9 | 6.6 | 8.3 |
| Aspartic acid | 5.5 | 4.7 | 5.7 | 5.6 | 4.8 |
| Threonine | 7.0 | 6.9 | 6.8 | 6.8 | 6.4 |
| Serine | 13.9 | 13.5 | 12.1 | 15.7 | 13.5 |
| Glutamic acid | 14.4 | 13.4 | 15.1 | 15.1 | 14.1 |
| Proline | 9.5 | 8.0 | 10.0 | 9.2 | 8.3 |
| Glycine | 7.2 | 6.0 | 8.0 | 6.9 | 6.9 |
| Alanine | 5.1 | 4.4 | 5.4 | 5.0 | 4.5 |
| Half-cystine | 13.3 | 15.3 | 13.0 | 13.6 | 16.4 |
| Valine | 3.2 | 5.3 | 3.0 | 3.1 | 3.4 |
| Methionine | 1.0 | 0.5 | 0.5 | 0.4 | 0.4 |
| Isoleucine | 1.3 | 2.4 | 1.3 | 1.0 | 0.9 |
| Leucine | 5.7 | 5.7 | 5.6 | 5.4 | 5.0 |
| Tyrosine | 1.8 | 1.5 | 2.1 | 1.8 | 1.8 |
| Phenylalanine | 1.4 | 1.8 | 1.7 | 1.2 | 1.3 |

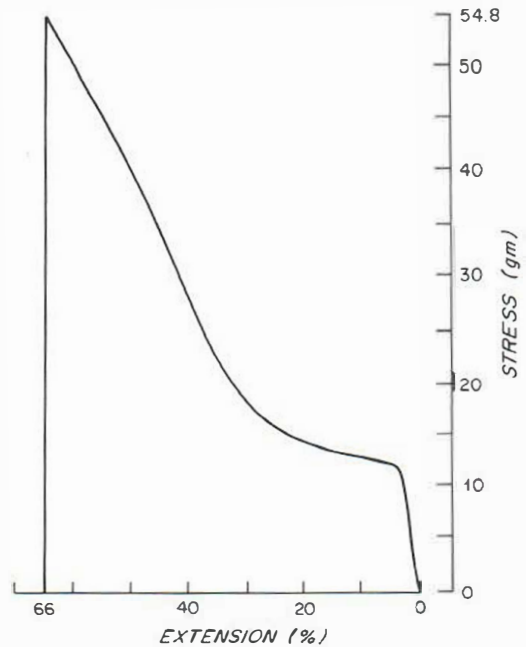


Fig. 2. Stress-strain analysis tracing of no. 1 hair. The shape of the curve is identical with that of normal hair.

stress-strain curve speaks against an abnormality of sulfur cross-linking, as it is very sensitive to such changes.

It is not clear how the insolubility of hair from patient no. 1 is related to its appearance, but it is a constant marker for this patient's hair abnormality. The "spun glass" abnormality, therefore, should be considered a distinctive variant of uncombable hair. Additional studies of individuals and families with uncombable hair are essential to uncover other examples of insoluble "spun glass" hair. However, elucidation of the defect may require new data on the chemical properties of hair.

ACKNOWLEDGEMENT

This work was supported by Grant AM-06838 from the N.I.H.

REFERENCES

- Asquith, R. S., Otterburn, M. S. & Sinclair, W. J.: Isopeptide crosslinks—their occurrence and importance in protein structure. *Angew Chem [Engl]* 13 (8): 514, 1974.
- Baden, H. P., Jackson, C. E., Wiess, L., Jimbow, K., Lee, L., Kubilius, J. & Gold, J. M.: The physicochemical properties of hair in the BIDS syndrome. *Am J Hum Genet* 28: 514, 1976.

3. Baden, H. P., Lee, L. D. & Kubilus, J.: A genetic electrophoretic variant of human hair α -polypeptides. *Am J Hum Genet* 27: 472, 1975.
4. Davis, B. J.: Disc electrophoresis. II. Method and application to human serum proteins. *Ann NY Acad Sci* 212: 404, 1964.
5. Dupre, A., Bonafe, J. L., Litoux, F. & Victor, M.: Le syndrome des cheveux incoiffables, pili trianguli et canaliculi. *Ann Dermatol Venereol (Paris)* 105: 627, 1978.
6. Dupre, A., Röchiccioli, P. and Bonafe, J. L.: "Cheveux incoiffables": anomalie congénitale des cheveux. *Bull Soc Fr Dermatol Syph* 80: 111, 1973.
7. Happle, R., Echemacht-Happle, K., Lehmann, R. & Frosch, P. J.: Uncombable hair syndrome. First International Congress of Hair Research, Hamburg, 13-16 March, 1979.
8. Harding, H. W. J. & Rogers, A. E.: The occurrence of the ϵ -(γ -glutamyl) lysine cross link in the medulla of hair and quill. *Biochim Biophys Acta* 257: 37, 1972.
9. Kelling, C., Goldsmith, L. A. & Baden, H. P.: Biophysical and biochemical studies of the hair in cartilage-hair hypoplasia. *Clin Genet* 4: 500, 1973.
10. Pollitt, R. J., Jenner, F. A. & Davies, M.: Sibs with mental and physical retardation and trichorrhexis nodosa with abnormal amino acid composition of the hair. *Arch Dis Child* 43: 211, 1968.
11. Schoenfeld, R. J. & Lupulescu, A. P.: Crimped "spun-glass" hair in siblings: with twelve year follow-up of an entire case. First International Congress of Hair Research, Hamburg, 13-16 March, 1979.
12. Stroud, J. D. & Mehregan, A. H.: "Spun-glass" hair: A clinicopathologic study of an unusual hair defect. In *The First Human Hair Symposium* (ed. A. C. Brown), pp. 103-107. Medcom Press, New York, 1974.

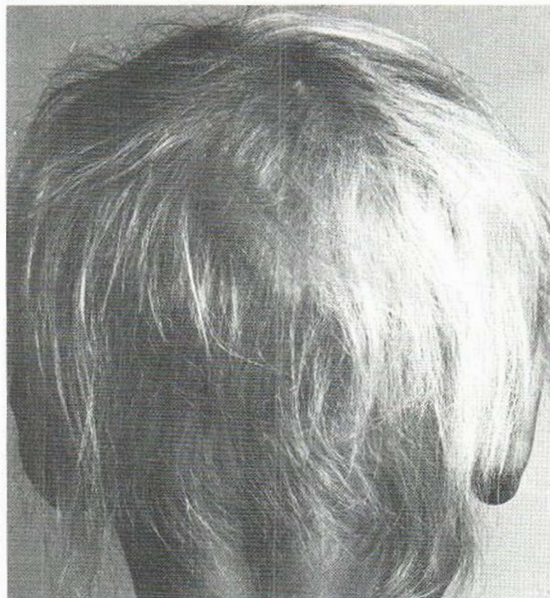


Fig. 1. Poor, thinned and colourless scalp hair before zinc therapy.

phatase levels was observed during the zinc supplementation. Microscopic examination of her poor scalp hair, using polarized light, revealed well-defined abnormalities of the hair shafts, as reported by others in a case of acrodermatitis enteropathica: 1) a marked individual variation in diameter, 2) narrowing often associated with waving or sharp bending and broken ends, 3) striation with a tendency to trichonodosis. Such changes were absent in the pigmented hair appearing after the start of zinc therapy.

Key words: Acrodermatitis enteropathica; Beau lines; Hair structure; Malabsorption; Sucrase deficiency; Zinc deficiency

Hair Changes Due to Zinc Deficiency in a Case of Sucrose Malabsorption

Kaare Weismann and Hans K. Hagdrup

Department of Dermatology, University of Copenhagen, Rigshospital, Copenhagen, Denmark

Received January 5, 1981

Abstract. A 7-year-old girl suffering from chronic diarrhoea due to sucrase deficiency was referred because of poor hair growth. Her scalp hair had a poor, colourless appearance and was much thinned in the occipital region. Her skin was dry, but otherwise normal. P-zinc was low (7.9 $\mu\text{mol/l}$), whereas P-albumin was normal. Oral zinc therapy, 40 mg daily, had a marked beneficial effect on her scalp hair, eyebrows and eyelashes, which became thicker and pigmented. Beau lines appeared on thumb-nails and 4th left finger-nail. A rise in P-zinc and S-alkaline phos-

phatase levels was observed during the zinc supplementation. Within the last two decades it has been shown that zinc deficiency may develop in man due to poor living conditions and various diseases. The condition may be a consequence of malnutrition in certain rural districts of the Middle East (7). In the Western hemisphere long-term total parenteral nutrition poor in zinc (5), alcoholic liver cirrhosis (11), short-bowel syndrome and malabsorption (9) are known causes of zinc deficiency. In childhood, lack of the essential element may be due to acrodermatitis enteropathica, a specific zinc malabsorption disease (9, 12), total parenteral nutrition (1) and antileukaemic chemotherapy (6). In these cases reported, zinc deficiency caused well-defined skin and hair changes (9) which often led to the diagnosis.