

## IMMUNOFLUORESCENCE OF TZANCK SMEARS IN PEMPHIGUS VULGARIS

James Wm. Decherd, Max B. Rubin, Herbert Goldschmidt, and Harold B. Heiss

*From the Department of Dermatology, Hospital of the University of Pennsylvania, School of Medicine, Philadelphia, Pennsylvania, USA*

**Abstract.** Positive direct immunofluorescence was observed on mucosal and skin lesions of two patients with pemphigus vulgaris when standard Tzanck smears of the lesions were prepared. Negative tests were noted on smears obtained from patients with other bullous disorders and on control blisters produced with cantharadine, friction, and liquid nitrogen. Our preliminary results suggest that this modification may provide an alternative to the standard direct immunofluorescent test when biopsy specimens are not easily obtainable.

The use of immunofluorescent technique has become widespread in the diagnosis and management of bullous disorders (2, 3, 4, 6). Recent reports have re-emphasized the fact that indirect immunofluorescence may be negative when, in fact, the direct test is positive (1). Biopsies are therefore required in situations where a false negative test result is suspected. Specimens must often be taken from relatively inaccessible areas and must be processed rapidly, frequently creating logistical problems.

We have performed direct immunofluorescence on specimens obtained from patients with bullous disorders utilizing the standard technique for preparing Tzanck smears. This modification has proved valuable in the diagnosis of pemphigus vulgaris.

### METHOD

Fresh bullous lesions from the oral cavity and body of a 46-year-old white male and a 53-year-old white woman with known pemphigus vulgaris were examined. Both had biopsies and standard indirect and direct tests consistent with this diagnosis. As controls, lesions from 2 patients with bullous pemphigoid and 1 patient with bullous erythema multiforme were examined. In addition, cantharidin-induced acantholytic blisters (5) and blisters produced by

liquid nitrogen and friction in 2 normal volunteers were examined.

All lesions were treated in a similar manner. The bulla of the roof, if present, was removed without disturbing the base. The base was then gently scraped with a sterile wooden tongue-depressor. Material obtained was immediately smeared on a glass slide and air dried. Slides were stored at  $-20^{\circ}\text{C}$  and prepared within 48 hours.

Slides were overlaid with commercially prepared fluorescein-conjugated goat anti-human IgG (Hyland Laboratories, Los Angeles, Calif., USA) diluted 1:10 with phosphate-buffered saline containing 2% Tween-80. After incubation for 30 min, the slides were given three 10-min washings in phosphate-buffered saline and rinsed with distilled water (3).

After FA mounting fluid and coverslips were applied, the slides were examined with a Leitz Ortholux fluorescent microscope utilizing a Schott BG12 exciter filter and a Leitz K530 barrier filter.

### RESULTS

All lesions examined from both patients with pemphigus vulgaris were positive. Individual acantholytic cells as well as clumps and sheets of adherent epidermal cells were seen to exhibit bright green fluorescence (Figs. 1, 2, 3). The marked fluorescence of individual acantholytic cells confirms the observations of others (8). The intensity of the fluorescence was greatest at the periphery of the cell membrane. Some cells showed a localized "beading" at the periphery of the cell. The large sheets of cells exhibited the same type of bright intercellular fluorescence as is noted in the standard direct preparations.

### COMMENT

Early diagnosis is essential for the proper management of pemphigus vulgaris, and the indirect im-

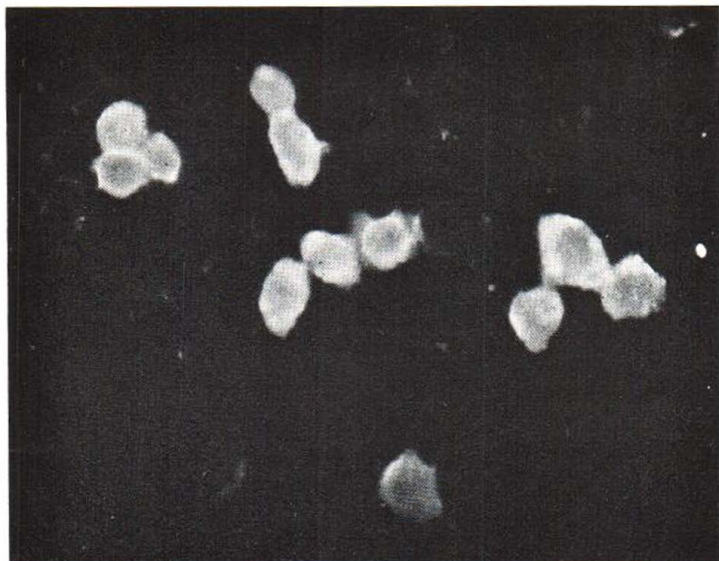


Fig. 1. Acantholytic cells from oral lesions of a 46-year-old white male with pemphigus vulgaris showing positive immunofluorescence.  $\times 210$ .

munofluorescence test may be negative in the early stages. In one study 66% of the patients with this disorder initially presented with lesions limited to the oral cavity (7), where adequate biopsy specimens cannot be obtained easily.

This new technique of performing direct immunofluorescence on Tzanck smears has proved to be a particularly useful adjunct in the diagnosis of pemphigus vulgaris. Not only may it be performed without the necessity of a standard biopsy specimen, but also the preparation of the smears

requires neither specialized equipment nor training. By circumventing tissue biopsy and subsequent cryostat sectioning a much more rapid means of diagnosis is provided. Furthermore, since storage of the slides for 48 hours before testing did not induce false negative results, the special facilities required for the immunofluorescent diagnosis of pemphigus could be utilized by physicians in the outlying areas by mailing the smears to central laboratories.

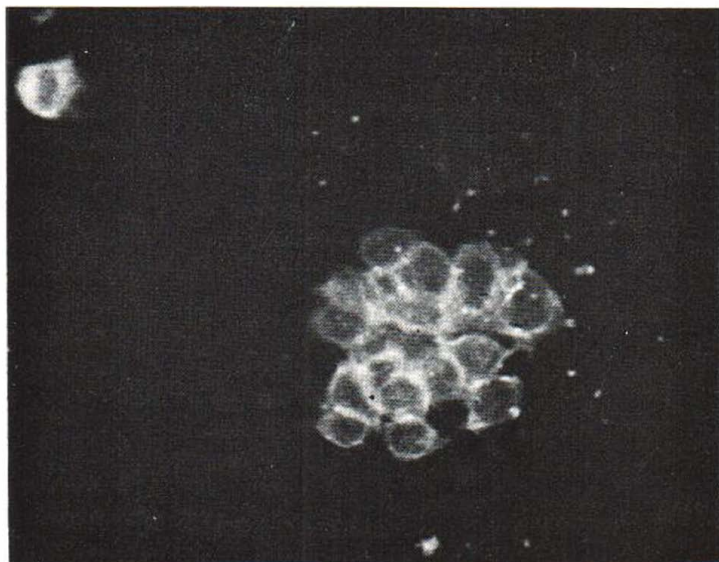


Fig. 2. Clump of cells and one acantholytic cell from pemphigus vulgaris lesion of central chest of a 53-year-old white female. Intraepithelial localization of labeled antibody is similar to that seen in standard direct biopsy preparations.  $\times 210$ .

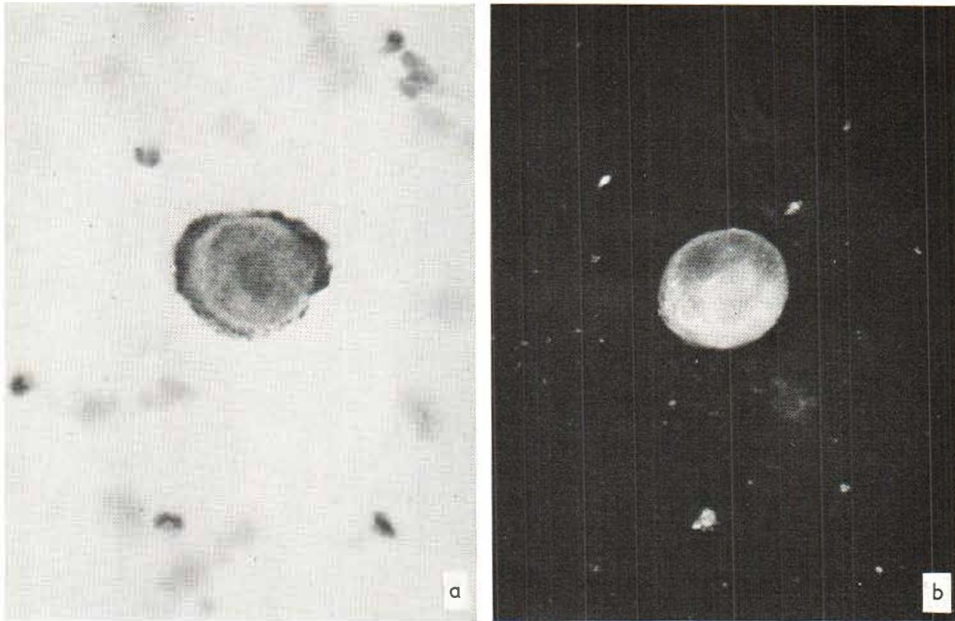


Fig. 3. (a) Acantholytic cell from Tzanck smear of pemphigus vulgaris, Giemsa stain,  $\times 450$ . (b) Acantholytic cell

from Tzanck smear of pemphigus vulgaris showing positive immunofluorescence.  $\times 350$ .

#### ACKNOWLEDGEMENTS

J. D. is a USPH Trainee on Public Health Grant AM-05261.

This work is supported in part by the Kline Fund and the Wende Fund.

#### REFERENCES

1. Bean, S. F., Alt, T. H. & Katz, H. I.: Oral pemphigus and bullous pemphigoid. *JAMA* 216: 673, 1971.
2. Beutner, E. H. & Jordon, R. E.: Demonstration of skin antibodies in sera of pemphigus vulgaris patients by indirect immunofluorescent staining. *Proc Soc Exp Biol Med* 117: 505, 1964.
3. Beutner, E. H., Jordon, R. E. & Chorzelski, T. P.: The immunopathology of pemphigus and bullous pemphigoid. *J. Invest Derm* 51: 63, 1968.
4. Beutner, E. H., Chorzelski, T. P. & Jordon, R. E.: *Autosensitization in Pemphigus and Bullous Pemphigoid*, Charles C. Thomas, Springfield, Ill., 1970.
5. Epstein, D. L. & Kligman, A. L.: Warts treated with Cantharidin. *Arch Derm (Chicago)* 77: 508, 1958.
6. Peck, S. M., Osserman, K. E., Weiner, L. B., Lefkowitz, A. & Osserman, R. S.: Studies in bullous diseases: Immunofluorescent serologic tests. *New Eng J Med*, 279: 951, 1968.
7. Ryan, J. G.: Pemphigus: A 20 year old survey of experience with 70 cases. *Arch Derm (Chicago)* 104: 14, 1971.
8. Wright, E. T., Epps, R. L. & Newcomer, V. D.: Fluorescent antibody studies in pemphigus vulgaris. *Arch Derm (Chicago)* 93: 562-576, 1966.

Received October 29, 1971

J. Wm. Decherd, M.D.  
Department of Dermatology  
Hospital of the University of Pennsylvania  
Duhring Laboratories  
3600 Spruce Street  
Philadelphia, Pennsylvania 19104  
USA