

## Annular Elastolytic Giant Cell Granuloma Produced on an Old Burn Scar and Spreading after a Mechanical Trauma

Carmela Pestoni, M. Pereiro Jr and Jaime Toribio

Department of Dermatology, Complejo Hospitalario Universitario, Faculty of Medicine, C/San Francisco s/n, ES-15782 Santiago de Compostela, Spain. E-mail: mejaime@usc.es  
Accepted April 7, 2003.

Sir,

Annular elastolytic giant cell granuloma (AEGCG) is a rare skin disease. It is characterized clinically by annular lesions and histopathologically by giant cell elastophagocytosis on the active border of the lesion and a loss of elastic fibres in the centre in non-sun-damaged skin. The pathogenesis remains controversial. We report the case of a 32-year-old man with a unique, long-course lesion of AEGCG on the left leg developed after repeated burns in his youth. The lesion had remained quiescent over the course of the previous 8 years, but after a mechanical trauma it spread again. To our knowledge, this is the first time these features have been described in the course of AEGCG.

### CASE REPORT

A 32-year-old man presented a unique, 16-year evolution, asymptomatic annular lesion on the internal side of his left leg. The lesion was 7 × 5 cm in size with a smooth, slightly raised erythematous border (Fig. 1). The lesion began after repeated burns caused by a motorbike exhaust pipe in his youth and slowly increased in size. Eight years previously he had been diagnosed as having necrobiosis lipoidica based only on the clinical aspect and he had been treated with topic-occlusive corticosteroids to stop its growth. The patient had no other illness.

A biopsy specimen from the lesion showed a granulomatous inflammatory dermal infiltrate composed of lymphocytes and foreign-body giant cells in the active border of the lesion. In the inner part of the lesion, epidermal atrophy and horizontally aligned collagen fibres with slight fibrosis were observed. Orcein stain revealed a few, thick, broken fibres in

the active border, but a loss of elastic fibres in the inner lesion. Adjacent and within the giant cells there were elastolytic fibres (Fig. 2). There was no palisading or necrosis. The laboratory data, including blood count, routine biochemistry, urinalysis, protein and immunoglobulin levels and antinuclear antibodies, were normal.

At the time of presentation, the patient had been involved in a car accident and was suffering from traumatic wounds to the lesion which had quickly spread again (Fig. 3). We treated the active erythematous border with intralesional corticosteroids which stopped growth and the lesion improved.

### DISCUSSION

Actinic granuloma (AG) was first described by O'Brien in 1975 (1) and confirmed by Toribio et al. in 1978 (2) as asymptomatic annular lesions similar to those of granuloma annulare that spread on sun- or heat-damaged skin. It is characterized histopathologically by giant cell elastophagocytosis in the active border, loss of elastic fibres in the inner and a prominent actinic elastosis surrounding the annular plaque. The term 'actinic' indicates its external or environmental origin, embracing every form of electromagnetic radiation such as ultraviolet, visible light, infrared and X-ray (1). In 1979, Hanke et al. (3) described a similar picture in non-sun-damaged skin as annular patches with erythematous borders and hypopigmented centre but without solar elastosis, namely AEGCG. The authors rejected its actinic origin as they did not find actinic damage at the site of the lesions and it remains as an entity with unknown aetiology. Main histological changes taking place in AEGCG include the presence of giant cells, granulomatous inflammation and loss of

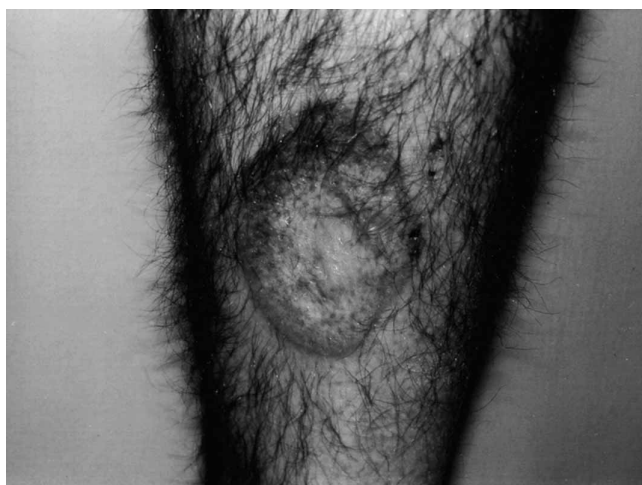

Fig. 1. Clinical aspect of the lesion. Subjacent vascularization could be observed through the atrophic, hypopigmented, hairy-free centre.

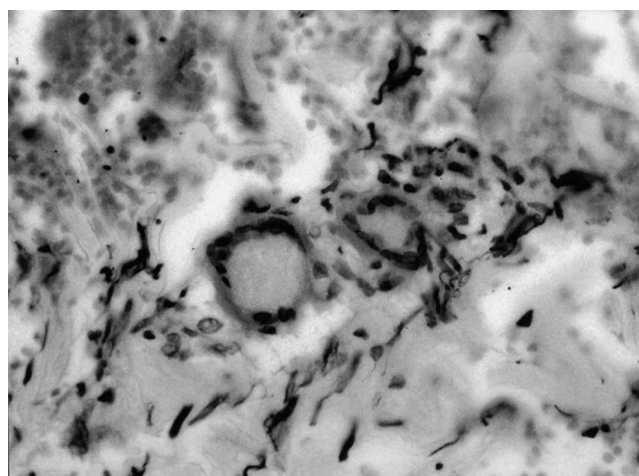


Fig. 2. Elastophagocytosis in the border of the lesion. Orcein stain (ORC × 400).

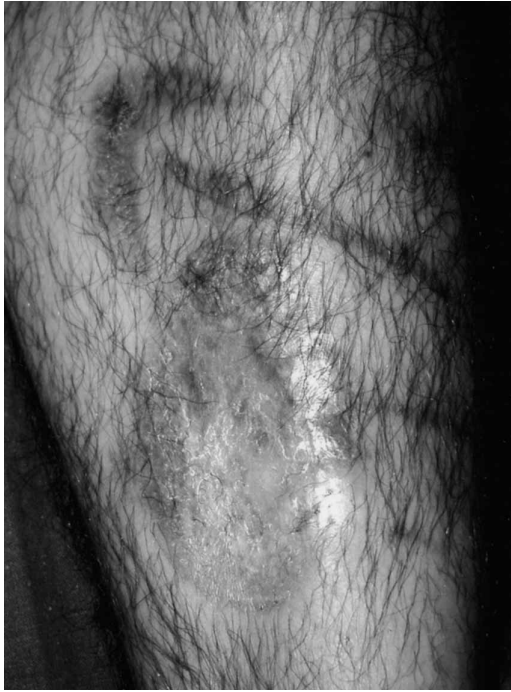

Fig. 3. The lesion after a mechanical trauma as a result of a car accident. The erythematous and elevated border can be observed in the upper and lower regions.

elastica. Similar lesions of AG and AEGCG include atypical necrobiosis lipidica of the face and scalp (4), Miescher's granuloma of the face (5) and granuloma multiforme (6).

In our patient, a unique lesion appeared on an old burn scar in non-sun-exposed skin. Many years later, after a mechanical trauma, the lesion started to spread again. This might suggest that burns could be precursors of AEGCG, and injuries in the area could produce new activity in the border. Heat or chronic heat damage might change the antigenicity of elastic fibres. As O'Brien described (1), perhaps the traumatic effects of long-term radiant heat on the dermis have been underestimated. In experiments of short duration, Rasmussen et al. (7) have shown that the dermis begins to undergo physical changes in vitro when it reaches 60°C and that this fact could produce the condition of elastolysis described as the prior state for development of the AG (1, 2). A human in vitro granuloma model (8) based on the co-incubation of L3 larvae of *Nippostrongylus brasiliensis* with human mononuclear blood cells is being used in the investigation of multinucleated giant cell and granuloma formation. In the future it could be a model for investigating the effects of heat on granuloma formation and its influence on elastolysis.

Several authors (9, 10) consider that AG is only a variant of granuloma annulare, which takes place in elastotic skin. These diseases are similar, but there are some differences. Palisading granulomas, necrobiotic foci and mucin deposits are more frequent in granuloma annulare (10), while the presence of collagen fibres aligned inside the annulus suggesting a scar is strongly suggestive of AG. A review of the clinical and

pathologic differential diagnosis of AEGCG can be found elsewhere (11, 12).

Özkaya-Bayazit et al. (12) described a patient with AEGCG on sun-exposed areas with sparing of an old burn scar with an almost complete absence of elastic fibres. This illustrates the importance of the dermal elastic tissue in the pathogenesis of the disease. The development of AEGCG could depend on the complete or incomplete absence of elastic fibres in the burn scar. Prior elastolysis is necessary for AEGCG to develop, but when the elastic fibres are absent the AEGCG will not appear since elastophagocytosis cannot occur.

In conclusion, heat and burns could be precursors of lesions of AEGCG as long as elastosis exists. Injuries in the area could modify the evolution of the lesion. In the literature, no references to AEGCG on a burn lesion or modifications of the course of this entity after mechanical trauma are reported, and to our knowledge this is the first time these features have been described in the course of AEGCG.

## REFERENCES

- O'Brien JP. Actinic granuloma: an annular connective tissue disorder affecting sun- and heat-damaged (elastotic) skin. *Arch Dermatol* 1975; 111: 460–466.
- Toribio J, Quiñones PA, Pérez-Oliva N. Granuloma actínico. *Actas Dermosifiliogr* 1978; 69: 289–294.
- Hanke CW, Bailin PL, Roenigk HH. Annular elastolytic giant cell granuloma. A clinicopathologic study of five cases and a review of similar entities. *J Am Acad Dermatol* 1979; 1: 413–421.
- Dowling GB, Wilson Jones E. Atypical (annular) necrobiosis lipidica of the face and scalp. A report of the clinical and histological features of 7 cases. *Dermatologica* 1967; 135: 11–26.
- Mehregan AH, Altman J. Miescher's granuloma of the face. A variant of the necrobiosis lipidica-granuloma annulare spectrum. *Arch Dermatol* 1973; 107: 62–64.
- Leiker DL, Kok SH, Spaas JAJ. Granuloma multiforme. A new disease resembling leprosy. *Int J Lepr* 1964; 32: 368–370.
- Rasmussen DM, Wakim KG, Winkelmann RK. Effect of aging on human dermis: of thermal shrinkage and tension. In: Montagna W, ed. *Advances in biology of skin. VI. Aging*. Oxford: Pergamon Press, 1965: 151–162.
- Seitzer U, Haas H, Gerdes J. A human in vitro granuloma model for the investigation of multinucleated giant cell and granuloma formation. *Histol Histopathol* 2001; 16: 645–653.
- Ragaz A, Ackerman AB. Is actinic granuloma a specific condition? Another view: perhaps the concept should be extended. *Am J Dermatopathol* 1979; 1: 51–53.
- McGrae JD. Actinic granuloma. A clinical, histopathological and immunocytochemical study. *Arch Dermatol* 1986; 122: 43–47.
- Tock CL, Cohen PR. Annular elastolytic giant cell granuloma. *Cutis* 2000; 62: 181–187.
- Özkaya-Bayazit E, Büyükbabani N, Baykal C, Öztürk A, Okcu M, Soyer HP. Annular elastolytic giant cell granuloma: sparing of a burn scar and successful treatment with chloroquine. *Br J Dermatol* 1999; 140: 525–530.