

Supplementary material has been published as submitted. It has not been copyedited, typeset or checked for scientific content by Acta Dermato-Venereologica

Figure S1: Skin biopsy of hand lesions: papillomatosis accompanied by parakeratosis, hyperkeratosis, granular layer thickening and koilocytosis (haematoxylin-eosin, 100 $\times$ ).

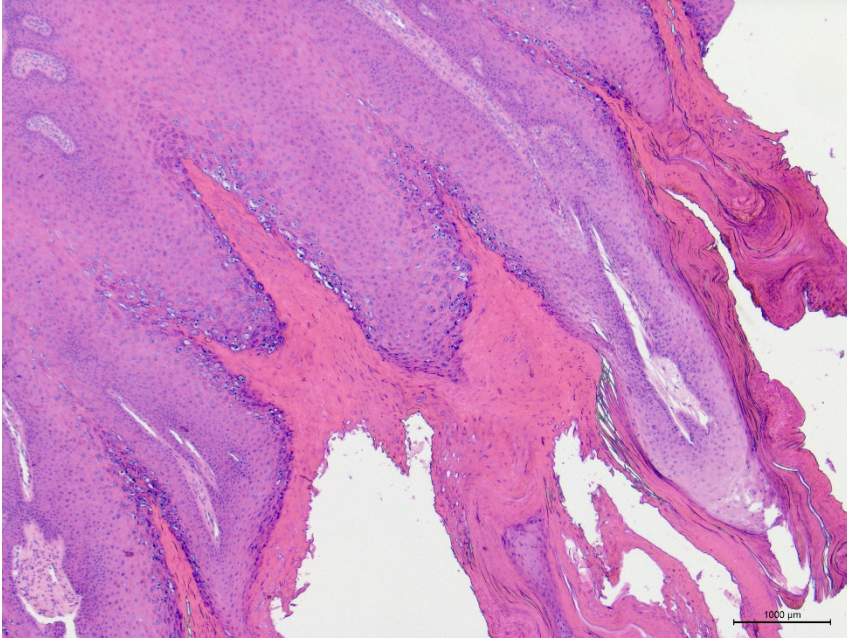


Figure S2: Illustration of combined treatment and skin lesions after starting dupilumab application. Significant improvements in GV lesions can already be seen before drugs are tapered (Pred, prednisone; MTX, methotrexate; DC, disease control; BP, bullous pemphigoid; GV, generalized verrucosis).

