

NEVUS COMEDONICUS

A Review of the Literature and Report of Twelve Cases

Hossein Nabai and Amir H. Mehregan

From the Department of Dermatology and Syphilology, Wayne State University School of Medicine, and Detroit General Hospital, Detroit, Michigan, USA

Abstract. We have reviewed the literature on nevus comedonicus and have reported 12 new cases. Clinical features and histopathologic findings are described and differential diagnosis from other follicular malformations is discussed.

Nevus comedonicus is a developmental anomaly of the pilosebaceous apparatus and is characterized clinically by aggregation of a number of dilated follicular orifices containing pigmented horny plugs. The lesion may be patchy, band-like or may show a zosteriform arrangement. Histologically there is cystic dilatation of the follicular canal and orthokeratotic plugging. This article is based on a review of the literature and study of 12 cases with nevus comedonicus. Clinical variations and histologic changes are described.

Historical

This entity was first described by Kofmann (8) in 1895. One year later, two publications appeared on the subject, one by Selhorst (16) under "nevus acneiformis unilateralis" and the other by Thibierge (19) as "nevus à comedons". White (20) in 1914 reported the first case in the American literature under the title of "nevus follicularis keratosus".

CLINICAL DATA

Incidence

Nevus comedonicus is a relatively rare nevoid malformation. Sweitzer & Winer (18) in 1932 found 29 cases recorded in the literature. Beerman & Homan (2) in 1959 reviewed 88 cases reported and added a series of eight new cases.

In a quite recent review, made by Wood & Thew (22) in 1968, the number of reported cases had increased to 125. Twelve cases reported in this article were found in a review of 100 000 biopsy specimens in a dermatopathology laboratory.

Sex

Review of the literature suggests no evidence of sex predilection or hereditary pattern for nevus comedonicus. Our series was made up of 8 females and 4 males.

Age

In most instances nevus comedonicus appears during the childhood or in adolescence. In one of our cases, the lesion was present at birth. In another case, the skin lesions developed at the age of 67, following a radical mastectomy.

Race

While most cases recorded are Caucasian, nevus comedonicus occurs in all races. One case in our series was a negro female.

Clinical appearance

The skin lesions consist of aggregation of discrete dilated follicular orifices plugged with pigmented keratinous material. The interfollicular epidermis appears normal or may be slightly hypo- or hyperpigmented. The lesion may form single or multiple plaques or show linear (3, 6), segmental, unilateral (15, 17), or zosteriform distribution (4). The most common site of involvement is the face (nine instances in our series). Trunk lesions were seen in 2 of our cases and on the arm in 1 case.

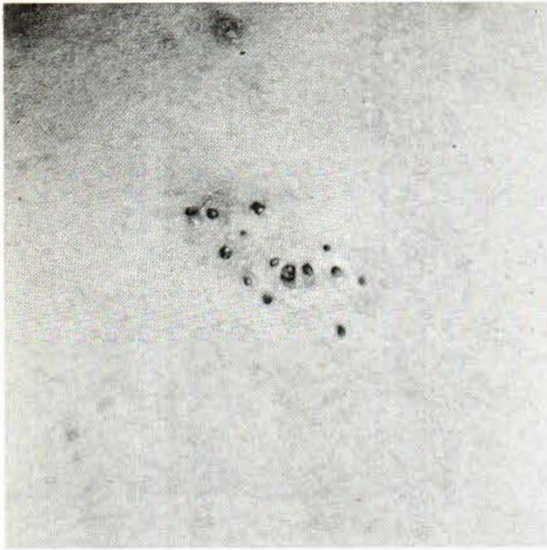


Fig. 1. A single patch of nevus comedonicus shows many dilated follicular pores containing pigmented keratinous material.

A case with a linear lesion involving the upper arm and extending into the palmar surface of the hand was reported by Wood & Thew (22). In another case reported by Klein (7) extensive involvement of the trunk occurred in association with lesions of the palms and the soles. In a case

reported by Paige & Mendelson (11) extensive nevoid malformation of the trunk and the face extended into the hairy scalp. In the areas of scalp involvement the hair shafts differed in texture and in color from the surrounding uninvolved areas. Late onset of the lesions has been reported following an attack of herpes zoster; and in association with nevus flammeus; ichthyosis (12); grand mal epilepsy (14), and right leg hypertrophy. Familial incidence has been recorded by Rodin (13).

Complications

One complication of nevus comedonicus is the development of chronic inflammation, suppuration, formation of fistula and hypertrophic scar (1). Hypertrophic or keloidal scar may also result from superficial destruction of the lesion or following biopsy. Secondary development of various forms of benign adnexal tumors or malignancies which is a hallmark of organoid nevi (10) (nevus sebaceus) has never been observed in nevus comedonicus.

HISTOPATHOLOGY

Nevus comedonicus is characterized histologically by cystic dilatation of the follicular canal containing keratinous material. The follicular wall

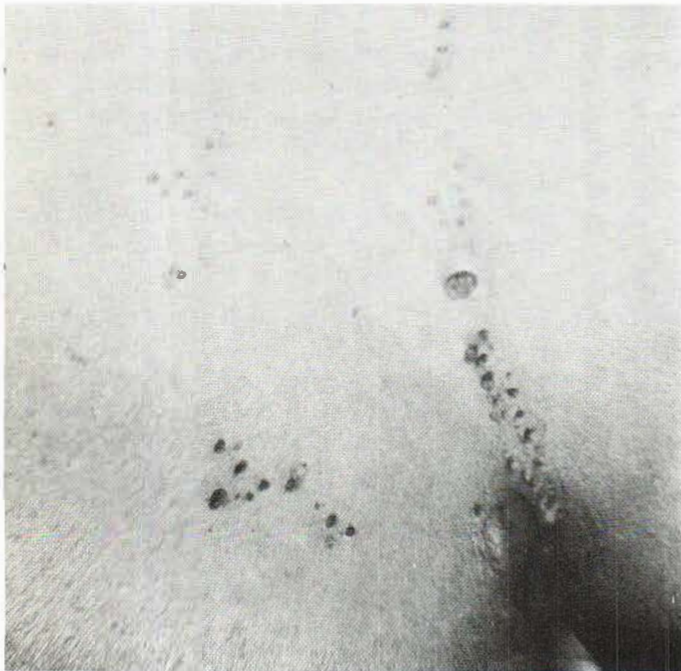

Fig. 2. Nevus comedonicus with unilateral distribution.

may be markedly atrophic or may show irregular proliferation with papillomatous projection into the surrounding corium, resembling the dilated pore of Winer (21). An atrophic or abortive hair follicle in connection with the cyst wall may be present in an early lesion. Sebaceous glands may also be present in this stage. In older lesions both hair follicles and sebaceous glands are usually absent. The interfollicular epidermis appears normal. In serial sections of our 12 cases we were unable to find any evidence of abnormal development of eccrine sweat glands or the presence of ectopic apocrine glands within the areas of nevoid malformation.

COMMENTS

Nevus comedonicus is a simple malformation of the pilosebaceous structures characterized by underdevelopment of the hair follicles and sebaceous glands with resulting cystic dilatation of the follicular canal and keratinous plugging. Normal appearance of the interfollicular epidermis, absence of sebaceous hyperplasia and lack of ectopic apocrine glands differentiate this simple malformation from the more complicated structure

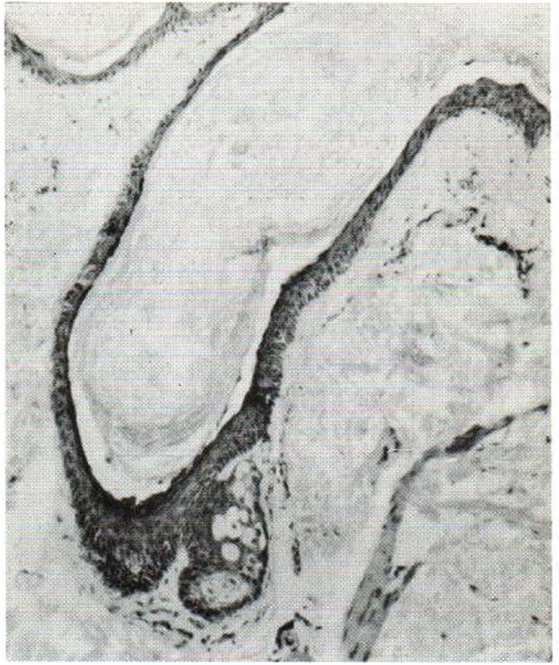


Fig. 4. Nevus comedonicus of an elderly individual shows dilated follicular pores and proliferation of follicular sheath epithelium resembling the dilated pore of Winer. Hematoxylin-eosin, $\times 50$.

of the organoid nevus (10) Nevus comedonicus may also be readily distinguished from folliculitis ulerythematosus reticulata which involves the cheeks in the form of ill-defined reticulated atrophic areas and is characterized histologically by malformation of the pilosebaceous structures in association with significant changes in the dermal connective tissue (9).

Finally, nevus comedonicus should be differentiated from the new entity described by Carneiro (5) as familial dyskeratotic comedones and also from generalized comedones which occur in older individuals in a diffuse and non-nevoid pattern. Nevus comedonicus may be treated for cosmetic reasons or for prevention of secondary inflammatory and pyodermic complications. Complete surgical excision is the most satisfactory approach. It is worth mentioning again that superficial destruction of these lesions often leads to development of hypertrophic or keloidal scar.

REFERENCES

1. Anderson, N. P., Ayres, S. & Kane, L. M.: Comedone nevus. *Acta Dermatovener (Stockholm)* 14: 199, 1933.

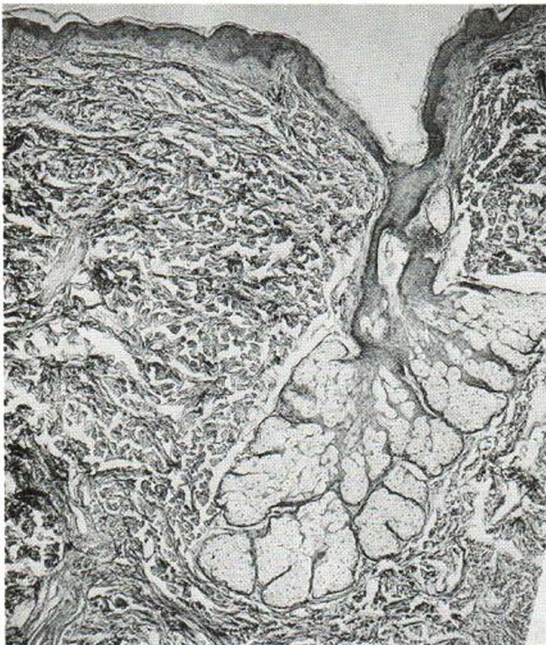


Fig. 3. An early lesion of nevus comedonicus containing a small hair shaft and well developed sebaceous glands. Hematoxylin-eosin, $\times 63$.

2. Beerman, H. B. & Homan, J. B.: Nevus comedonicus. *Arch Klin Exp Derm* 208: 325, 1959.
3. Bernucci, F.: Considerazione su di un nevoacronie lineare a comedoni. *Arch Ital Derm* 6: 26, 1930.
4. Blaschko, A.: Acne zosteriformis. *Arch Derm Syph* 123: 242, 1916.
5. Carneiro, S. J. C., Dickson, J. & Knox, J.: Familial dyskeratotic comedones. *Arch Derm (Chicago)* 105: 249, 1972.
6. Cohen, E. L.: Nevus acneiformer unilateralis. *Brit J Derm Syph* 55: 297, 1943.
7. Klein, A.: Über einen halbseitigen systematisierten Naevus follicularis Keratosus. *Arch Derm Syph* 124: 571, 1917.
8. Kofmann, S.: Ein Fall von seltener Localisation und Verbreitung von Komedonen. *Arch Derm Syph* 32: 177, 1895.
9. MacKee, G. M. & Paroungian, M. B.: Folliculitis ulerythemotosa reticulata. *J Cut Dis* 36: 339, 1918.
10. Mehregan, A. H. & Pinkus, H.: Life history of organoid nevi. *Arch Derm (Chicago)* 91: 574, 1965.
11. Paige, T. N. & Mendelson, C. G.: Bilateral nevus comedonicus. *Arch Derm (Chicago)* 96: 172, 1967.
12. Piers, F.: Linear comedo nevus and ichthyosis. *Brit J Derm Syph* 57: 138, 1945.
13. Rodin, H. H., Blankenship, M. L. & Bernstein, G.: Diffuse familial comedones. *Arch Derm (Chicago)* 95: 145, 1967.
14. Rook, A. J.: Systematized nevus comedonicus with epileptiform attacks, Case 3. *In Proceedings of the Tenth International Congress of Dermatology*, London, 1952, pp. 421-422.
15. Sayer, A.: Naevus acneiformis unilateralis (naevus follicularis keratosus) with report of a case. *Arch Derm Syph* 36: 1210, 1937.
16. Selhorst, S. B.: Naevus acnéiformis unilateralis. *Brit J Derm* 8: 419, 1869.
17. Senear, F. E. & Perlstein, M. O.: Nevus unilateralis comedonicus. *Arch Derm Syph* 32: 680, 1935.
18. Sweitzer, S. E. & Winer, L. H.: Naevus unilateralis comedonicus. *Arch Derm Syph* 26: 694, 1932.
19. Thibierge, G.: Naevus acnéique unilateral en bandes et en plaques (naevus à comedons). *Ann Derm Syph* 7: 1298, 1896.
20. White, C. J.: Naevus follicularis keratosus. *J Cut Dis* 32: 187, 1914.
21. Winer, L. H.: The dilated pore, a trichoepithelioma. *J Invest Derm* 23: 181, 1954.
22. Wood, M. G. & Thew, A. M.: Nevus comedonicus. A case with palmar involvement and review of the literature. *Arch Derm (Chicago)* 98: 111, 1968.

Received May 26, 1972

Amir H. Mehregan, M.D.
 Pinkus Dermatopathology Laboratory
 415 South Monroe Street
 P.O. Box 360
 Monroe, Michigan 48161
 USA