

MORPHOMETRIC ANALYSIS OF THE DOMINANT AND SEX-LINKED FORMS OF ICHTHYOSIS VULGARIS

J. E. Fräki, K. Kuokkanen and V. K. Hopsu-Havu

From the Departments of Dermatology and Anatomy, Universities of Turku and Oulu, Finland

Abstract. Morphometric analysis of the dominant and sex-linked forms of ichthyosis vulgaris, based on the measurement of projected histological specimens, was carried out in order to find objective differences in the skin of the manifest and forme fruste forms of these diseases. The skin surface, stratum granulosum and basal cell lines were longer in ichthyosis than in the controls, but there were no differences between the two forms of ichthyosis. Stratum granulosum was significantly higher in the sex-linked form than in the others. The dominant form did not differ from the controls. The areas of the stratum corneum and granulosum in the specimens were significantly greater in the sex-linked form than in the others. The stratum spinosum was significantly greater in both forms of ichthyosis than in the control group. The dermis in the dominant form of ichthyosis was found to contain about twice the number of capillaries found in the controls. The density of capillaries was somewhat increased also in the sex-linked form. No differences in the densities of sweat glands, sebaceous glands and hair follicles were recorded between the various ichthyosis forms and the controls. The forme fruste forms appeared to lie morphometrically between controls and the manifest forms of ichthyosis. Objective histomorphometric measurements confirmed most of the visual evaluations of the histology of the dominant and sex-linked forms of ichthyosis and disclosed some new observations.

Ichthyosis vulgaris is the most common of the genodermatoses, comprising some 95% of all of them. Since the work of Orel (11), Bruhns (1) and Cockayne (2) ichthyosis is known to be inherited both as an autosomal dominant and as a sex-linked recessive trait. In the dominant type the inheritance is often irregular, this being partly due to the fact that mild forms are easily overlooked in practice as well as when preparing pedigrees for publication. A distinction between the two forms of ichthyosis can usually be made on the basis of careful clinical investigation (17). The autosomal dominant form is characterized by symmetrical, often mild lesions consisting of

small light-coloured scales (Fig. 1). Most severely involved are the extensor surfaces of the extremities, while neck and flexor surfaces are unaffected. Hyperkeratosis of palms and follicular keratosis occur frequently. The lesions in the sex-linked form are more severe, consisting of large and often dirty-coloured scales (Fig. 2). The face, neck and popliteal flexor surfaces are frequently affected. Follicular hyperkeratosis and "ichthyotic palms" do not occur (8, 15, 16, 17, 18). In the dominant form of ichthyosis vulgaris it is not known whether the clinical pictures of the homozygote and heterozygote differ from each other.

The histologic features of ichthyosis vulgaris are usually summarized as hyperkeratosis, thinning or absence of the stratum granulosum, follicular keratin plugs, irregular basal protrusions and decrease in the number of sweat glands (9, 10). Only recently some more definite histological observations have been recorded to differentiate between the sex-linked and dominant forms on morphological grounds (5, 8, 13, 16, 18).

Opinions concerning the histological characteristics of the two forms of ichthyosis agree in many points but disagree on some others (18). Differences of opinion may be partly due to the fact that an interpretation of the structure under the microscope is always subjective, unless objective means of measuring parameters are used. Since no objective morphometric analysis of the two forms of ichthyosis have been carried out, such a study was undertaken.

MATERIALS AND METHODS

The material consists of 19 families from northern Finland, in which their members suffering from ichthyosis




Fig. 1. Follicular hyperkeratosis and small scales in autosomal dominant ichthyosis.

vulgaris have been examined in the Department of Dermatology at the University of Oulu (8). Based on genetic and clinical observations the patients with ichthyosis vulgaris were divided into four groups: (i) 17 cases of the autosomal dominant form (I.d.), (ii) 24 cases of the autosomal dominant forme fruste (I.d.f.f.), (iii) 13 cases of the sex-linked (I.s.) form, and (iv) 19 cases of the sex-linked forme fruste (I.s.f.f.). The control samples were obtained from 75 healthy persons without ichthyosis. The age range was from six months to 80 years.

The biopsies were taken from the middle part of the lateral surface of the upper arm with 4 mm biopsy punch under local anesthesia (1% xylocain-exadrin). Samples were fixed in 10% formalin, embedded in paraffin and 5–6 μm sections were obtained. Sections were stained with hematoxylin-eosin. The skin specimens were re-embedded, if diagonal sections were obtained. Sections were projected with an episcopes on a wall to obtain a 450-fold magnification and typical areas were drawn on a standard size first class paper. Of each specimen, 3–6 sections were studied. The person who drew the pictures did not know the code of sections and diagnoses. The lengths of the surface of stratum corneum (skin surface line), of stratum granulosum and of the basal membrane were measured on the drawing with a curvimeter map-measurer. Stratum corneum, stratum spinosum and 50 basal cells were then cut from the paper and weighed on

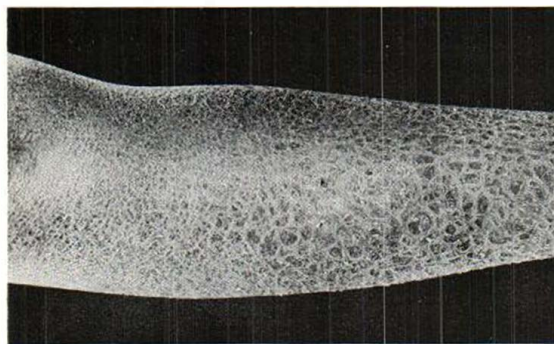


Fig. 2. Large scales of sex-linked ichthyosis.

a balance. The number of drawn capillaries were recorded. The numbers of sweat glands, sebaceous glands and hair follicles were recorded with careful microscopical observation of the sections.

Statistical analysis was performed with IBM 1130 computer. The following statistical methods were used: students *t*-test for pair comparison, Scheffe's method for multiple comparison, and χ^2 test for nonparametrical analysis.

RESULTS

A characteristic histological picture of I.d. and I.s. is shown in Figs. 3 and 4, respectively.

Length measurements

Skin surface. The skin surface of both types of ichthyosis was longer than in the controls ($p < 0.001$) (Table I). There was no difference between the two forms of ichthyosis. The means in f.f. forms lay between the controls and the manifest forms of the disease. I.d.f.f. differed statistically from I.d. but not from the controls. No statistical differences were found between I.s.f.f. and control or I.s.

Stratum granulosum. I.d. and I.s. did not differ from each other but both showed a significantly longer stratum granulosum than the control group. I.d.f.f. and I.s.f.f. as a group did not differ from the controls but I.d.f.f. alone as well as I.s.f.f. alone, when tested against the controls, gave statistically significant and almost significant differences, respectively. I.d.f.f. and I.s.f.f. did not differ significantly from each other.

Basal membrane. The length of basal membranes of I.d. and I.s. did not differ from each other but combined as a group they were significantly longer than all others as well as the controls. I.d.f.f. and I.s.f.f. did not differ from the controls or from each other.

Height of stratum granulosum. The height of stratum granulosum in I.s., obtained by dividing the area of stratum granulosum by its length, was significantly greater than that in the others (Table II). I.d. did not differ significantly from the controls. I.d.f.f. and I.s.f.f. did not differ significantly from each other or from the controls.

Area measurements

Stratum corneum. The area of stratum corneum in I.s. was almost significantly larger than in I.d. ($p < 0.05$), the mean in I.s. being about twice

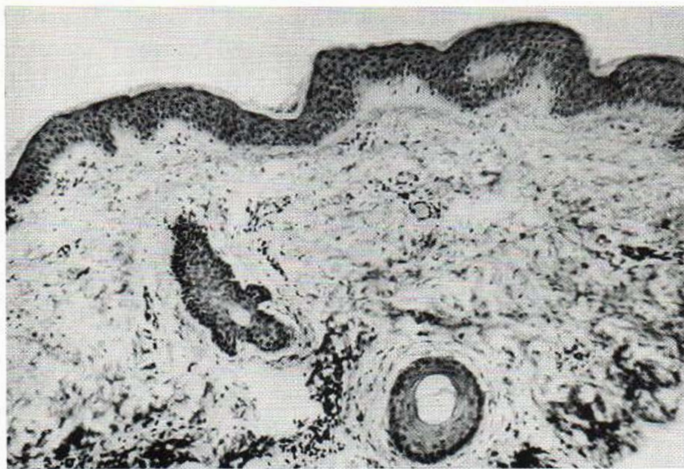

Fig. 3. A characteristic histological picture of autosomal dominant ichthyosis.

that in I.d. (Table III). I.d. did not differ from the controls but I.s. differed significantly. The variation was great in I.d. Neither I.d.f.f. nor I.s.f.f. differed significantly from the control group, even though their means were somewhat higher.

Stratum granulosum. This was almost significantly greater in I.s. than in I.d. ($p < 0.05$). It was significantly greater than those of the other groups. Even in I.d., stratum granulosum was greater than in the controls. I.s.f.f. was almost significantly above the controls. In I.s. it was almost significantly greater than in I.s.f.f.

Stratum spinosum. This did not differ significantly in I.d. and I.s. In both of them this was significantly greater than in the controls. I.d.f.f. and I.s.f.f. did not differ from the controls or from each other. I.d. was almost significantly greater than I.d.f.f.

Basal cells. The areas of 50 basal cells in I.d.

and I.s. did not differ significantly from each other or from the controls. In I.d.f.f. and I.s.f.f. this was, oddly enough, smaller than in the controls.

Capillaries and adnexa

Capillaries. In I.d. the number of capillaries was almost significantly greater than in I.s. (Table IV). I.d. and I.s. differed significantly from the controls and I.d.f.f. This signifies a greater number of dermal capillaries in the ichthyotic patients than in controls or forme fruste manifestations.

Sweat glands. The frequency of sweat glands was the same in the controls, I.d., I.s. and their forme fruste manifestations.

Sebaceous glands. The frequency of sebaceous glands in these groups did not differ significantly from each other. However, the frequency of glands in I.s. was about half of that found in the controls, the difference being almost significant.

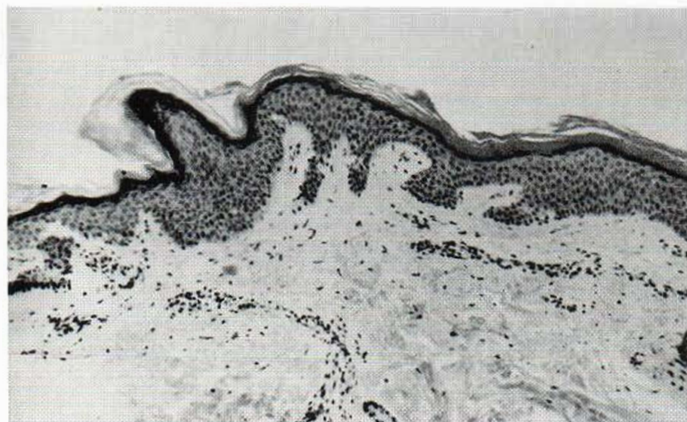


Fig. 4. A characteristic histological picture of sex-linked ichthyosis.

Table I. Length measurements (arbitrary units)

No.	Diagnosis		Skin surface	Stratum granulosum	Basement membrane
1	I.d.	<i>m</i>	550	560	730
		S.D.	86	100	150
		<i>n</i>	15	17	17
2	I.d.f.f.	<i>m</i>	490	530	650
		S.D.	31	47	120
		<i>n</i>	24	24	24
3	I.s.	<i>m</i>	550	580	800
		S.D.	110	130	260
		<i>n</i>	13	13	13
4	I.s.f.f.	<i>m</i>	500	550	630
		S.D.	61	140	110
		<i>n</i>	19	19	19
5	Control	<i>m</i>	480	500	650
		S.D.	41	41	120
		<i>n</i>	73	75	75

Statistical analysis of differences:

Skin surface	Stratum granulosum				Basement membrane							
	1	2	3	4	1	2	3	4				
2	**				2	o		2	*			
3	o	*			3	o	o	3	o	*		
4	o	o	o		4	o	o	4	*	o	*	
5	***	o	***	o	5	***	***	5	*	o	**	o

Scheffe's method, confidence coefficient 0.950

1 and 3 > all others 2 and 5 < all others 1 and 3 > all others
 2 and 5 < all others 5 < all others 3 > all others
 5 < all others 1 and 3 > 5 1 and 3 > 5
 1 and 3 > 5 1 and 5 < 3 1 and 3 > 2
 1 and 3 > 2 1 and 3 > 4

o = 2P > 0.05
 * = 2P < 0.05
 ** = 2P < 0.01
 *** = 2P < 0.001

Sebaceous glands were recorded in 3 out of 13 cases of I.s., in 6 out of 17 cases of I.d. and in 34 out of 75 controls.

Hair follicles. No significant differences were recorded in the frequency of hair follicles in the various groups.

DISCUSSION

Our morphometric analysis reveals objectively detectable differences in the morphology of the dominant and sex-linked types of ichthyosis. The genetic carriers, i.e. forme fruste cases who were clinically normal or had only mild skin changes, appeared morphometrically to lie between the normals and the manifest ichthyotic patients.

The length of the skin surface was similar in both forms of ichthyosis, showing that the general roughness of the surface does not differ in these

two forms of ichthyosis, although the surface contour is characteristic and nearly diagnostic: the scales are large and thick in the sex-linked, but small and powdery in the dominant form.

In the histologic sections, the considerably greater area (amount) of stratum corneum in the sex-linked than in the dominant form may be due to two factors. Firstly, the stratum corneum in the I.d. is definitely thinner and secondly, the stratum corneum of I.d. may be bound to the underlying structures more loosely and become more easily detached and lost during biopsy and tissue processing for microscopy. The latter could be a definite source of error. In fact, the standard deviation in the I.d. group was very large, indicating an occasional loss of stratum corneum.

The thickness of stratum granulosum is generally considered to be the most characteristic morphological difference between the I.d. and I.s. forms of ichthyosis: the layer is thick in I.s. and

Table II. Height of stratum granulosum (arbitrary units)

No.	Diagnosis		Stratum granulosum
1	I.d.	<i>m</i>	0.16
		S.D.	0.049
		<i>n</i>	17
2	I.d.f.f.	<i>m</i>	0.15
		S.D.	0.033
		<i>n</i>	24
3	I.s.	<i>m</i>	0.21
		S.D.	0.072
		<i>n</i>	13
4	I.s.f.f.	<i>m</i>	0.16
		S.D.	0.030
		<i>n</i>	19
5	Control	<i>m</i>	0.15
		S.D.	0.031
		<i>n</i>	75

Statistical analysis of differences:

	1	2	3	4	
2	o				o = 2P > 0.05
3	*	***			* = 2P < 0.05
4	o	o	**		** = 2P < 0.01
5	o	o	***	o	*** = 2P < 0.001

Scheffe's method 0.950 confidence coefficient 0.950

3 and 4 > all others
 2 and 5 < all others
 3 > all others
 1 and 3 > 2
 1 and 3 > 5

Table III. Area measurements (arbitrary units)

No.	Diagnosis		Stratum corneum	Stratum granulosum	Stratum spinosum	Basal cells
1	I.d.	<i>m</i>	510	89	1 200	56
		S.D.	300	32	310	8.4
		<i>n</i>	16	17	17	17
2	I.d.f.f.	<i>m</i>	550	78	970	44
		S.D.	220	17	230	11
		<i>n</i>	24	24	24	24
3	I.s.	<i>m</i>	860	130	1 300	54
		S.D.	540	54	300	13
		<i>n</i>	13	13	13	13
4	I.s.f.f.	<i>m</i>	580	91	1 100	50
		S.D.	350	37	360	14
		<i>n</i>	19	19	19	19
5	Control	<i>m</i>	470	76	990	56
		S.D.	220	19	260	12
		<i>n</i>	74	75	75	74

Statistical analysis of differences:

Stratum corneum					Stratum granulosum					Stratum spinosum					Basal cells				
	1	2	3	4		1	2	3	4		1	2	3	4		1	2	3	4
2	o				2	o				2	*				2		***		
3	*	*			3	*	***			3	o	***			3	o		*	
4	o	o	o		4	o	o	*		4	o	o	o		4	o	o	o	
5	o	o	***	o	5	*	o	***	*	5	o	o	***	o	5	o	***	o	o

Scheffe's method, confidence coefficient 0.950

5 < a.o.	2 and 5 < a.o.	1 and 3 > a.o.	2 and 4 < a.o.
3 > a.o.	3 and 4 > a.o.	2 and 5 < a.o.	2 < a.o.
1 and 3 > 5	5 < a.o.	2 < 1, 3 and 4	
3 and 4 > a.o.	1 and 3 > 2		
1 and 5 < 3	1 and 5 < 3		
	3 > a.o.		
	1 and 5 < 4		

o = $2P > 0.05$
 * = $2P < 0.05$
 ** = $2P < 0.01$
 *** = $2P < 0.001$
 a.o. = all others

thin or lacking in I.d. Our measurements verify this difference between the two forms of ichthyosis. However, no difference was objectively recorded between the I.d. and the control skin samples. This finding differs from the general view that the stratum granulosum in I.d. is thinner than in the normal controls (5). In this connection it should be borne in mind that our biopsies were taken from the lateral surface of the arms and the differences there may not be equally visible as in some other sites. In fact, a closer look at Table I of Feinstein et al. (5) shows. However, no difference was objectively re-disclosed that even though the stratum granulosum in leg biopsies was thinner than in the controls, a

similar difference could not be found in the biopsies taken from the arm. Erickson & Kahn (4) concluded that there is a marked decrease in the thickness of stratum granulosum in ichthyosis vulgaris. They did not, however, differentiate between the two forms of ichthyosis and the biopsies were taken from the buttock.

The area of stratum spinosum is an indication of the degree of acanthosis in the skin. It was found to be increased in both forms of ichthyosis, but there was no difference between the I.d. and I.s. forms. This finding corresponds to the general notion obtained on the basis of visual estimations. The fact that no marked differences were found in the sizes of the basal cells would sug-

Table IV. Capillaries and adnexa (arbitrary units)

No.	Diagnosis		Capillaries	Sebaceous glands	Sweat glands	Hair follicles
1	I.d.	<i>m</i>	20	f 0.59	1.5	1.7
		S.D.	7.0	(6/17)	(15/17)	(17/17)
		<i>n</i>	17			
2	I.d.f.f.	<i>m</i>	10	f 0.74	1.9	1.7
		S.D.	4.8	(13/24)	(24/24)	(21/24)
		<i>n</i>	24			
3	I.s.	<i>m</i>	14	f 0.31	1.6	1.5
		S.D.	4.6	(3/13)	(12/13)	(12/13)
		<i>n</i>	13			
4	I.s.f.f.	<i>m</i>	9.4	f 0.68	1.5	1.3
		S.D.	2.7	(10/19)	(18/19)	(16/19)
		<i>n</i>	19			
5	Control	<i>m</i>	11	f 0.63	1.4	1.3
		S.D.	4.2	(34/75)	(69/75)	(66/75)
		<i>n</i>	75			

Statistical analysis of differences:

Capillaries

	1	2	3	4	
2	***				o = 2P > 0.05
3	*	*			* = 2P < 0.05
4	***	o	***		** = 2P < 0.01
5	***	o	*	o	*** = 2P < 0.001

Scheffe's method, confidence coefficient 0.950

- 1 and 3 > all others
- 2 and 4 < all others
- 1 > all others
- 4 < all others

gest that there are no great differences in the rate of cell division and growth in these diseases. The long basal membrane in both I.d. and I.s. signifies the presence of papillomatosis in both forms of ichthyosis.

Our findings of more capillaries in the dermis of I.d. than in I.s. and normal skin is an interesting new finding. In fact, the number of capillaries was twice the control number and is quite apparent from a visual study of the sections, once it has been pointed out. This would suggest that the circulation in the I.d. dermis is more rapid than in the I.s. or controls. We could not, however, find any definite difference in the amount of the lymphohistocytic cells in the dermis.

The skin adnexa have been mentioned by several investigators of ichthyosis and decreased numbers of sebaceous and sweat glands have usually been claimed (3, 7, 9, 12, 10). In more recent investigations, differences have been found between the two forms of ichthyosis. Wells & Kerr (16) reported a decreased number of seba-

ceous glands in I.d. while Ziprkowski & Feinstein (18) found a normal number in I.s. but no glands in I.d. Our findings differ from those cited above since sebaceous glands were found in both forms of ichthyosis vulgaris and, in fact, they were more frequent in I.d. than in I.s. (6 out of 17 cases in I.d. and in 3 out of 13 cases in I.s.). Therefore, we do not consider the frequency of sebaceous glands to deviate from normal in these two diseases.

As to the frequency of sweat glands, Wells (14) and Wells & Kerr (16) reported a reduction in both types of ichthyosis. This could not be verified by Feinstein et al. (5). Frost & Van Scott (6) also state that sweat glands appear histologically normal in all forms ichthyosiform dermatoses. Our findings would seem to corroborate those of the later investigators since the frequency of sweat glands was essentially the same in all groups studied by us.

Hair follicles have been reported to be present in all forms of ichthyosis and no specific differ-

ences between the two types have been mentioned. Our findings similarly do not disclose any differences characteristic of either form of the disease.

In the practical differential diagnosis of I.s. contra I.d., the characteristic features would be the thick and compact stratum corneum of I.s. and the looser structure of I.d. Stratum granulosum is prominent in I.s. but not in I.d., acanthosis is the same, capillaries are more numerous in I.d. but not in I.s., and there is no quantitative difference in the adnexa. These criteria, combined with the clinical picture, make the differentiation of these two diseases quite feasible.

REFERENCES

1. Bruhns, C.: Ichthyosis. In *Handbuch der Haut- und Geschlechtskrankheiten* (ed. J. Jadahssohn), Bd. VIII/2, pp. 1-100. Springer-Verlag, Berlin, 1931.
2. Cockayne, E. A.: Inherited abnormalities of the skin and its appendages. In *Ichthyosis*, pp. 158-217. University Press, London and Oxford, 1933.
3. Degos, R.: *Dermatologie* (Collection Medicochirurgicale a Revision Annuelle). Flammarion, Paris, 1953.
4. Erickson, L. & Kahn, G.: The granular layer thickness in atopy and ichthyosis vulgaris. *J Invest Derm* 54: 11, 1970.
5. Feinstein, A., Ackerman, A. B. & Ziprkowski, L.: Histology of autosomal dominant ichthyosis vulgaris and X-linked ichthyosis. *Arch Derm (Chicago)* 101: 524, 1970.
6. Frost, P. & Van Scott, E. J.: Ichthyosisform dermatoses. *Arch Derm (Chicago)* 94: 113, 1966.
7. Gans, O. & Steigleder, G. K.: *Histologie der Hautkrankheiten*. Springer, Berlin, 1955.
8. Kuokkanen, K.: Ichthyosis vulgaris. *Acta Dermatovener (Stockholm)* 49: Suppl. 62, 1969.
9. Lever, W. F.: *Histopathology of the Skin*, 3rd ed. Pitman, London, 1961.
10. Montgomery, H.: *Dermatopathology*. Hoeber, New York, 1967.
11. Orel, H.: Die Vererbung der Ichthyosis congenita und der Ichthyosis vulgaris. *Z Kinderheilk* 47: 312, 1929.
12. Percival, G. H., Montgomery, G. L. & Dodds, T. C.: *Atlas of Histopathology of the Skin*, 2nd ed. Livingstone, Edinburgh, 1962.
13. Schnyder, U. W.: Inherited ichthyosis. *Arch Derm (Chicago)* 102: 240, 1970.
14. Wells, R. S.: Ichthyosis. *Brit Med J* II: 1504, 1966.
15. Wells, R. S. & Kerr, C. B.: Genetic classification of ichthyosis. *Arch Derm (Chicago)* 92: 1, 1965.
16. — The histology of ichthyosis. *J Invest Derm* 46: 530, 1966.
17. — Clinical features of autosomal dominant and sex-linked ichthyosis in an English population. *Brit Med J* 1: 947, 1966.
18. Ziprkowski, L. & Feinstein, A.: A survey of ichthyosis vulgaris in Israel. *Brit J Derm* 86: 1, 1972.

Received October 6, 1972

V. K. Hopsu-Havu, M.D.
Department of Dermatology
University of Turku
Turku 3
Finland