

ERYTHEMA NODOSUM MIGRANS

Matti Hannuksela

From the Department of Dermatology, University Central Hospital, Helsinki, Finland

Abstract. Among 438 patients with erythema nodosum (EN) seen during the period 1963-1971, 56 had erythema nodosum migrans (ENmi). Only 3 of them were men. The number of ENmi nodules varied from one to eight, and in 40 patients they were situated unilaterally. The mean duration of the eruption was 4.5 months and the nodes disappeared without scarring. The patients' general condition was good. Fever and arthralgia were rare. In half of the ENmi cases, examination revealed no disease or other condition underlying the eruption. Of the conditions possibly triggering ENmi, pregnancy was recorded most often (40%). Streptococcal infections and sarcoidosis were next in rank. The number of users of oral contraceptives among EN patients was 2½ times as high as expected on the basis of sales figures. Nosologically, ENmi is regarded as a clinical variant of typical EN, not to be confused with other nodular diseases affecting the legs.

Erythema nodosum migrans (ENmi) was first described by Bäfverstedt in 1954 (1): "It presents, either from the onset, or in the further course, nodose efflorescences which blanch in the center and progress 'while dividing up' centrifugally (i.e. migrate)." As compared with typical erythema nodosum, "The nodules persist somewhat longer, are less tender, and show a more conspicuous asymmetrical, or purely unilateral localization. The histology is that typical of erythema nodosum." In his later study, Bäfverstedt (2) found that migration of the nodules was not a constant feature.

Bäfverstedt himself (1, 2) published 20 cases of ENmi, but since then little attention has been paid to this form of erythema nodosum. A few authors have presented their opinions on its relation to the other nodules-on-legs syndromes. According to most of them, ENmi is only one name for a disease also known as subacute migratory non-suppurative panniculitis, nodular vasculitis and Whitfield's erythema induratum (6, 10). On

the other hand, Hellerström (8) has accepted Bäfverstedt's view. Bäfverstedt emphasized later that ENmi should not be identified or confused with such conditions as subacute nodular migratory panniculitis or other forms of hypodermatitis, panniculitis, vasculitis, etc., with divergent histology and mixed clinical and/or histopathological content (3). In a previous study (7), I presented 36 cases of ENmi. Further studies on this clinical variant of erythema nodosum are reported here.

MATERIAL AND METHODS

The study was performed at the Department of Dermatology, University Central Hospital, Helsinki, in 1963-1971. During these years, 438 patients with erythema nodosum were seen, 56 of whom had ENmi. In all cases, a careful inquiry was made about the medical history, including the use of oral contraceptives and other hormones. On admission, the following examinations were performed: chest X-ray, quantitative tuberculin test, Kveim test, haemoglobin, white blood cells (total and differential counts), erythrocyte sedimentation rate, antistreptolysin titre (AST), antistaphylococcal titre, serum creatinine and routine urine examinations. Throat swab culture for haemolytic streptococci and culture for tubercle bacilli from sputum or gastric lavage were done in most cases, as well as electrocardiogram, serum glutamine-oxaloacetic transaminase, alkaline phosphatase, *Yersinia* antibody titre (agglutination test), and paper electrophoresis.

Diagnostic criteria for sarcoidosis were bilateral hilar adenitis (and possibly other changes) compatible with sarcoidosis seen in the chest X-ray, a typical clinical picture (skin sarcoidosis, uveitis, parotitis, or a combination of these), a positive histological finding from lymph nodes or other organs, or a positive Kveim test.

Cases with tonsillitis at most 3 weeks before erythema nodosum and with AST of over 250, those with a positive throat swab culture for haemolytic streptococci (group A), and those with AST of over 500 with or without signs of streptococcal infection were considered to be probably of streptococcal origin. Cases with tonsillitis but without a rise of AST above 250, and those with AST 250-500 but without signs of streptococcal infection were regarded as possibly streptococcal erythema nodosum.

Table I. Composition of the series and some clinical data

ENty=typical erythema nodosum. ENmi=erythema nodosum migrans

	ENty		ENmi		Total	
	No.	%	No.	%	No.	%
Women	340	89	53	95	393	90
Men	42	11	3	5	45	10
Total	382		56		438	
Age (years)						
16-25	67	18	18	32	85	19
26-35	139	36	21	38	160	37
36-45	90	24	9	16	99	23
46-55	56	15	6	11	62	14
≥ 56	30	8	2	4	32	7
Seasonal onset of the eruption						
Jan.-Mar.	124	32	22	39	146	33
Apr.-June	121	32	18	32	139	32
July-Sept.	50	13	8	14	58	13
Oct.-Dec.	87	23	8	14	95	22
Duration of the eruption (weeks)						
≤ 3	135	35	0	0	135	31
3 ≤ 6	166	43	5	9	171	39
6 ≤ 9	43	11	4	7	47	11
> 9	38	10	47	84	85	19
Recurrent eruption	48	13	15	27	63	14

Yersinia titres of over 80 were considered suggestive of present or recent infection.

The diagnosis of tuberculosis was based on the finding of tubercle bacilli in culture, or on histological or radiological evidence of active tuberculosis.

The most important clinical data are seen in Table I.

Table II. The occurrence of erythema nodosum migrans in the various aetiological groups

EN=erythema nodosum. ENmi=erythema nodosum migrans

Group	No. of cases of EN	ENmi		Duration of the eruption in ENmi (mean) (months)
		No.	%	
Sarcoidosis	181	5	3	4.5
Streptococcal infections	88	9	10	3.1
Pregnancy	25	10	40	5.3
Yersiniosis	46	0	0	
Other causes	37	3	8	7.5
Cause unknown	117	31	27	4.9
Whole series	438	56	13	4.5

RESULTS

In most cases, the factors underlying ENmi remained obscure. Of the possible causes of ENmi, pregnancy was recorded relatively more often than the others (Table II). Sarcoidosis was seldom implicated and yersiniosis was not found in a single case.

The eruption was unilateral in 40 cases (71%). The number of nodules varied from one to eight, and they were mostly situated on the frontal or lateral surfaces of the leg. In no case were they found on other parts of the body. In 11 cases, the nodes really did migrate (not merely growing in size) and in 6 further cases, burst out to form new ones (Fig. 1).

The duration of the eruption is seen in Table II. It was longer in pregnancy than in the other aetiological groups. The nodules usually appeared in the second to fourth month of pregnancy and persisted until delivery.

The patients' general condition remained excellent during the eruption. Local pain at the sites of the nodules was the most usual attendant symptom. Five patients had arthralgia. In 8 cases, an axillary temperature of over 37.0°C (up to 39.4°C) was recorded. Only two of them had fever of over 38.0°C.

Histological changes compatible with erythema nodosum were seen. In the dermis, only perivascular lymphocytic infiltrations were present. The major changes were found in the hypodermal tissue: Accumulations of lymphocytes, histiocytes and occasional giant cells in the septa of fat lobules and between fat cells (Fig. 2). No dermal or subcutaneous necrosis was present. In some cases, slight vasculitic changes were seen in small vessels and medium-sized veins.

DISCUSSION

There is no universally accepted classification for the diseases presenting as nodules on the legs. Erythema nodosum in its typical form is easily diagnosed clinically even without histological examination. For the atypical forms of erythema nodosum, the term "chronic erythema nodosum" has been proposed (6). ENmi, the migratory panniculitis of Vilanova and Pinol Aguadé, erythema induratum Whitfield, and probably also nodular vasculitis, were considered to be different names

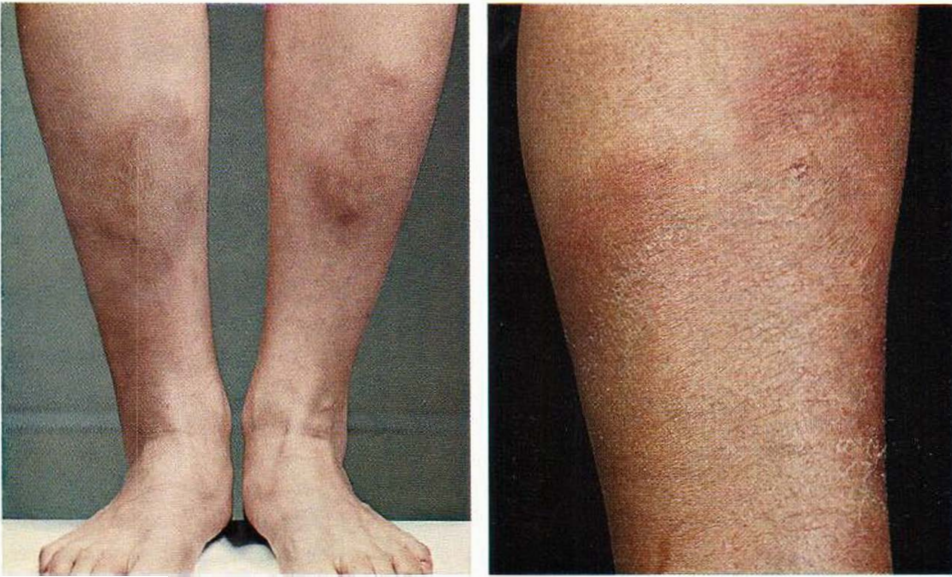

Fig. 1. (a) Centrifugally spreading nodules on both legs. (b) Migrating nodules on the right leg only. The original node has already disappeared.

for the chronic variant of erythema nodosum (6).

In many of the cases of Vilanova & Pinol Aguadé (15, 16), the description of the clinical appearance and course of the eruption closely resemble that of ENmi. However, in some of their 30 cases the disease presenting as an induration on the leg may have been necrobiosis lipoidica, and in some other cases even typical erythema nodosum. Although these authors regarded universal capillaritis as the initial lesion, and considered various changes in collagen to be characteristic of the condition, they also found infiltrates of fibroblasts, histiocytes and monocytes in the interlobular septa. A different view was taken by Perry & Winkelmann (13) who emphasized that in their 14 cases of subacute nodular migratory panniculitis, the giant cell reaction within the septa of the panniculus was more marked than the changes in the capillaries and small vessels. They also pointed out that the histological picture of erythema nodosum is often indistinguishable from subacute nodular migratory panniculitis. On the basis of case histories and findings, Perry & Winkelmann divided their cases into three groups. The first group (9 cases) met the criteria of Vilanova & Pinol Aguadé. The second group consisted of only 1 patient, with clinically and histologically typical migratory

panniculitis. The duration of the lesion was so short, however, that the diagnosis was considered to be in doubt. The nodules of the patients in the third group (4 cases) resembled those of erythema nodosum in their clinical features but were histologically indistinguishable from migratory panniculitis. In their whole series, there were 2 patients with ulcerating lesions. Thus it seems evident that even the series of Perry & Winkelmann was not uniform but consisted of patients with necrotizing panniculitis and non-necrotizing panniculitis (including erythema nodosum).

Erythema induratum Whitfield has been said to be a disease affecting middle-aged women, to have a recurrent or chronic course and to be histopathologically closely related to nodular vasculitis (4). In Whitfield's original paper (17), however, there were only 2 female patients with nodular eruptions on their legs. In one, a 14-year-old girl, the nodules were ulcerative, and in the other, a 37-year-old woman, they were non-ulcerating but painful and persisted for 10 weeks. Microscopic examination of the nodes revealed granulomatous panniculitis and vasculitic changes in veins and arteries in the former case, but only slight vasculitis in the veins of the subcutaneous tissue in the latter. It seems probable that the younger patient had Bazin's erythema

Table III. *Distribution of the women of fertile age taking contraceptive pills in the aetiological groups of erythema nodosum*

Group	No. of women taking the pill		No. of non-users	Total
	<3 months	3 months		
Sarcoidosis	0	6	5	11
Streptococcal infections	2	2	4 (1) ^a	8
Yersiniosis	0	2	6	8
Pregnancy	0	0	6 (3)	6
Other causes	0	0	1	1
Cause unknown	2	10 (3)	14 (7)	26
Whole series	4	20 (3)	36 (11)	60

^a The figures in parentheses are the numbers of cases with erythema nodosum migrans.

induratum and the older woman, typical erythema nodosum.

Nor does ENmi fit the criteria of nodular vasculitis. The term "nodular vasculitis" was introduced by Montgomery and his co-workers (11) for a clinical entity in which relatively chronic, persistent, or recurrent nodular lesions of non-tuberculous origin occur chiefly on the legs below the knees. The lesions occasionally result in ulceration and most of the patients are women of over 30. Histopathologically, definite vasculitis in both arteries and veins associated with necrosis of the fat and fibrosis is to be seen in the subcutaneous tissue. Obliterative changes also occur in veins and arteries to varying degrees but there is no evidence of true tubercle formation with caseation (12).

Immunohistological studies on the nodular diseases affecting the legs have revealed distinct differences between erythema nodosum, erythema induratum Bazin and non-definitive panniculitis (14). In typical erythema nodosum and in ENmi, no immunoglobulins were to be seen in the walls of dermal or subcutaneous veins or arteries, but they were very often found in erythema induratum Bazin and non-definitive panniculitis. These findings support the view that ENmi is not related either to Bazin's erythema induratum or to other necrotizing nodular diseases.

In Bäfverstedt's earlier study (1), there were 16 cases of ENmi. Apparently, in all cases the lesions migrated, i.e. either spread centrifugally or "wandered" (the old nodule disappeared while

a new one grew up just beside the old one). In Bäfverstedt's later study (2), there was no wandering in 2 out of 4 cases. In the present study, the nodules burst out to form two or more new migrating nodules in 6 cases, and in 11 further cases the nodes wandered without dividing up. In all cases, there was some fluctuation in the size of the nodes but this was not considered to be true migration.

Six of Bäfverstedt's (1, 2) 20 cases of ENmi were probably of streptococcal origin, 5 possibly of streptococcal origin and 4 probably provoked by sarcoidosis. In the remaining 5 cases the aetiology was obscure. In the present series, ENmi was associated with sarcoidosis in 5 out of 56 cases and with streptococcal infections in 9 but even more frequently with pregnancy (10/56).

The influence of pregnancy and contraceptive medication on the pathogenesis of erythema nodosum has not been widely examined. The eruption is more likely to appear during the first trimester of pregnancy than later (7), and recurrent erythema nodosum has been reported during two successive pregnancies (5). Erythema nodosum has also been considered to be a complication of contraceptive medication (9). My earlier study on erythema nodosum (7) was made at the time when oral contraceptives were introduced. Their use increased rapidly in the late sixties. During the last 3 years in Finland, 100 000–150 000 women (i.e. up to 16% of those of fertile age) have been taken these pills, according to the sales statistics. In 1969–1971, 24 out of 60 (40%) women of fertile age with erythema nodosum were under contraceptive medication at the onset of the eruption. The distribution of these cases according to the other possible triggering agents is presented in Table III. The high proportion of 'pill'-takers among the female patients with erythema nodosum supports the view that female sex hormones may often influence the host response to various agents.

In conclusion: ENmi is a clinical variant of erythema nodosum. The triggering agents are the same as in typical erythema nodosum, with the exception of yersiniosis.

REFERENCES

1. Bäfverstedt, B.: Erythema nodosum migrans. *Acta Dermatovener (Stockholm)* 34: 181, 1954.

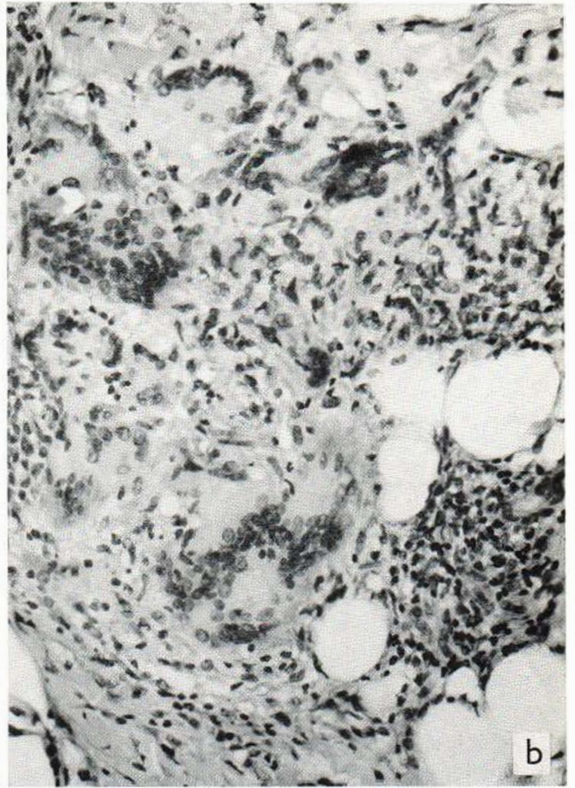
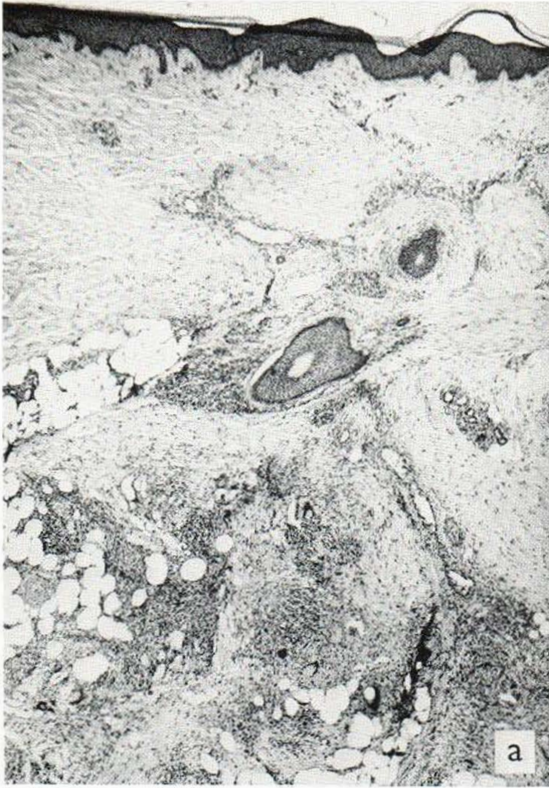

Fig. 2. (a) $\times 50$. Histological changes of erythema nodosum migrans lesion. Slight perivascular lymphocytic infiltrations are present in the dermis. The septa of the panniculus

adiposus are infiltrated with lymphocytes, histiocytes and giant cells. (b) $\times 260$. Numerous giant cells, histiocytes and round cells between fat lobules.

- Bärfverstedt, B.: Zur Kenntnis des atypischen Erythema nodosum. *Arch Klin Exp Derm* 208: 291, 1959.
- Erythema nodosum migrans. *Acta Dermatovener (Stockholm)* 48: 381, 1968.
- Champion, R. H. & Wilkinson, D. S.: Disorders affecting blood vessels. In *Textbook of Dermatology* (ed. A. Rook, D. S. Wilkinson & F. J. G. Ebling), pp. 446-466. Blackwell Scientific Publications, Oxford and Edinburgh, 1968.
- Daw, E.: Recurrent erythema nodosum of pregnancy. *Brit Med J* 2: 44, 1971.
- Fine, R. M. & Meltzer, H. D.: Chronic erythema nodosum. *Arch Derm (Chicago)* 100: 33, 1969.
- Hannuksela, M.: Erythema nodosum with special reference to sarcoidosis. *Ann Clin Res* 3: Suppl. 7, 1971.
- Hellerström, S.: Erythema nodosum. *Acta Dermatovener (Stockholm)* 46: 469, 1966.
- Holcomb, F. D.: Erythema nodosum associated with the use of an oral contraceptive. *Obstet Gynec* 25: 156, 1965.
- Lever, W. F.: *Histopathology of the Skin*. Fourth edition. Pitman Medical Publishing Company, London, 1967.
- Montgomery, H., O'Leary, P. A. & Barker, N. W.: Nodular vascular diseases of the legs. Erythema induratum and allied conditions. *JAMA* 128: 335, 1945.
- Montgomery, H.: *Dermatopathology*. Hoeber Medical Division, Harper & Row, New York, 1967.
- Perry, H. O. & Winkelmann, R. K.: Subacute nodular migratory panniculitis. *Arch Derm (Chicago)* 89: 58, 1964.
- Salo, O. P., Förström, L., Mustakallio, K. K., Niemi, K.-M. & Hannuksela, M.: Unpublished data.
- Vilanova, X. & Pinol Aquadé, J.: Hypodermite nodulaire subaiguë migratrice. *Ann Derm Syph* 83: 369, 1956.
- Subacute nodular migratory panniculitis. *Brit J Derm* 71: 45, 1959.
- Whitfield, A.: On the nature of the disease known as erythema induratum scrofulosorum. *Amer J Med Sci* 2: 828, 1901.

Received November 21, 1972

M. Hannuksela, M.D.
Department of Dermatology
University Central Hospital
Snellmaninkatu 14
SF-00170 Helsinki 17
Finland