

## INVESTIGATIVE REPORT

# Compound Heterozygosity for New Splice Site Mutations in the Plakophilin 1 Gene (*PKP1*) in a Chinese Case of Ectodermal Dysplasia–Skin Fragility Syndrome

Rui ZHENG, Ding-Fang BU and Xue-Jun ZHU

*Department of Dermatology, Peking University First Hospital, Beijing 100034, China*

Ectodermal dysplasia-skin fragility syndrome is a rare autosomal recessive inherited disease characterized by skin fragility, nail dystrophy and hyperkeratosis of palms and soles. Skin biopsy shows the loss of cell adhesion and the decrease of desmosomes in number and size. Mutations in *PKP1* have been found to be the underlying cause of the syndrome. We report here a Chinese case of ectodermal dysplasia-skin fragility syndrome. Mutation analysis revealed compound heterozygosity for mutations in *PKP1* of the proband. A new splice site mutation (c.1053 T>A+c.1054+1 G>T) near the 3' end of exon 5 and at the donor end of intron 5 on one allele was transmitted from the proband's mother. Another new splice site mutation (c.1835-2 A>G) near the acceptor end of intron 10 originated from her father. The absence of the mutant mRNA and plakophilin 1 protein in the proband's skin may result from the mechanism of nonsense-mediated mRNA decay induced by premature stop codons in *PKP1* transcripts due to the two splice site mutations. **Key words:** *ectodermal dysplasia-skin fragility syndrome; skin fragility; plakophilin 1; mutation; compound heterozygosity.*

(Accepted March 17, 2005.)

Acta Derm Venereol 2005; 85: 394–399.

Xue-Jun Zhu, MD, Department of Dermatology, Peking University First Hospital, Beijing 100034, China. E-mail: ZHUXJ@public.bta.net.cn

Ectodermal dysplasia-skin fragility syndrome (OMIM 604536) is a rare autosomal recessive inheritable disease characterized by skin fragility after birth, short and sparse hair, dystrophic nails and hyperkeratosis of palms and soles. Intelligence is usually not impaired in this condition. In 1997, McGrath et al. first reported that mutations in plakophilin 1 gene (*PKP1*) were the cause of the disease (1). Mutations in *PKP1* produce the loss of connection between epidermal cells, skin fragility and congenital ectodermal dysplasia. Since then, only seven cases have been reported in the literature (1–6). Here we report the study of *PKP1* mutations in a non-consanguineous Chinese family with a proband of ectodermal dysplasia-skin fragility syndrome. Two new mutations, an unusual splice site mutation inherited

from her mother and a splice site mutation from her father, were found in *PKP1* of the proband.

## MATERIALS AND METHODS

*The patient*

The proband, a 3-year-old girl, was the first child of healthy and non-consanguineous parents. She was found to have red papules on her face, sparse hair and dystrophic nails at birth. Bullae were also noted around her wrist where her identification label was worn. Skin fragility became prominent as shown by blisters and erosions on friction areas, such as thighs, buttocks, knees and heels. Scars were not found after healing of the bullae and erosions. Nails were yellow at birth, and became hollow and fragile gradually. The newly developed nails were dystrophic and thick. Perioral redness and fissures on lips, fragile skin, sparse hair and dystrophic nails then persisted (Fig. 1a–c). Significant hyperkeratotic and painful palms and soles developed after she was 18 months old. Perianal erythema and erosions were also noticed. Her intelligence and sweating were normal. She showed no evidence of dental, respiratory or gastrointestinal symptoms. No history of skin, hair and nail abnormalities was found in her family.

*Light and electron microscopy examinations*

A skin biopsy sample was used for routine pathological examination and electron microscopic studies. For electron microscopy, the sample was fixed in 2.5% glutaraldehyde and osmate solution then embedded in epoxy resin. Ultra-thin sections were stained with uranium acetate and lead citrate and examined with a transmission electron microscope.

*Immunohistochemistry*

Skin paraffin sections from the proband and a normal person as a control were mounted on slides pre-coated with polylysine and incubated in 10 mM citrate buffer (pH 6.0) in microwave oven for 15 minutes for antigen retrieval. The slides were then incubated with anti-plakophilin 1 monoclonal antibody (PP1-5C2, Cymbus, UK). The bound antibody was recognized by anti-mouse IgG antibody conjugated with horseradish peroxidase and visualized by diaminobenzidine staining.

*Mutation detection*

Genomic DNA samples were extracted from peripheral blood of the proband, her parents and grandmother and 50 normal controls by standard method. PCR primers for the amplification of the 13 coding exons and their flanking sequences were made based on the sequence of human *PKP1* gene. For

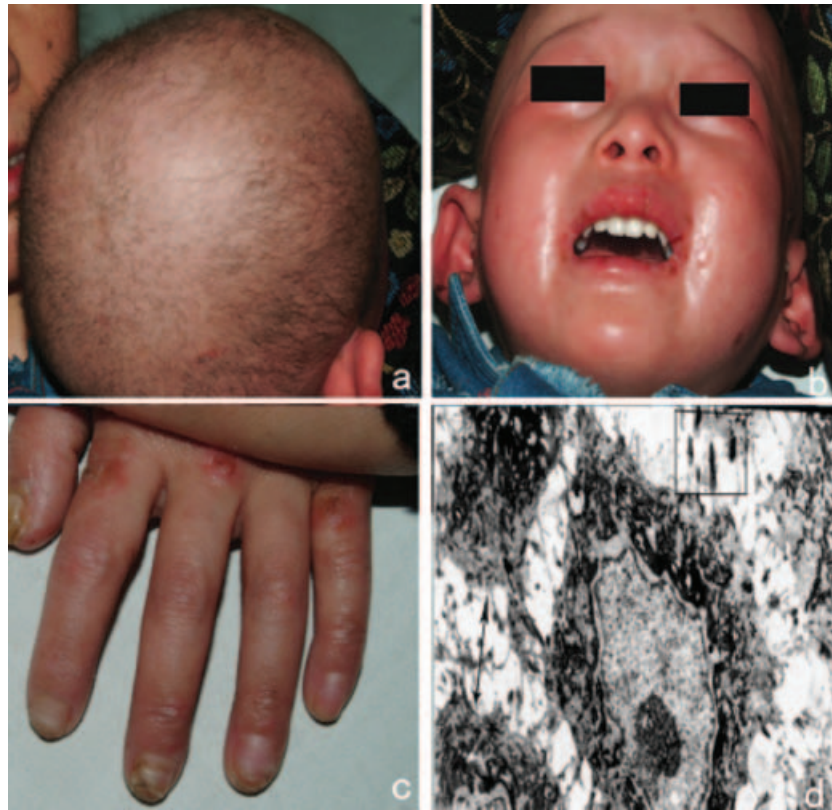


Fig. 1. The proband of ectodermal dysplasia-skin fragility syndrome. (a) Curly, short and sparse hair. (b) Red macules and fissures on lips and around her mouth. (c) Dystrophic nails, dispersed erythroedema, bullae and scars on a hand. (d) Electron microscopy shows loss of adjacent links, widened cell spaces (arrows), small desmosomes (square), crumpled nucleus, short and condensed tonofilaments and poor connection of tonofilaments to desmosomes at the cell periphery ( $\times 5000$ ).

the amplification of exon 5, the forward primer was 5'-GTT ATC ATG ACC TCA CAC TGC, the reverse primer was 5'-GGC CAG TGT CAC TAA ACT CTC, and the PCR product was expected to be 527 bp. For the amplification of exon 11, the forward primer was 5'-GGC AGA AGG CTA TCG AAG AG, the reverse primer was 5'-GTG AGG AGG GGC TCT GAT T, and the PCR product was expected to be 338 bp. PCR was performed in a total volume of 25  $\mu$ l containing 2.5  $\mu$ l 10 $\times$  PCR buffer, 0.2  $\mu$ M for each forward and reverse primer, 100  $\mu$ M for each deoxyribonucleoside triphosphate, 1.5 mM magnesium chloride, 100 ng genomic DNA and 1.25 U Taq DNA polymerase. The thermal cycle conditions were 94 $^{\circ}$ C for 45 seconds, 58–62 $^{\circ}$ C for 45 seconds and 72 $^{\circ}$ C for 45 seconds for 30 cycles. PCR products were separated in 1.5% agarose gel, cut under UV light, purified using silica beads, and sequenced in an ABI 377 automatic sequencer. PCR products amplified from exon 5 were digested with restriction enzyme *Bsr*SI to identify whether the two proximate mutations found by direct sequencing were located on one allele. PCR products from exon 11 were digested with restriction enzyme *Sma*I to further confirm the mutations detected by sequencing.

#### Reverse transcription-polymerase chain reaction

As a second skin biopsy was refused by her parents, reverse transcription-polymerase chain reaction (RT-PCR) was then performed using total RNA extracted from skin paraffin sections of the proband and a normal individual as a control

(7, 8). Several thick paraffin sections were incubated in 1 ml of TRIzol reagent (Invitrogen, Carlsbad, CA, USA) for at least 1 hour at 65 $^{\circ}$ C. Total RNA was then extracted according to the manufacturer's instructions. cDNA was generated from the total RNA by using random primers and M-MuLV reverse transcriptase. The outer primers for nested PCR across the identified splice site mutations were sense primer: 5'-CAA GGC TGT GCA GTA CCT GA (nucleotides 744–763 in the cDNA) and antisense primer: 5'-TAA GGT TCC CAG CAT GTT CC (nucleotides 2139–2120 in the cDNA). The first inner primer pair across the splice site mutation of (c.1053 T>A+c.1054+1 G>T) was sense primer: 5'-TTG GGG CCT ATT ACA TCC AG (nucleotides 791–810) and antisense primer: 5'-CGG TAG GAG AGG TTG TGC AG (nucleotides 1391–1372), and the size of a normal product was expected to be 601 bp. The second inner primer pair across the splice site mutation of (c.1835-2 A>G) was sense primer: 5'-CGC ACC TAC CTG AAC CTC AT (nucleotides 1585–1604) and antisense primer: 5'-AGG TTC CCA GCA TGT TCC TA (nucleotides 2137–2118), and the size of a normal product was expected to be 553 bp. For monitoring of the RT-PCR experiment,  $\beta$ -actin cDNA was also amplified. The forward primer was 5'-ATC TGG CAC CAC ACC TTC, the reverse primer was 5'-AGC CAG GTC CAG ACG CA, and the PCR product was expected to be 291 bp. The amplification condition was 94 $^{\circ}$ C for 2 minutes, followed by 94 $^{\circ}$ C 45 seconds, 60 $^{\circ}$ C 45 seconds, and 72 $^{\circ}$ C for 45 seconds for 33 cycles. PCR products were separated in 2% agarose gel.

## RESULTS

### Skin biopsy

Light microscopic examination showed hyperkeratosis, acanthosis and widening of intercellular spaces in the epidermis, i.e. in consistence with a previous report (1). The most prominent changes in electron microscopy examination were the loss of close contact between keratinocytes, widening of intercellular spaces and microvillus-like projections in the enlarged spaces and decrease in number and size of desmosomes. Tonofilaments became short and condensed, and poorly connected to desmosomes at the cell periphery. Nuclear membrane was crumpled (Fig. 1d).

### Immunohistochemistry

When skin section was reacted with anti-plakophilin 1 antibody, no signal was detected in the epidermis of the skin biopsy from the proband, while positive staining was found in the epidermis from a normal control (data not shown).

### Mutation detection

Three abnormal sequence changes confirmed by at least two independent PCRs and sequencing from both directions were found in the *PKP1* gene of the proband after all of the 13 coding exons were examined by PCR and direct sequencing. The first was a heterozygous nucleotide change (c.1053 T>A) (the prefix 'c.' indicates cDNA for the mutation numbering, numbering of cDNA nucleotide starts from the A of the translation initiation codon ATG) at the second nucleotide upstream from the 3' end of exon 5 (Fig. 2a). This nucleotide change does not change the codon. The second was a heterozygous nucleotide change (c.1054+1 G>T) located at the end of the donor site, a highly conservative site, of intron 5. Normally, the sequence around the end of exon 5 is ACTGgta (upper case, exon; lower case, intron), a site for restriction enzyme *BsrSI* (ACTGGN1/-1), and the PCR product amplified from normal exon 5 can be cut by *BsrSI* into 369 and 158 bp. One or both of the two sequence changes on one allele will result in the disappearance of this enzyme site. The proband carried the two heterozygous sequence changes, but the PCR product amplified from exon 5 could be partially cut by *BsrSI*, indicating that one of the alleles was normal and the two sequence changes were located on one allele (Fig. 2b). Therefore, a splice site mutation on one allele was composed of two sequence changes (c.1053 T>A+c.1054+1 G>T). The third sequence change was a heterozygous splice site mutation (c.1835-2 A>G) located in the highly conservative site, the second nucleotide upstream from the acceptor end of intron 10 (Fig. 3a). This heterozygous mutation creates

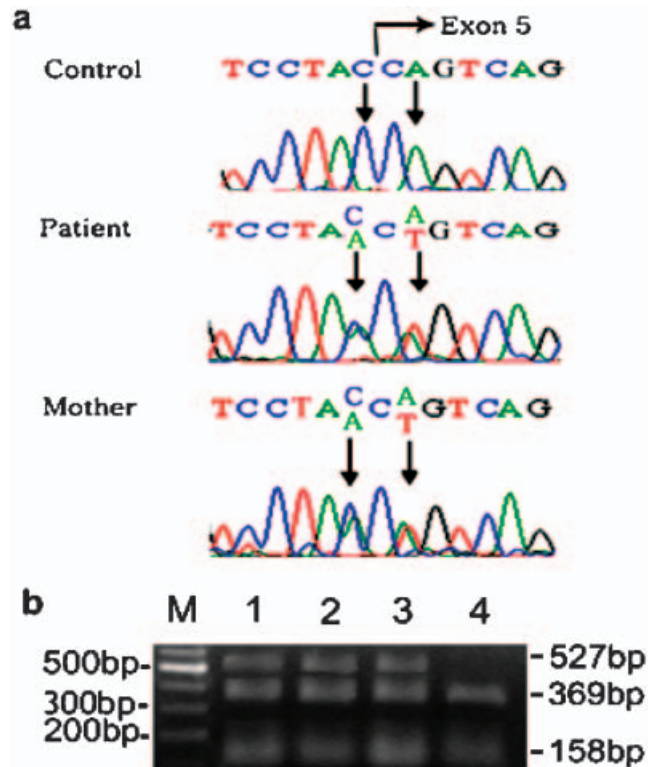


Fig. 2. (c.1053 T>A+c.1054+1 G>T) mutation in *PKP1*. (a) Direct sequencing of the PCR products amplified from exon 5 of the proband, her mother and a normal control and showing the sequencing results of the complementary strand. (b) Restriction enzyme *BsrSI* digestion of the PCR products amplified from exon 5. Lane 1, the proband; lane 2, her mother; lane 3, her grandmother; lane 4, her father; M, DNA molecular size marker of 100 bp apart (Huamei Biotech Co., Beijing, China).

a restriction enzyme *SmaI* site, and *SmaI* digestion of the PCR product confirmed the mutation (Fig. 3b). None of the three sequence changes were found in 50 normal controls and in the single nucleotide polymorphism (SNP) database at the NCBI website (9).

### RT-PCR analysis

No bands were detected from the skin cDNA of the proband using the two sets of inner primer pairs for nested PCR. However,  $\beta$ -actin cDNA could be amplified, indicating the successful performance of the RT-PCR using total RNA samples extracted from skin paraffin sections of the proband and a control. In contrast, PCR products of 601 bp and 553 bp were easily obtained from a normal control using the first and the second inner primer pairs, respectively (Fig. 4).

## DISCUSSION

The proband reported here had typical clinical manifestations of ectodermal dysplasia-skin fragility syndrome after birth. Immunohistochemistry using anti-plakophilin 1 antibody revealed the absence of plakophilin 1 protein

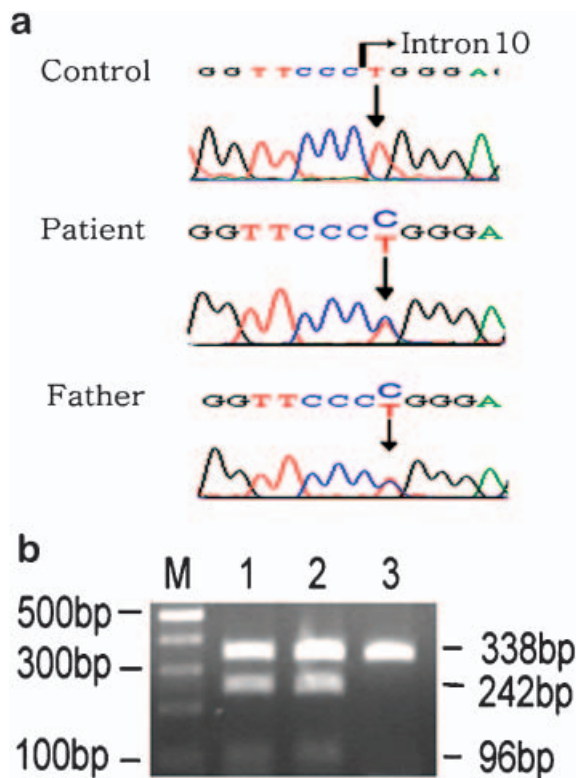


Fig. 3. (c.1835-2 A>G) mutation in *PKP1*. (a) Direct sequencing of the PCR products amplified from exon 11 of the proband, her father and a normal control and showing the sequencing results of the complementary strand. (b) Restriction enzyme *Sma*I digestion of the PCR products amplified from exon 11. Lane 1, the proband; lane 2, her father; lane 3, her mother; M, DNA molecular size marker of 100 bp apart (Huamei Biotech Co., Beijing, China).

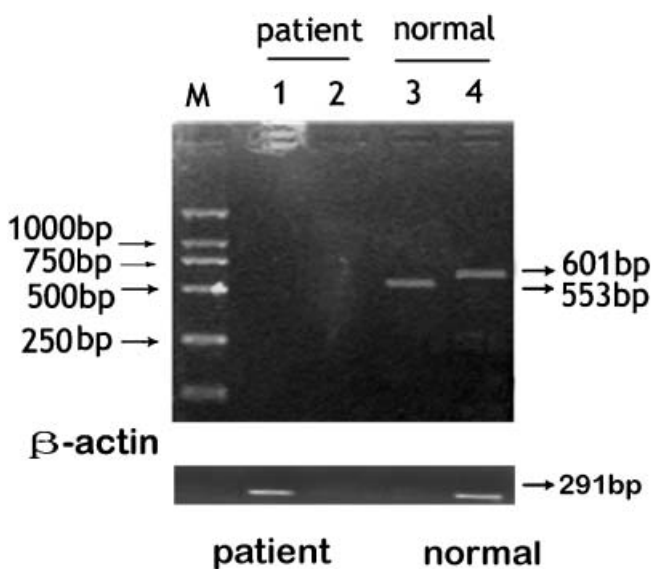


Fig. 4. RT-PCR of total RNA extracted from skin paraffin sections. Lanes 1 and 2, the proband; lanes 3 and 4, a normal control. Lanes 1 and 3, PCR using the second inner primer pair; lanes 2 and 4, PCR using the first inner primer pair. M, DNA molecular size marker (Takara Biotech Co., Dalian, China).

(PKP1) in the proband's epidermis. Ultrastructural study showed a decrease in number and size as well as abnormal structures of the desmosomes in epidermis. A comparison of the seven cases published previously with this case is shown in Table I. All cases had typical clinical manifestations including skin fragility and persistent perioral crusting and erosions after birth, and their PKP1 in epidermis was absent or reduced. In Table I, cases 1, 2 and 3 had bullae with generalized erythema like the colour of a cooked lobster, immediately after birth or in the first hour after birth, but cases 5 and 6 and the patient we report here only showed bullae without generalized erythema. Cases 4 and 7 in Table I had a special 'mitis' phenotype with reduced PKP1 rather than the absence of PKP1 in epidermis. Case 4 was normal until 3 months of age after a fever. In case 7, scalp hair was fragile and curly, but sparse hair was only seen on areas other than his scalp. The common clinical features of the seven cases were sparse hair, dystrophic nails and painful hyperkeratosis on palms and soles.

In this study, the two mutations found in *PKP1* of the proband are new mutations not reported previously. The heterozygous sequence changes of (c.1053 T>A) and (c.1054+1 G>T) were located on one allele. The sequence change of (c.1054+1 G>T) causes splice site mutation. Despite no resultant codon change, (c.1053 T>A) may cause abnormal splicing of PKP1 transcript due to its location close to the 3' end of exon 5. Therefore, the two close sequence changes can be recognized as one splice site mutation causing abnormal splicing of PKP1 mRNA near the 3' end of exon 5. The proband's grandmother and mother were the disease carriers, having the splice site mutation of (c.1053 T>A+c.1054+1 G>T) on one allele (Fig. 2). Her father was also a disease carrier, carrying a heterozygous mutation of (c.1835-2 A>G) which results in abnormal splicing of PKP1 mRNA at the 5' end of exon 11. The proband was a compound heterozygote of the two splice site mutations, (c.1053 T>A+c.1054+1 G>T) inherited from her mother and (c.1835-2 A>G) from her father. The normal phenotype of the proband's grandmother, mother and father indicates that carriers of *PKP1* mutations, i.e. individuals with haploinsufficiency, have no phenotype – in comparison to other desmosomal proteins, e.g. desmoplakin, desmoglein 1 (striate palmo-plantar keratoderma) (10, 11).

In general, splice site mutation will lead to skipping of an exon, inclusion of an intron in a transcript or using of a cryptic splice site (12). To characterize the consequence of the mutations, total RNA was extracted from skin paraffin sections of the proband and a normal control (7, 8). Two fragments of *PKP1* cDNA around the two mutation sites were amplified by nested RT-PCR. We could only amplify the two fragments from the normal control but not from the proband (Fig. 4).

Table I. Published patients with ectodermal dysplasia-skin fragility syndrome

Case (ref.)	Sex/Age	Age of onset	Genetic status	Mutation (location)	Consequence	PKP1 protein in epidermis
1 (1)	M/6 years	Birth	Compound heterozygote	Q304X (exon 4) 1132 ins 28 (exon 5)	PTC	Absent
2 (2)	M/18 months	Birth	Compound heterozygote	203-1 G>A (intron 1/exon 2) Y71X (exon 2)	PTC	Absent
3 (3)	M/17 years	Birth	Homozygote	1233-2 A>T (intron 5/exon 6)	PTC	Absent
4 (4)	M/42 years	3 months	Homozygote	2021+1 G>A (exon 11/intron 11)	PTC	Reduced
5 (5)	F/6 months	Birth	Homozygote	847-2 A>G (intron 3/exon 4)	PTC	Absent
6 (5)	F/3 years	Birth	Homozygote	203-1 G>A (intron 1/exon 2)	PTC	Absent
7 (6)	M/33 years	Birth	Homozygote	1680+1 G>A (exon 9/intron 9)	Loss of 45 bp in exon 9	Reduced
8 (this case)	F/3 years	Birth	Compound heterozygote	(c.1053 T>A+c.1054+1 G>T) (exon 5/intron 5) (c.1835-2 A>G) (intron 10/exon 11)	PTC	Absent

M, male; F, female; PTC, premature termination codon; *PKP1*, plakophilin 1 gene.

Using the splice site prediction method by Neural Network software (13), we found several possible consequences of exon skipping and activation of cryptic splice sites in case of the two splice site mutations. Apparently, the two splice site mutations on the two alleles will cause reading frame shift and nucleotide sequence changes downstream of the splice sites. Premature termination codons usually occur in this situation. The mutant mRNA, containing a premature termination codon, is easily degraded through the process of nonsense-mediated mRNA decay (14). This mechanism eliminates the deleterious effects of the truncated proteins and is probably protective. Therefore, PKP1 transcript and protein could not be detected in the proband's skin by nested RT-PCR and immunohistochemistry, and identification of sequence changes in PKP1 transcripts in the proband was impossible.

PKP1 is a major accessory protein in desmosomal plaques, playing key roles in recruiting desmosomal proteins, assembly of desmosomes and regulating cell migration (15). PKP1 belongs to the armadillo protein family, which consists of characteristic 9.2 armadillo repeats (16). The armadillo repeat is a tandem repeated sequence, about 40 amino acids long, which interacts with keratin intermediate filaments in cell. Many proteins with this structure are important regulators of signal transduction (17). The N-terminal of PKP1 is connected to the desmoplakin in desmosomes (18). To be components of desmosomes (16, 19, 20), PKP1 is concentrated in stratified epithelial desmosomes, but PKP2, a homologue of PKP1, is widely distributed in desmosomes of various epithelia as well as non-epithelial tissues such as myocardium. Recent studies

showed that mutations in PKP2 underlined arrhythmic right ventricular cardiomyopathy, a rare disease leading to syncope and sudden cardiac death (21).

Interestingly, all the patients reported to date had nonsense mutations and/or splice site mutations on both alleles of *PKP1*, and no missense mutations were found in the patients. Splice site mutation often causes a new premature stop codon due to reading frame shift. Premature stop codon in transcript induces the nonsense-mediated mRNA decay, resulting in a decrease or elimination of the mutant mRNA and its protein in tissues (22, 23). In patients with mild phenotype of the disease, residual mutant PKP1 may have partial functions. Absence of PKP1 causes the sparse and small desmosomes, disconnection of desmosomal plaques to keratin intermediate filaments, condensation of intermediate filaments and loss of cell-cell adhesion. Malfunctioning of keratin intermediate filaments also interferes with signal transduction among cells (17), which may be related to ectodermal dysplasia of the disease.

#### ACKNOWLEDGEMENTS

We are grateful to the patients and their families. We also thank our colleagues in the Department of Dermatology, Peking University First Hospital for their help.

#### REFERENCES

- McGrath JA, McMillan JR, Shemanko CS, Runswick SK, Leigh IM, Lane EB, et al. Mutations in the plakophilin 1 gene result in ectodermal dysplasia/skin fragility syndrome. *Nat Genet* 1997; 17: 240-244.

2. McGrath JA, Hoeger PH, Christiano AM, McMillan JR, Mellerio JE, Ashton GH, et al. Skin fragility and hypohidrotic ectodermal dysplasia resulting from ablation of plakophilin 1. *Br J Dermatol* 1999; 140: 297–307.
3. Whittock NV, Haftek M, Angoulvant N, Wolf F, Perrot H, Eady RA, et al. Genomic amplification of the human plakophilin 1 gene and detection of a new mutation in ectodermal dysplasia/skin fragility syndrome. *J Invest Dermatol* 2000; 115: 368–374.
4. Hamada T, South AP, Mitsuhashi Y, Kinebuchi T, Bleck O, Ashton GH, et al. Genotype-phenotype correlation in skin fragility-ectodermal dysplasia syndrome resulting from mutations in plakophilin 1. *Exp Dermatol* 2002; 11: 107–114.
5. Sprecher E, Molho-Pessach V, Ingber A, Sagi E, Indelman M, Bergman R. Homozygous splice site mutations in PKP1 result in loss of epidermal plakophilin 1 expression and underlie ectodermal dysplasia/skin fragility syndrome in two consanguineous families. *J Invest Dermatol* 2004; 122: 647–651.
6. Steijlen PM, van Steensel MA, Jansen BJ, Blokx W, van de Kerkhof PC, Happel R, et al. Cryptic splicing at a non-consensus splice-donor in a patient with a novel mutation in the plakophilin-1 gene. *J Invest Dermatol* 2004; 122: 1321–1324.
7. Mizuno T, Nagamura H, Iwamoto KS, Ito T, Fukuhara T, Tokunaga M, et al. RNA from decades-old archival tissue blocks for retrospective studies. *Diagn Mol Pathol* 1998; 7: 202–208.
8. Svoboda-Newman SM, Greenson JK, Singleton TP, Sun R, Frank TS. Detection of hepatitis C by RT-PCR in formalin-fixed paraffin-embedded tissue from liver transplant patients. *Diagn Mol Pathol* 1997; 6: 123–129.
9. <http://www.ncbi.nlm.nih.gov/>
10. Whittock NV, Ashton GH, Dopping-Hepenstal PJ, Gratian MJ, Keane FM, Eady RA, et al. Striate palmoplantar keratoderma resulting from desmoplakin haploinsufficiency. *J Invest Dermatol* 1999; 113: 940–946.
11. Hunt DM, Rickman L, Whittock NV, Eady RA, Simrak D, Dopping-Hepenstal PJ, et al. Spectrum of dominant mutations in the desmosomal cadherin desmoglein 1, causing the skin disease striate palmoplantar keratoderma. *Eur J Hum Genet* 2001; 9: 197–203.
12. Berget SM. Exon recognition in vertebrate splicing. *J Biol Chem* 1995; 270: 2411–2414.
13. [http://www.fruitfly.org/seq\\_tools/splice.html/](http://www.fruitfly.org/seq_tools/splice.html/)
14. Frischmeyer PA, Dietz HC. Nonsense-mediated mRNA decay in health and disease. *Hum Mol Genet* 1999; 8: 1893–1900.
15. South AP. Plakophilin 1: an important stabilizer of desmosomes. *Clin Exp Dermatol* 2004; 29: 161–167.
16. Hatzfeld M, Kristjansson GI, Plessmann U, Weber K. Band 6 protein, a major constituent of desmosomes from stratified epithelia, is a novel member of the armadillo multigene family. *J Cell Sci* 1994; 107: 2259–2270.
17. Peifer M, Berg S, Reynolds AB. A repeating amino acid motif shared by proteins with diverse cellular roles. *Cell* 1994; 76: 789–791.
18. Hatzfeld M, Haffner C, Schulze K, Vinzens U. The function of plakophilin 1 in desmosome assembly and actin filament organization. *J Cell Biol* 2000; 149: 209–222.
19. Mertens C, Kuhn C, Franke WW. Plakophilins 2a and 2b: constitutive proteins of dual location in the karyoplasm and the desmosomal plaque. *J Cell Biol* 1996; 135: 1009–1025.
20. Bonne S, van Hengel J, Nollet F, Kools P, van Roy F. Plakophilin-3, a novel armadillo-like protein present in nuclei and desmosomes of epithelial cells. *J Cell Sci* 1999; 112: 2265–2276.
21. Gerull B, Heuser A, Wichter T, Paul M, Basson CT, McDermott DA, et al. Mutations in the desmosomal protein plakophilin-2 are common in arrhythmogenic right ventricular cardiomyopathy. *Nat Genet* 2004; 36: 1162–1164.
22. Jacobson A, Peltz SW. Interrelationships of the pathways of mRNA decay and translation in eukaryotic cells. *Annu Rev Biochem* 1996; 65: 693–739.
23. Maquat LE. Defects in RNA splicing and the consequence of shortened translational reading frames. *Am J Hum Genet* 1996; 59: 279–286.