

## CLINICAL REPORT

**Fibroblastic Rheumatism: A Case Without Rheumatological Symptoms**LAURA COLONNA<sup>1</sup>, CLAUDIO BARBIERI<sup>1</sup>, GIOVANNI DI LELLA<sup>1</sup>, GIOVANNA ZAMBRUNO<sup>2</sup>, GIORGIO ANNESSI<sup>3</sup> and PIETRO PUDDU<sup>1</sup><sup>1</sup>Department of Immunodermatology, <sup>2</sup>Laboratory of Molecular and Cell Biology and <sup>3</sup>Histopathology Service, Istituto Dermopatico dell'Immacolata, IDI-IRCCS, Rome, Italy

**Fibroblastic rheumatism is a rare syndrome characterized by the association of multiple cutaneous nodules with symmetric polyarthritis. We report on a patient who presented a 4-year history of pink to skin-coloured nodular lesions symmetrically localized at para-articular sites without evident rheumatological symptoms. Histopathology of a skin nodule led to the diagnosis of fibroblastic rheumatism showing a poorly circumscribed dermal proliferation of spindle and stellate fibroblast-like cells embedded in thickened collagen bundles with a marked reduction of elastic fibres. X-rays of both hands and feet showed metacarpophalangeal, metatarsophalangeal and interphalangeal erosions, unexpected by patient history. This case of fibroblastic rheumatism appears unique in view of the absence of any clinical manifestation of polyarthritis at 7 years from appearance of skin lesions. Key words: absence of symmetrical polyarthritis; para-articular skin nodules.**

(Accepted February 18, 2002).

Acta Derm Venereol 2002; 82: 200–203.

Laura Colonna, Department of Immunodermatology, Istituto Dermopatico dell'Immacolata, IRCCS, Via dei Monti di Creta 104, IT-00167 Rome, Italy. E-mail: laura.colonna@tin.it

Fibroblastic rheumatism (FR) is a rare syndrome of unknown aetiology in which skin nodules are associated with symmetrical polyarthritis. The course of the disease is variable, with regression of skin lesions in some cases but with a possible occurrence of destructive arthropathy. We describe a case of FR characterized by typical skin nodules and with radiographic changes in the absence of evident rheumatological symptoms.

## CASE REPORT

A 19-year-old man was admitted in January 1999 with asymptomatic cutaneous nodular lesions on many para-articular sites. His clinical past revealed an acute tibial osteochondrosis in 1993, an episode of pericarditis in 1996 and another in 1997. There was no history of rheumatic fever. Skin nodules first appeared in 1995 on

the dorsal sides of the hands, extending to other parts of the body within approximately 3 months.

On physical examination, 15–20 pink to skin-coloured, solid, cutaneous nodules, 5–20 mm in diameter, were localized on various para-articular sites, including the elbows, the volar tenar aspect of the hands (Fig. 1), the dorsal surface of the hands, fingers and knees; a few solitary nodules were also observed on the nose and neck. Skin lesions were not firmly adhered to the subcutaneous tissue and were tender to the touch.

There were no noticeable joint effusions except for slightly swollen hands. The patient did not complain of any symptoms, but of minor discomfort when pressure was applied to metacarpophalangeal joints of the index fingers of both hands and minimal morning stiffness of the elbows. Active and passive motion of the shoulders, elbows, wrists, hands, hips, knees, ankles and feet was painless and not limited in range. Raynaud's phenomenon, sclerodactyly and calcinosis were absent.

Laboratory routine tests were normal. Rheumatoid factor, urine hydroxyproline level, anti-*Borrelia* antibodies, fluorescent antinuclear antibodies, anti-ds-DNA, anti-Scl-70, anti-RNP, anti-Ro, anti-Jo-1 were all negative. X-rays of both hands and feet showed metacarpophalangeal, proximal interphalangeal, distal interphalangeal and metatarsal-phalangeal well-defined subcortical erosions. Radiographs of the chest, elbows, wrists and knees showed no abnormalities. Nail fold capillary microscopy showed normal capillary density (10 cap/mm) without oedema and haemorrhages; there

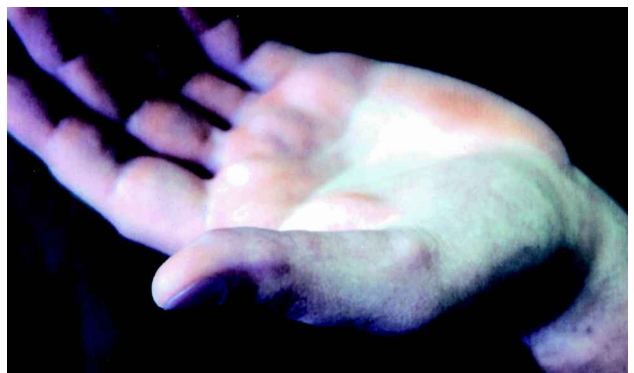

Fig. 1. A nodule on thenar surface of the left hand.

were some “bushy” and ectatic capillaries, but neither giant capillaries nor avascular zones were observed.

Histopathology of skin nodules led to the diagnosis of FR. Biopsy specimens from two lesions of the hands showed a poorly circumscribed nodule in the dermis composed of an increased number of spindle and stellate fibroblast-like cells with monomorphous nuclei and small nucleoli. The cells were embedded and regularly spaced within thickened collagen bundles disposed in haphazard array. The epidermis was unaffected and there were no inflammatory cells within the nodules (Fig. 2). Weigert stain displayed a marked reduction of the elastic fibres throughout the lesions. Immunohistochemical study revealed that the fibroblastic-like cells were positive for vimentin and XIIIa factor. Only few of these cells were stained with anti- $\alpha$ -smooth muscle actin and CD68 antibodies. Stains for desmin were negative. Direct immunofluorescence (DIF) demonstrated IgM and C3 granular deposits at the dermal-epidermal junction.

Ultrastructural examination of a hand nodule showed an increased number of dermal fibroblasts of various shapes with long cytoplasmic processes and a well-developed rough endoplasmic reticulum (Fig. 3A). Some of these cells had features of myofibroblasts, displaying pinocytotic vesicles, focal investment by basal lamina and small dense plaques along the cell membrane (Fig. 3B). Microfilament bundles but no myofilaments with dense bodies were seen within the cytoplasm of these myofibroblast-like cells. On cross-section, collagen fibres of varying diameter and occasional “collagen flowers” were detected (Fig. 3C). An increased amount of ground substance was present among collagen fibres and bundles. Elastic fibres were rare but of normal appearance.

The patient was treated with oral prednisone, 25 mg/day, and hydroxychloroquine, 200 mg/day, for 3 months without significant improvement. At present, with a 3-year follow-up from first admission in our department, patient conditions are unchanged, with no

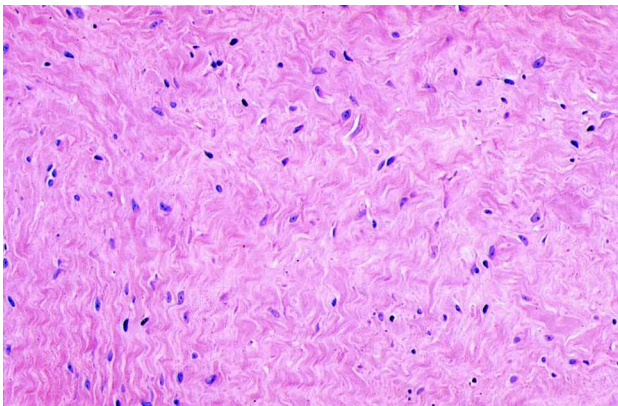


Fig. 2. Numerous fibroblast-like cells embedded in coarse collagen bundles (haematoxylin and eosin  $\times 200$ ).

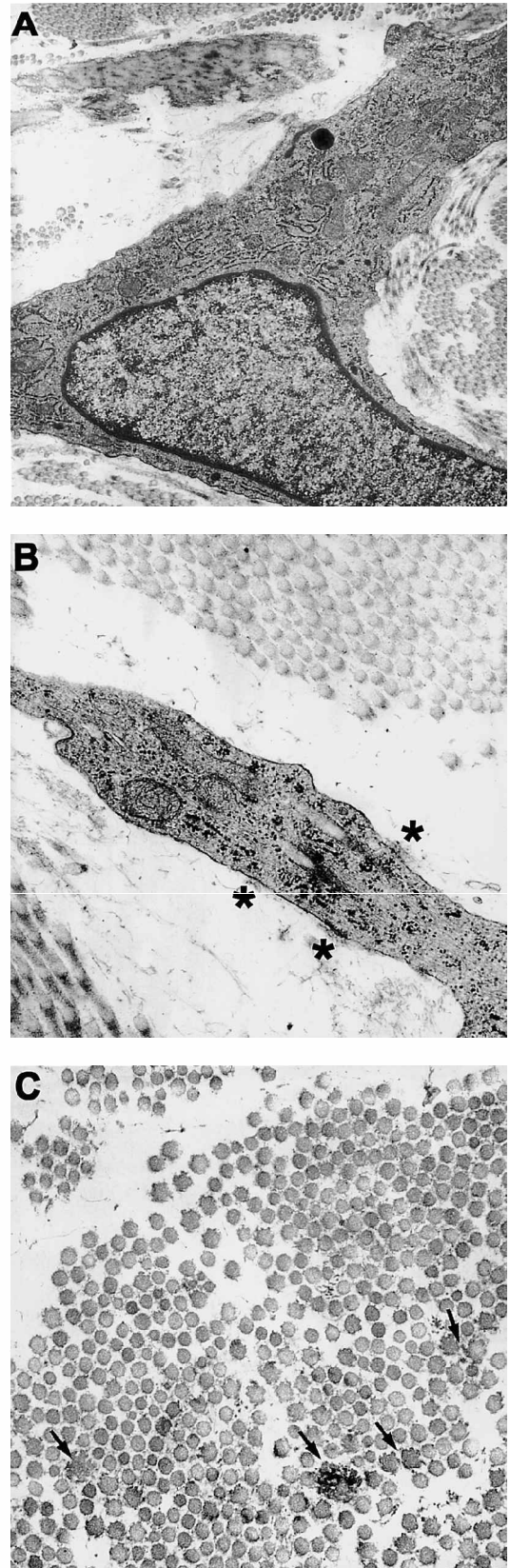


Fig. 3. Transmission electron microscopy of a skin biopsy. (A) A stellate fibroblast with prominent rough endoplasmic reticulum. (B) A cytoplasmic process of a myofibroblast-like cell showing microfilament bundles, interrupted basal lamina (\*) and small dense plaques along the plasma membrane. (C) A cross section of collagen fibres with several “collagen flowers” (arrows). (A  $\times 8,900$ ; B and C  $\times 21,000$ ).

reduction or development of skin lesions, and no joint symptoms.

## DISCUSSION

FR was first described by Chaouat et al. in 1980 (1). Nineteen patients, including this one, have been described hitherto, published in 16 different articles (1–16). Contrary to earlier reports (11, 13), there is no female to male preponderance (F:M = 9:10). It is a disease of young-middle age, rarely affecting children. The disorder is characterized by cutaneous nodules and joint involvement, with dermatological lesions appearing before (by 1 to 12 months) (6, 11, 12), simultaneously (9), or after (by days to 4 months) (1, 4) rheumatological manifestations. Onset is often sudden (7, 9, 11), with pain and swelling of symmetric joints variably associated with malaise and Raynaud's phenomenon, even though it can be more gradual (10, 12).

Dermatological symptoms include skin nodules, sclerodactyly, and thickening of the palmar face of the hands. Cutaneous nodules are the hallmark of the disease. These firm, pinkish coloured to erythematous lesions, 2 to 20 mm in diameter, are mostly seen on the dorsal aspects of the fingers in the para-articular areas, but can also be found elsewhere. Sclerodactyly (13/19) and palmar fibrosis (9/18) have frequently been observed.

Rheumatological manifestations consist of symmetrical polyarthralgia, morning stiffness, and joint edema. With progression of the disease, articular movements of the affected joints generally become markedly restricted and quite painful. Destructive polyarthropathy has been documented in three patients (6, 14, 15). In FR, joint radiographs show no initial stage destruction, but demineralization and erosive changes may appear later in the course of the disorder (1, 2, 12, 14). Raynaud's phenomenon has been observed in nearly half the cases (8/19). Patients may be febrile, but specific systemic manifestations are generally lacking. Laboratory tests are of no diagnostic value. Evolution is variable and improvement of cutaneous and articular symptoms possible with or without therapy. Partial (9–11, 13, 14) or complete (3, 7, 12) resolution of the skin nodules has been described, almost always (7, 9–11, 13, 14) following therapy, but efficacy of different treatments is far from proven also in view of the short follow-up reported (10, 11). Moreover, persistence of skin nodules despite therapy has been described, and permanent deformities are the rule in long-lasting studies (3, 10, 11, 14, 16).

Histology of the skin nodules is distinctive, showing fibrosis of the dermis and subcutaneous tissue with an increased number of dermal fibroblasts and thickened collagen bundles, occasionally arranged in a whorled pattern. Elastic fibres are usually diminished, and vessels and adnexae are surrounded but not destroyed by the fibrosis. There is little or no (9, 11) inflammatory cell

infiltrate; an increased cellularity of lymphocytes and macrophages in the papillary dermis has recently been reported in the initial stage of the disease (16).

At the ultrastructural level, the presence of myofibroblasts with distinctive myofilament bundles and dense bodies and/or myofibroblast-like cells has been described in the majority of the examined cases. In keeping with electron microscopic features, a variable percentage of  $\alpha$ -smooth-muscle-actin-positive cells is a frequent although not constant finding (14, 16). Non-specific additional ultrastructural findings include morphological alterations of collagen fibres, such as variability in diameter and "collagen flowers" images (16).

In our case, joint symptoms were present, with minimal rheumatological signs, and the patient was admitted for para-articular skin nodules and minor swelling of his hands that had been present since 1995; he did not spontaneously complain of any symptom. Mild elbow stiffness in the morning, without polyarthralgia, was revealed by the patient on history-taking, and the slight discomfort induced by pressure to the metacarpophalangeal joints of both index fingers was found on physical examination. However, there was no functional disability of the affected joints. Surprisingly, X-ray showed clear-cut, multiple hand and foot marginal erosions unexpected by patient history and physical examination. Light microscopy of a cutaneous biopsy specimen led us to the diagnosis of FR, showing a distinctive dermal nodule characterized by proliferation of fibroblast-like cells and collagen bundles. Electron microscopy evidenced an increased number of active fibroblastic cells, some of them showing features of myofibroblasts (10). Thus, diagnosis of FR was made by histologic examination, supported by electron microscopy findings and confirmed by joint radiographs.

There are no effective treatments for FR. Aspirin and other non-steroidal anti-inflammatory drugs, colchicine, d-penicillamine, prednisone,  $\alpha$ -interferon, methotrexate have been used with temporary and incomplete results. The patient seen by us was treated with oral prednisone for 3 months without any skin or joint improvement. Therapy was therefore stopped and the patient's condition is unchanged 3 years later.

A few disorders may exhibit para-articular cutaneous nodules similar to those observed in FR. In multicentric reticulohistiocytosis, skin lesions clinically resemble those of FR, and polyarthritides is common (17). However, mucosal involvement, affecting more than 50% of patients with multicentric reticulohistiocytosis (17), has never been observed in FR. Histology of multicentric reticulohistiocytosis provides the best clue for differential diagnosis showing lipid-laden histiocytes and multinucleated giant cells with ground-glass cytoplasm. The histological differential diagnosis includes progressive nodular fibrosis of the skin (18). In fact, the condition is characterized by a nodular proliferation of

plump fibroblasts in the dermis together with thickened collagen bundles. However, unlike FR, progressive nodular fibrosis of the skin does not involve para-articular sites and is not usually associated with joint radiological changes.

In the present case, despite the fact that rheumatological signs were not apparent, skin clinical examination, joint radiographs and the histological and ultrastructural findings were all consistent with those described by Chaouat et al. in 1980. To the best of our knowledge, this is the first case of FR without any clinical evidence of polyarthritis at 7 years from skin lesion development. Thus, although FR is usually characterized by evident clinical manifestations of rheumatic diseases, asymptomatic para-articular cutaneous nodules should nevertheless always lead to careful radiological and histological investigation.

#### ACKNOWLEDGEMENT

We thank A. Bucci for skilful technical assistance and A. Mari for artwork.

#### REFERENCES

1. Chaouat Y, Aron-Brunetiere R, Faures B, Binet O, Ginet C, Aubart D. Une nouvelle entité: le rhumatisme fibroblastique. *Rev Rhum Mal Osteoartic* 1980; 47: 345–351.
2. Crouzet J, Amouroux J, Duterque M, Halmagrand N, Beraneck L, Guillien P. Rhumatisme fibroblastique: un cas avec etude de l'histologie synoviale. *Rev Rhum Mal Osteoartic* 1982; 49: 469–472.
3. Schiavon F, Punzi L, Todesco S. Fibroblastic rheumatism: a fifteen-year follow-up study. *Arthritis Rheum* 1998; 41: 759–760.
4. Vignon Pennamen MD, Naveau B, Foldes C, Wallach D, Bonvalet D, Ryckewaert A, et al. Fibroblastic rheumatism. *J Am Acad Dermatol* 1986; 14: 1086–1088.
5. Taccari E, Teodori S, Zoppini A. Le rhumatisme fibroblastique du sujet agé. Données histopathologiques, ultrastructurales et problèmes de diagnostic différentiel. *Rev Rhum Mal Osteoartic* 1987; 54: 463–467.
6. Hernandez RJ, Headington JT, Kaufman RA, Martel W. Fibroblastic rheumatism. *Skeletal Radiol* 1989; 18: 43–45.
7. Levigne V, Perrot JL, Faisant M, Deville V, Claudy AL. Rhumatisme fibroblastique. *Ann Dermatol Venereol* 1990; 117: 199–202.
8. Barbaud A, Schmutz JL, Chemidling M, Beurey J, Weber M. Le rhumatisme fibroblastique. *Ann Dermatol Venereol* 1990; 117: 828–830.
9. Leclech C, Croue A, Masson C, Loison J, Verret JL. Rhumatisme fibroblastique. *Ann Dermatol Venereol* 1990; 117: 830–833.
10. Lacour JP, Maquart FX, Bellon G, Gillery P, Lepeyre P, Ziegler G, et al. Fibroblastic rheumatism: clinical, histological and biochemical study of a case. *Br J Dermatol* 1993; 128: 194–202.
11. Ostlere LS, Stevens HP, Jarmulowicz M, Higgins C, Black C, Rustin MHA. Fibroblastic rheumatism. *Clin Exp Dermatol* 1994; 19: 268–270.
12. Kanzler MH, Dhillon I, Headington JT. Fibroblastic rheumatism. *Arch Dermatol* 1995; 131: 710–712.
13. Vittecoq O, Mejjad O, da Silva F, Joly P, Thomine E, Lauret P, et al. Preliminary experience with low-dose methotrexate in fibroblastic rheumatism. *Arthritis Rheum* 1996; 39: 2070–2073.
14. Romas E, Finlay M, Woodruff T. The arthropathy of fibroblastic rheumatism. *Arthritis Rheum* 1997; 40: 183–187.
15. Masson C, De Bantd M, Perroux-Goumy L, Meyer O, Leclech C, Kahn MF, et al. Fibroblastic rheumatism: a review of 17 cases. *Arthritis Rheum* 1997; 40 Suppl: S101.
16. Fam AG, Hanna W, Mak V, Assaad D. Fibroblastic rheumatism: clinical and histologic evolution of cutaneous manifestations. *J Rheumatol* 1998; 25: 2261–2266.
17. Rapini RP. Multicentric reticulohistiocytosis. *Clin Dermatol* 1993; 11: 107–111.
18. Bauer EA, Uitto J, Santa Cruz D, Turner MLJ. Progressive modular fibrosis of the skin: altered procollagenase expression by cultured fibroblasts. *Invest Dermatol* 1986; 87: 210–216.