

CLINICAL REPORT

Herpes Simplex Virus Infection in a Hyper-IgE Patient: Appearance of Unusual Mass LesionsKLILAH HERSHKO¹, ALON Y. HERSHKO², VERA LEIBOVICI¹, KAREN MEIR³ and ARIEH INGBER¹Departments of ¹Dermatology, ²Internal Medicine A and ³Pathology, Hadassah University Hospital, Jerusalem, Israel

A 7-year-old girl presented with large soft masses rising from the nostril and from behind the ear. She had previously been diagnosed as suffering from hyper-IgE syndrome. The presence of herpes simplex virus infection within these lesions was confirmed by biopsy and immunohistochemical studies. The mass lesions did not respond to antibacterial therapy with cefazolin, but improved promptly under antiviral therapy with acyclovir. Immunological studies revealed a mild decrease in the CD4 cell population. Based on our results and on the relevant literature we propose an immunological mechanism for this unique manifestation of herpes simplex virus infection in hyper-IgE syndrome. *Key words:* CD4 deficiency; cutaneous nodules; hypereosinophilia; Job's syndrome.

(Accepted February 18, 2002.)

Acta Derm Venereol 2002; 82: 204–205.

Klilah Hershko, Department of Dermatology, Hadassah University Hospital, Jerusalem, Israel 91120. E-mail: alon_hershko@hotmail.com

The hyper-IgE syndrome was first described in 1966 by Davis et al. (1), who coined the term “Job’s syndrome”. Thus far, about 200 cases have been reported worldwide. Several organ systems are affected and the diagnosis is based on the presence of skin abscesses, pneumonia with the formation of pneumatocele, recurrent eczematoid rashes and elevation of serum IgE levels (2). The most significant feature of this syndrome is immune deficiency, and various immunological defects, both humoral and cellular, have been reported. In this report, we describe a patient with hyper-IgE syndrome and an unusual manifestation of herpes simplex virus (HSV) infection of the skin presenting as mass lesions. We propose that the patient’s CD4 lymphocyte deficiency may have accounted for the compromised response to the virus.

CASE REPORT

A 7-year-old girl was admitted to the Department of Dermatology with large (2–3 cm) soft masses rising from the left nostril and from behind the right ear (Fig. 1). Her history included severe eczema, recurrent pneumonia with pneumatocele, skin abscesses and high levels of IgE (peak 4000 IU) documented on repeat

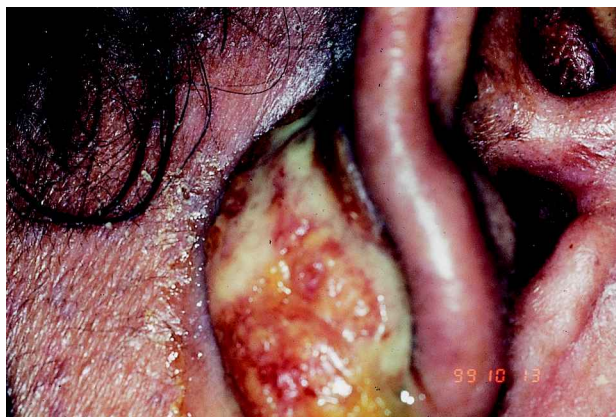

Fig. 1. A retroauricular soft cutaneous nodule with erythema and a yellowish discharge.

examinations, fulfilling all the criteria for the diagnosis of hyper-IgE syndrome. Other typical features present included hypereosinophilia (peak 35%) and opportunistic fungal pulmonary infections. T-lymphocyte levels were as follows – CD3: 585/μl (normal limits 600–1050), CD4: 315/μl (450–750), CD₈: 255/μl (225–375). Neutrophil chemotaxis was interpreted as normal. Testing for antibody to HIV was negative. The possibility of skin abscesses was ruled out by a computed tomography scan. Histologic examination showed viral inclusions within the epidermal cells (Fig. 2). The presence of HSV was then demonstrated by immunohistochemical staining (Fig. 3). HSV antibodies in the serum were IgG positive and IgM negative. The likelihood that the masses arose from an abnormal host response to

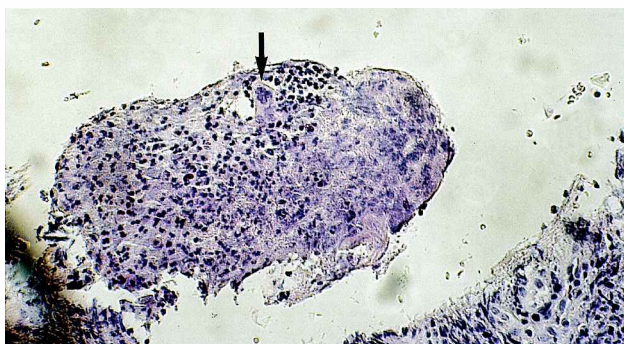


Fig. 2. Eroded epidermis from the mass lesion. The arrow indicates an inclusion body (hematoxylin and eosin, original magnification ×400).

HSV has been considered. This notion was supported by regression of the masses in response to antiviral therapy (acyclovir) following failure of antibacterial therapy (cefazolin).

DISCUSSION

Immune deficiency in patients with hyper-IgE syndrome may be attributed to several mechanisms, including defective granulocyte chemotaxis, defective antibody production, decreased production of, or responsiveness to, cytokines and abnormalities in T-lymphocyte function (2). These abnormalities render such patients susceptible to recurrent bacterial infections as well as to opportunistic infections. Moreover, in such cases, one can also observe bizarre responses to common infective agents such as staphylococcal botryomycosis (3) and candida endophthalmitis (4). To the best of our knowledge, this is the first description of unusual HSV-related mass lesions in a hyper-IgE syndrome patient. The traditional way to verify HSV infection is by viral culture. In our case, we have directly demonstrated the presence of HSV in the lesions by specific immunohistochemical staining, and confirmed its pathogenic role by prompt response to antiviral therapy. It is well established that CD4 cells play a major role in protecting against HSV infection (5). In this report, we describe a patient with decreased CD4 cell levels in whom response to HSV infection was compromised. Interestingly, a similar correlation between CD4 depletion and impaired host defense has been described in two AIDS patients who developed unusual HSV lesions (6). In one of these patients a mass lesion was noted in the external ear resembling the lesions described in our patient who was HIV-negative.

Several abnormalities in T-lymphocyte subgroups have been reported in hyper-IgE syndrome. Previous reports have described either deficiency of CD8 cells (7) or excess of CD4 cells (8). In both cases, it was proposed that these abnormalities account for uncontrolled production of IgE, but the authors did not emphasize the impact of their findings on immunological function. It should be stressed, however, that our study did not rule out the coexistence of other immunological defects which may have contributed to evolution of the unusual response to HSV observed.

In conclusion, we believe that T-lymphocyte studies should be considered in hyper-IgE patients. In the case of persistently decreased CD4, long-term or even prophylactic anti-viral therapy may be warranted.



Fig. 3. Skin biopsy demonstrating an epidermal erosion and numerous enlarged cells positively stained for HSV (shown by the arrow). (Herpes simplex virus type I immunoperoxidase and hematoxylin counterstain; original magnification $\times 175$).

Identification of an HSV mass lesion is a diagnostic challenge and its existence should be considered and distinguished from other possibilities, such as primary bacterial infection, to permit the administration of appropriate treatment and to avoid unnecessary and ineffective interventions, such as drainage or amputation (6).

REFERENCES

1. Davis SD, Schaller J, Wedgwood RJ. Job's syndrome: recurrent, "cold" staphylococcal abscesses. *Lancet* 1966; 1: 1013–1015.
2. Grimbacher B, Holland SM, Gallin JI, Greenberg F, Hill SC, Malech HL, et al. Hyper IgE syndrome with recurrent infection – an autosomal dominant multisystem disorder. *N Engl J Med* 1999; 340: 692–702.
3. Buescher ES, Herbert A, Rapini RP. Staphylococcal botryomycosis in a patient with the hyperimmunoglobulin E – recurrent infection syndrome. *Pediatr Infect Dis J* 1988; 7: 431–433.
4. Haslett RS, Moriarty AP, Vijayadurai P, McGalliard JN, Chandna A. Candida endophthalmitis in Job syndrome. *Arch Ophthalmol* 1996; 114: 617–618.
5. Leung KN, Nash AA, Sia DY, Wildy P. Clonal analysis of T-cell responses to herpes simplex virus: isolation, characterization and antiviral properties of an antigen-specific helper T-cell clone. *Immunology* 1984; 53: 623–628.
6. Weaver G, Kostman JR. Inoculation herpes simplex virus infections in patients with AIDS: unusual appearance and location of lesions. *Clin Infect Dis* 1996; 22: 141–142.
7. Geha RS, Reinherz E, Leung D, McKee KT. Deficiency of suppressor T cells in the hyperimmunoglobulin E syndrome. *J Clin Invest* 1981; 68: 783–791.
8. Presotto F, Trentin L, Agostini C. Hyper IgE syndrome (Letter). *N Engl J Med* 1999; 341: 375–376.