

LETTERS TO THE EDITOR

Methimazole-induced Antineutrophil Cytoplasmic Antibody (ANCA)-associated Vasculitis and Lupus-like Syndrome with a Cutaneous Feature of Vesiculo-bullous Systemic Lupus Erythematosus

Haw-Yueh Thong, Chia-Yu Chu and Hsien-Ching Chiu*

Department of Dermatology, National Taiwan University Hospital, 7 Chung-Shan South Road, Taipei, Taiwan.

E-mail: hcc@ha.mc.ntu.edu.tw

Accepted March 15, 2002.

Sir,

It has been reported that lupus erythematosus (LE)-like adverse reaction is induced by various drugs, e.g. procainamide, hydralazine, isoniazid and diphenylhydantoin (1, 2). Antithyroid agents can also induce this syndrome. Propylthiouracil has been reported to induce perinuclear antineutrophil cytoplasmic antibody (MPO-ANCA)-positive vasculitis (3, 4). Methimazole and carbimazole, two other antithyroid drugs classified with propylthiouracil as thionamides, can also cause ANCA-positive vasculitis, but much less frequently than propylthiouracil (4, 5). Other adverse effects related to methimazole include fever, rash, arthralgia, hepatitis, agranulocytosis and lupus-like syndrome (4, 6). However, only a few reports have described the skin symptoms and the histological findings in detail in antithyroid agent-induced lupus-like syndrome. We report on a patient with Graves' disease who, after being treated with methimazole for one week, developed a blistering eruption on the hands and legs. To our knowledge, this is the first report describing methimazole-induced lupus-like syndrome and ANCA-positive vasculitis with a cutaneous feature of vesiculo-bullous systemic lupus erythematosus (SLE).

CASE REPORT

An 18-year-old female with a 2-year history of hyperthyroidism, which was treated with a 6-month course of propylthiouracil and propranolol, had discontinued the medications for one year until the recurrence of hyperthyroidism presented as tremor, palpitation and heat intolerance. The patient did not have a history of systemic rheumatic disease or any previous complaint of photosensitivity and Raynaud phenomenon. The laboratory studies revealed the anti-thyroglobulin antibody (particle agglutination method, Fujirebio Co., Japan) level 1:25,600 (normal <1:80), anti-microsomal antibody (particle agglutination method) 1:10,240 (normal <1:80), free T4 0.53 ng/dl (normal 0.6–1.6), and TSH 0.27 μ U/ml (normal <6.5). She was then treated with methimazole 15 mg and propranolol 40 mg daily. A week later, hemoptysis, cough, dyspnea and an itchy skin rash were noted. The skin lesions consisted predominantly of vesicles 1–3 mm in size and crusted erosions on the legs and dorsa of the hands and feet (Fig. 1). The patient was admitted to our hospital where laboratory investigation showed a leukocyte count of $10.1 \times 10^9/l$ with

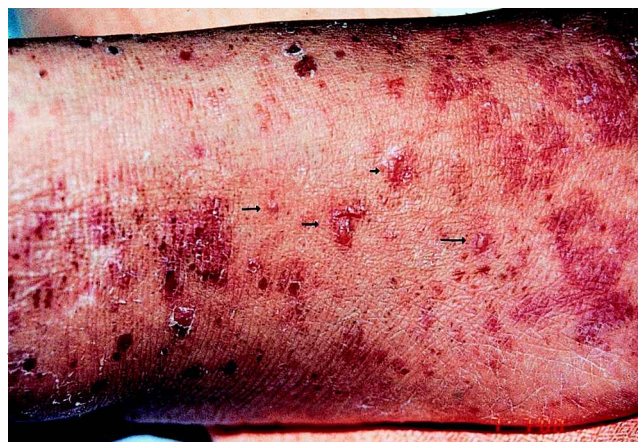

Fig. 1. Vesicles (arrows) and crusts are present on the lower leg.

62% segmental neutrophils and 1% eosinophils, a platelet count of $470 \times 10^9/l$, a hemoglobin level of 6 mg/dl, a reticulocyte count of 4.4%, a mean corpuscular volume of 87.6 fl, prothrombin time 9 s (control 10 s) and activated partial thromboplastin time 25 s (control 30 sec). Urinalysis was unremarkable. A chest X-ray film showed a bilateral, ground-glass appearance. Treatment with blood components and methylprednisolone was given. Owing to persistent respiratory insufficiency, the patient was intubated. A skin biopsy specimen from the lower leg revealed a neutrophilic infiltrate with nuclear dusts in the dermal papillae and tips of rete ridges, and vacuolar degeneration at the basement membrane zone with subepidermal blister formation (Fig. 2). Direct immunofluorescence study showed linear deposition of IgG and IgA at the basement membrane zone (Fig. 3). The indirect immunofluorescence study was negative. An open lung biopsy specimen revealed an intra-alveolar hemorrhage and capillaritis, as suggested by focally expanded and disrupted alveolar septa replaced by a neutrophilic infiltrate. Further investigation revealed PR3-ANCA (enzyme immunoassay, Pharmacia Diagnostics GmbH & C. KG, Freiburg, Germany) 4 EU/ml (normal <7), MPO-ANCA (enzyme immunoassay, Pharmacia Diagnostics) 62 EU/ml (normal <7), C3 35.7 mg/dl (normal 81.61–118.41) and C4 6.5 mg/dl (normal 27.45 ± 10.72). Antinuclear antibody of speckled type was found at a serum dilution of 1:80 by means of indirect immunofluorescence microscopy, using HEP-2 cells (Medical & Biological Laboratories Co., Japan (MBL)). Anti-ds DNA (enzyme immunoassay, MBL) 24.3 IU/ml (normal <12) was also noted. The anti-phospholipid antibody (enzyme immunoassay, Diagnostica Stago, France) level was 33.95 IU/ml (normal <5), but anti-cardiolipin antibody (enzyme immunoassay, Shield Diagnostics Ltd., UK) was negative. The anti-SS-A antibody (double radial immunodiffusion, MBL) was positive,

*Author for correspondence.

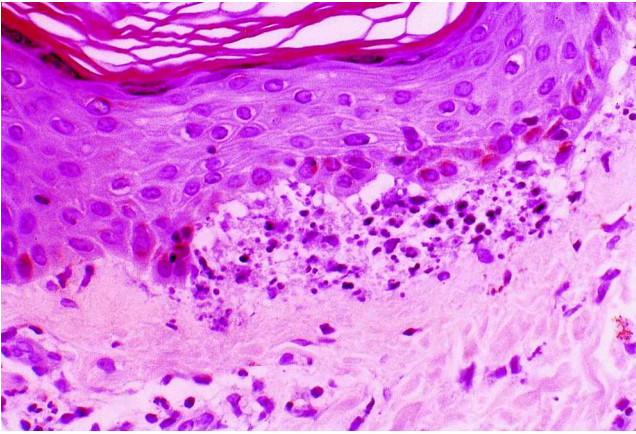


Fig. 2. A subepidermal blister with a neutrophilic infiltrate and nuclear dusts in the dermal papillae and the tips of rete ridges. (hematoxylin & eosin; original magnification $\times 400$)

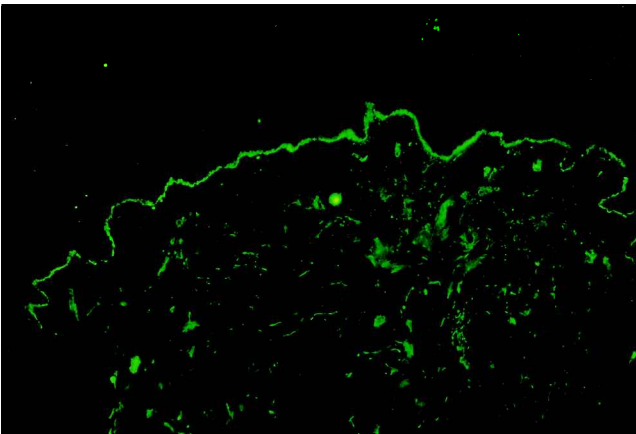


Fig. 3. Linear deposition of IgG at the dermal-epidermal junction. (original magnification $\times 40$)

while anti-SS-B, anti-Scl-70 and anti-Sm antibodies (double radial immunodiffusion, MBL) were negative. Generalized muscle weakness was also noted 2 weeks after admission. The creatine kinase level was < 20 U/l. Nerve conduction velocity and electromyography showed a myopathy and possible co-existing neuropathy. A sural nerve biopsy specimen showed lymphocytic vasculitis and moderate to severe degeneration of the nerve bundles. A muscle biopsy showed decreased ATPase staining and a mild degree and extent of muscle atrophy, especially the type II muscles, but without any evidence of vasculitis. Based on the clinical, histopathological and laboratory data, a diagnosis of methimazole-induced LE-like syndrome with a cutaneous feature of vesiculo-bullous SLE was made. Treatment with methimazole was discontinued and no new skin lesions were noted thereafter. Plasmapheresis and pulse therapy with methylprednisolone at 1 g daily for 3 days followed by 40 mg daily was given. The thyroid function became normal. She was extubated three weeks later. The skin lesions settled over a 4-week period. The serological data, including the titers of antinuclear antibody and anti-ds DNA antibodies, improved within 2 weeks and the C3 and C4 levels returned to normal within 2 months. The patient was subsequently treated with ^{131}I . Her thyroid function returned to normal and the muscle weakness improved.

DISCUSSION

Drug-induced LE-like syndrome may be clinically and serologically similar to idiopathic SLE (7, 8). Definitive criteria have not been established to distinguish idiopathic LE from drug-induced LE-like syndrome (7–9). Patients with drug-induced lupus often do not fulfill the criteria for SLE, and a diagnosis of drug-induced lupus can readily be missed if SLE diagnostic criteria are strictly applied (10). The development of a generalized vesiculo-bullous eruption in patients with SLE is uncommon. A generally accepted definition for vesiculo-bullous SLE does not exist. Medication-induced vesiculo-bullous SLE is rare and has been reported following the administration of penicillamine and hydralazine (11).

Despite a number of studies on LE-like syndrome induced by antithyroid agents, there are few detailed reports of cutaneous manifestations. A blistering eruption showing the histological and immunopathological features of vesiculo-bullous SLE has never been reported to be induced by anti-thyroid agents, including methimazole. The time course of the disease in our patient strongly suggests that methimazole was the cause. This antithyroid agent has been related previously to drug-induced pemphigus and drug-induced SLE. Wing & Fantus (10) reviewed 53 cases that developed adverse immunologic effects after receiving propylthiouracil and methimazole. In these patients, a number of different autoantibodies were found, but antinuclear antibodies were rare, and none of the cases met the criteria for a diagnosis of SLE. The clinical manifestations and laboratory data in our patient did not fulfill the criteria for a diagnosis of SLE. Nevertheless, the appearance of LE-like symptoms (pleuropulmonary manifestations, anemia, rashes, neuromuscular manifestations) and abnormal laboratory findings (weakly positive ANA, positive anti-ds DNA, decreased C3 and C4 levels) following the intake of methimazole and the resolution of the symptoms following its withdrawal highly suggested a drug-induced lupus. Moreover, the histological and immunopathological features of the skin lesions were compatible with those of vesiculo-bullous SLE.

Another uncommon feature in this patient was the involvement of the lung presented as serious respiratory insufficiency caused by capillaritis and intra-alveolar hemorrhage. Based on the positive MPO-ANCA and the extensive pulmonary capillaritis, a diagnosis of ANCA-associated vasculitis was also established. Methimazole-induced ANCA-associated vasculitis has been reported elsewhere (4). However, antithyroid agent-induced vasculitis associated with respiratory failure is a rare phenomenon (12). On the other hand, because myeloperoxidase and thyroid peroxidase molecules have been reported to contain possible cross-reactive epitopes (13, 14), and a high titer of antithyroid microsomal antibody was present in the serum of our patient, the possibility that our patient had

anti-thyroperoxidase antibody in addition to, or, less likely, instead of MPO-ANCA cannot be excluded.

Vesiculo-bullous SLE has been reported to respond to dapsone (15). However, in our patient, an early aggressive treatment with steroid pulse therapy and plasmapheresis was mandatory because of her life-threatening clinical condition. The contributory factors, such as an environmental trigger or an immunological factor, for the presence of a serious illness in this patient remain to be elucidated. The mechanism by which methimazole induces SLE-like reactions is unclear.

REFERENCES

1. Alarcon-Segovia D. Drug induced lupus syndromes. *Mayo Clin Proc* 1969; 44: 664–681.2.
2. Cush JJ, Goldings EA. Drug induced lupus: clinical spectrum and pathogenesis. *Am J Med Sci* 1985; 290: 36–45.
3. Kitahara T, Hiromura K, Maezawa A, Ono K, Narahara N, Yano S, et al. Case of propylthiouracil-induced vasculitis associated with anti-neutrophil cytoplasmic antibody (ANCA); review of the literature. *Clin Nephrology* 1997; 47: 336–340.
4. Kawachi Y, Nukaga H, Hoshino M, Iwata M, Otsuka F. ANCA-associated vasculitis and lupus-like syndrome caused by methimazole. *Clin Exp Dermatol* 1995; 20: 345–347.
5. Hori Y, Arizono K, Hara S, Kawai R, Hara M, Yamada A. Antineutrophil cytoplasmic autoantibody-positive crescentic glomerulonephritis associated with thiamazole therapy. *Nephron* 1996; 74: 734–735.
6. Cooper D. Antithyroid drugs. *N Engl J Med* 1984; 311: 1353–1362.
7. Yung RL, Richardson BC. Drug-induced lupus. *Rheum Dis Clin North Am* 1994; 20: 61–86.
8. Hess E. Drug-related lupus. *N Engl J Med* 1988; 318: 1460–1462.
9. Sato-Matsumura KC, Koizumi H, Matsumura T, Takahashi T, Adachi K, Ohkawara A. Lupus erythematosus-like syndrome induced by thiamazole and propylthiouracil. *J Dermatol* 1994; 21: 501–507.
10. Wing SS, Fantus IG. Adverse immunologic effects of antithyroid drugs. *Can Med Assoc J* 1987; 136: 121–127.
11. Condon C, Phelan M, Lyons JF. Penicillamine-induced type II bullous systemic lupus erythematosus. *Br J Dermatol* 1997; 136: 474–475.
12. Stankus S, Johnson N. Propylthiouracil-induced hypersensitivity vasculitis presenting as respiratory failure. *Chest* 1992; 102: 1595–1596.
13. Haapala AM, Hyoty H, Parkkonen P, Mustonen J, Soppi E. Antibody reactivity against thyroid peroxidase and myeloperoxidase in autoimmune thyroiditis and systemic vasculitis. *Scand J Immunol* 1997; 46: 78–85.
14. Farsi A, Turchini S, Azzurri A, Domeneghetti MP, Passaleva A. Some anti-thyroperoxidase antibodies positive sera give a pANCA pattern on ethanol-fixed human neutrophils: cross-reactivity or false positives? *Autoimmunity* 1997; 25: 117–122.
15. Yung A, Oakley A. Bullous systemic lupus erythematosus. *Aus J Dermatol* 2000; 41: 234–237.

Angiokeratoma of the Scrotum (Fordyce Type) Associated with Angiokeratoma of the Oral Cavity

Thomas Jansen, Falk Georges Bechara, Markus Stücker and Peter Altmeyer

Department of Dermatology and Allergology, Ruhr-University Bochum, Gudrunstrasse 56, DE-44791 Bochum, Germany

Accepted February 23, 2002.

Sir,

Angiokeratoma is a rare cutaneous vascular disorder of the papillary dermis characterized by vascular ectasia associated with overlying hyperkeratosis. Five types of angiokeratoma are generally recognized: (i) the usually solitary papular angiokeratoma, (ii) the bilateral angiokeratoma that occurs on the dorsa of the fingers and toes (Mibelli type), (iii) the localized angiokeratoma of the scrotum or vulva (Fordyce type), (iv) the congenital form, angiokeratoma circumscriptum (naeviforme), and (v) the generalized systemic form, angiokeratoma corporis diffusum (Fabry's disease, fucosidosis). The types differ from each other by location and clinical manifestation, but share similar histopathological features (1). Some patients may have lesions of more than one of these types. We report on a patient with

angiokeratoma of the scrotum (Fordyce type) associated with angiokeratoma of the oral cavity.

CASE REPORT

A 72-year-old Caucasian man presented with papules on the scrotum and tongue. The lesions had been present for the past two years. He had no other complaints, and, in particular, there had been no bleeding from the lesions. He had no preceding history of local trauma and his medical history was unremarkable. No other members of the family presented this condition.

Physical examination revealed multiple discrete, red or purple, well-defined, dome-shaped papules, some with keratotic overlying skin, varying in size from 2 to 3 mm, scattered over the scrotum (Fig. 1). Similar lesions could