

LETTERS TO THE EDITOR

Serum Concentrations of Vascular Endothelial Growth Factor in Angiosarcomas With and Without *p53* Gene Mutation

Yasuyuki Amo, Mikio Masuzawa, Yuhko Hamada and Kensei Katsuoka

Department of Dermatology, Kitasato University School of Medicine, 1-15-1 Kitasato, Sagami-hara, Kanagawa 228-8555, Japan.

E-mail: amo@med.kitasato-u.ac.jp

Accepted May 8, 2002.

Sir,

Vascular endothelial growth factor (VEGF), a specific mitogen of endothelial cells *in vitro*, is also known to induce angiogenesis *in vivo*. Previous studies have shown that the proliferating cells in vascular tumors, such as angiosarcoma and Kaposi's sarcoma associated with AIDS, express VEGF mRNA, suggesting that neovascularization supported by VEGF expression in tumor cells is essential for the development and invasion of neoplasia (1–2). VEGF expression is known to be induced through the protein kinase C (PKC) pathway. *p53* gene mutation potentiates PKC induction for VEGF expression. *p53* gene point mutations have been found in the majority of angiosarcomas (3), and a newly typed *p53* gene point mutation has been found in the angiosarcoma cell line ISO-HAS (4). We suggest that these mutations may play an important role in the pathogenesis of angiosarcomas with increased VEGF expression (5, 6). Therefore, the malignant transformation of endothelial cells may be characterized by VEGF expression in the presence of *p53* gene mutation. The present study was designed to clarify the association between *p53* inactivation and VEGF secretion in cases of angiosarcoma.

PATIENTS AND METHODS

We investigated 11 elderly patients (7 males and 4 females; mean age, 75.3 years; range 67–84 years) with definite angiosarcoma of the face and scalp. The serum level of VEGF was measured using a human VEGF Quantikine kit (R&D Systems, Minneapolis, MN) according to the manufacturer's protocol. Normal control sera samples were obtained from 18 healthy volunteers (10 males and 8 females; mean age, 70.3 years; range, 62–81 years). Previous studies including outlying exons have indicated that mutations outside exons 5 to 8 are rare (7); we have also studied DNA sequencing to detect *p53* gene mutations in exons 5 to 8 in these angiosarcomas (4). Point mutation, an AGT→AGA transversion in codon 240 in exon 7, was detected in one case, resulting in a Ser→Arg substitution (4). However, the other angiosarcomas did not contain any point mutations in the *p53* gene in exons 5 to 8.

RESULTS AND DISCUSSION

The concentration of VEGF in healthy subjects (mean \pm SD) was 87 ± 57 pg ml⁻¹, range 13–206. Values > 2 SD above the mean control value (201 pg ml⁻¹) were considered as elevated. In one patient (case 1),

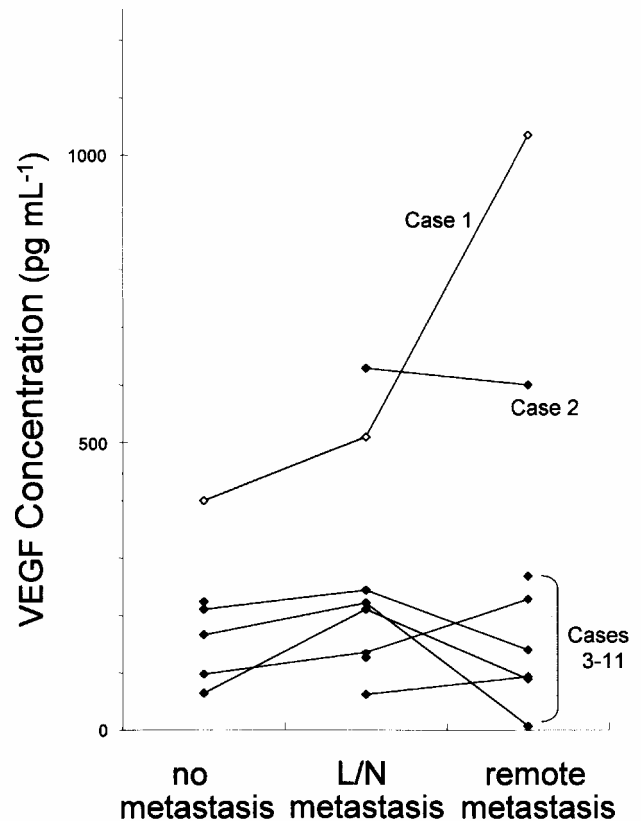


Fig. 1. Serum vascular endothelial growth factor (VEGF) levels in an angiosarcoma patient (case 1) who had a *p53* gene point mutation were significantly higher than those in normal controls (≤ 210 pg ml⁻¹) and the values were related to the tumor progression. In a patient (case 2) in whom a *p53* gene point mutation was not detected the values were significantly higher than those in normal controls; however, no correlation with the tumor expansion was seen. No statistical differences were found in serum VEGF levels between the other angiosarcoma patients (cases 3–11) in whom the *p53* gene point mutation was not detected. L/N: lymph node.

with a detectable *p53* gene point mutation, the VEGF levels were significantly higher than those observed in the normal controls at the respective time points in parallel with tumor expansion (Fig. 1) (5). On the other hand, serum VEGF levels in only one of 10 angiosarcoma patients in whom the *p53* gene point mutation was not detected were significantly higher than those in the normal controls at the respective time points, but no correlation with tumor expansion was seen (case 2).

No statistical differences were found in serum VEGF levels between the other angiosarcoma patients (cases 3–11) in whom the *p53* gene point mutation was not detected; these patients include those without metastasis ($153 \pm 70 \text{ pg ml}^{-1}$, range 65–223, $n=4$), those with metastasis to parotid lymph nodes ($166 \pm 70 \text{ pg ml}^{-1}$, range 62–244, $n=6$), and those with remote metastasis ($119 \pm 101 \text{ pg ml}^{-1}$, range 7–269, $n=7$) (Fig. 1).

Because of serious heart failure, the patient who had detectable *p53* gene point mutation (case 1) was treated with local radiation therapy alone. The other patients were treated with surgery, radiation therapy, local or systemic administration of recombinant interleukin-2 (IL-2), and immunotherapy using IL-2 and IL-2-activated lymphocytes. The effect of these treatments may have contributed to the serum VEGF levels. Therefore, serum VEGF levels may not be correlated with clinical course in most cases of angiosarcomas without *p53* gene mutation.

REFERENCES

1. Hashimoto M, Ohsawa M, Ohnishi A, Naka N, Hirota S, Kitamura Y, et al. Expression of vascular endothelial growth factor and its receptor mRNA in angiosarcoma. *Lab Invest* 1995; 73: 859–863.
2. Masood R, Cai J, Zheng T, Smith L, Naidu Y, Gill PS. Vascular endothelial growth factor/vascular permeability factor is an autocrine growth factor for AIDS-associated Kaposi's sarcoma. *Proc Natl Acad Sci USA* 1997; 94: 979–984.
3. Naka N, Tomita Y, Nakanishi H, Araki N, Hongyo T, Ochi T, et al. Mutation of p53 tumor-suppressor gene in angiosarcoma. *Int J Cancer* 1997; 71: 952–955.
4. Masuzawa M, Fujimura T, Hamada Y, Fujita Y, Hara H, Nishiyama S, et al. Establishment of a human hemangiosarcoma cell line (ISO-HAS). *Int J Cancer* 1999; 81: 305–308.
5. Amo Y, Masuzawa M, Hamada Y, Takasu H, Fujimura T, Katsuoka K, et al. Serum levels of vascular endothelial growth factor in a hemangiosarcoma patient with a new-typed *p53* gene point mutation. *Br J Dermatol* 2000; 143: 1118–1119.
6. Amo Y, Masuzawa M, Hamada Y, Katsuoka K. Expression of vascular endothelial growth factor in a human hemangiosarcoma cell line (ISO-HAS). *Arch Dermatol Res* 2001; 293: 296–301.
7. Hollstein M, Sidransky D, Vogelstein B, Harris SR. p53 mutations in human cancers. *Science* 1991; 253: 49–53.

1. Hashimoto M, Ohsawa M, Ohnishi A, Naka N, Hirota S, Kitamura Y, et al. Expression of vascular endothelial

Generalized Pustulosis and Severe Tubulointerstitial Nephropathy as Manifestations of Carbamazepine Hypersensitivity Syndrome

David Moreno-Ramírez¹, Begona García-Bravo¹, Antonio Rodríguez-Pichardo¹, Clotilde Ríos Camacho² and Francisco Camacho Martínez¹

Departments of ¹Dermatology and ²Nephrology, University Hospital "Virgen Macarena", Seville, Spain.

E-mail: camachodp@medynet.com

Accepted 3 June, 2002.

Sir,

Anticonvulsant hypersensitivity syndrome (AHS) is a multisystemic disorder with cutaneous changes and typical blood abnormalities that may be triggered by any of the aromatic antiepileptic drugs (1, 2). We present the case of a patient who, following carbamazepine treatment, developed AHS with major cutaneous and systemic manifestations that are not common in the context of this syndrome.

CASE REPORT

A 26-year-old woman was referred to our department for evaluation of a 10-day history of malaise, fever of up to 40°C and a generalized exanthem. The patient had been on carbamazepine therapy (400 mg daily) for 1 month because of temporal epileptic seizures. She reported no previous history of drug allergies.

Examination revealed a red-violet exanthem involving the trunk, extremities, palms and soles; the face was

severely affected, accompanied by mild oedema. A large number of pinhead-sized pustules were observed on her face and upper back with an intensely erythematous skin (Fig. 1). A biopsy taken from these pustular lesions revealed follicular and non-follicular intraepidermic spongiform pustules, with a perivascular infiltration of lymph cells and eosinophils in the upper dermis. Vasculitis was absent. These histological changes were consistent with an acute generalized exanthematous pustulosis.

Systemic examination revealed a deteriorated overall condition of the patient, fever, hepatomegaly and swollen bilateral inguinal lymph nodes. The first laboratory tests disclosed eosinophilia (13.5%) and elevated liver function tests: aspartate aminotransferase 63 U/l (0–37 U/l), alanine aminotransferase 262 U/l (0–40 U/l) and gamma glutamyltranspeptidase 335 U/l (11–49 U/l).

In view of the clinical and histological changes, we considered the case to be related to carbamazepine, so