

LETTERS TO THE EDITOR

A Case of Chondrodermatitis Nodularis Chronica Helicis with an Autoantibody to Denatured Type II Collagen

Sir,

Chondrodermatitis nodularis chronica helicis (CNCH) was first described by Winkler in 1915. It is characterized as a distinct clinicopathologic entity which typically presents as a painful, whitish-yellowish to red papule with a keratotic crust on the helix of the ears of middle-aged men. Upon removal of the crust, a central crater or ulcer can be seen. Histologically, there is necrotic debris enveloped by pseudoepitheliomatous hyperplastic epidermis. There is now general agreement that CNCH is a disorder of transepidermal elimination in which damaged dermal connective tissue is engulfed and eliminated by a hyperplastic epidermis (1, 2). The etiology of CNCH is uncertain and there are various theories: cartilaginous change is the origin of the disease (1, 2); hyperkeratosis is the primary event leading to the perforation (3); cold or insufficient circulation is responsible for production of the lesion (4); or traumatically injured collagen is the causative agent (5).

The major connective tissue component of ear cartilage is type II collagen. The damage to ear cartilage is also seen in relapsing polychondritis, in which an antibody for a native type II collagen is detected and is considered to be a causative factor (6).

The most significant diagnostic change of CNCH is considered to be inflammation of the perichondrium in conjunction with degeneration of the subjacent ear cartilage (1, 2). To study the role of cartilage damage in the pathophysiology of CNCH, we measured autoantibody for type II collagen in patient serum. Using anti-type II collagen antibody we immunohistochemically confirmed cartilage damage and found autoantibody to denatured type II collagen in patient serum by ELISA.

CASE REPORT

An 86-year-old Japanese woman presented with a painful ulcer on the left ear which she had had for 1 year. The lesion consisted of a well-defined erythematous nodule and a central 3-mm diameter ulcer on the antihelical area. According to the patient, the ulcer had been intermittently covered by a crust. The ears appeared otherwise normal. She has hypertension and chronic gastritis but no diabetes mellitus or renal disease. Routine laboratory examinations, including hemogram, liver function, electrolytes and urinalysis, showed no remarkable abnormality. Rheumatoid factor was negative.

Histopathologic study was performed after surgical resection of the lesion. The base of the ulcer was composed of necrotic or granulation tissues in the dermis, with a marked polymorphonuclear leucocyte infiltration. There was reactive acanthosis of the epidermis surrounding the ulcer. In the central portion of the cartilage, chondroid matrix had undergone degeneration, resulting in the replacement by fibrous materials or degenerative vacuoles. The degenerative changes were not confined to the cartilage zone directly beneath the ulcer, but appeared focally throughout the entire sample auricular cartilage (not shown). In the skin adjacent to the lesion there was a marked increase in elastic fibers in the papillary dermis, but there was no clumping of elastic staining materials. Paraffin-embedded section was immunoreacted with monoclonal anti-human type II collagen antibody (Fuji Pharmaceutical, Toyama, Japan) at 1:20 dilution for 24 h, then incubated with anti-mouse Ig antibody at 1:100 dilution for 2 h. Antigen-antibody complex was visualized by avidin-biotin complex.

Immunohistochemical examination revealed the destruction of cartilage, which was relapsed by homogeneous material (not shown).

Type I collagen was purchased from the Cosmo Bio Co. (Tokyo, Japan) and was prepared from human skin. Type II collagen, purchased from the Calbiochem-Novabiochem Co., was prepared from human auricular cartilage with pepsin treatment followed by salt precipitation. Purity of the collagens was determined by 2–15% gradient slab gel. In some experiments, type II collagen was heat denatured at 100°C for 2 min prior to the assay. Patient sera were obtained at two different periods, before and after surgical resection (time interval 3 months). They were obtained from 7 healthy controls (age/sex; 65/f, 67/f, 59/f, 64/f, 63/f, 69/f, 75/f; mean age 66). Sera from the two patients with relapsing polychondritis were used for positive controls. Sera were diluted at 1:10 and added to the plates. The polystyrene ELISA plates (Serocluster U plates, Costar, Cambridge, MA, USA) were coated with 100 µl of type I or II collagen (5 µg/ml) in solution (0.05M Tris-HCl, pH 7.6, 0.15M NaCl, 0.02% Na₂S₂O₄) at 4°C overnight. To prevent a non-specific reaction, PBS/0.05% Tween/0.01%BSA (PTB) solution was used for washing or dilution buffer. After washing with PTB solution, the plates were incubated with peroxidase-conjugated anti-human Ig (E-Y Laboratories, San Mateo, CA, USA) diluted 1:10000 for 1 h. O-Phenylendiamine was used as a substrate and the color reaction was stopped by adding 2M H₂SO₄. The optical density was examined with a microtiter plate spectrophotometer (Tosoh Microplate Reader, MPRA4, Tokyo) at 492 nm (7).

ELISA demonstrated that the titer of the patient serum against type II collagen was within the range of those of normal sera ($n = 10$). Authentic sera from relapsing polychondritis ($n = 2$) were confirmed to react with native type II collagen (Fig. 1a). In contrast, the titer of patient serum against denatured type II collagen was significantly higher than the range of normal sera (Fig. 1b). No immunoreactivity with type I collagen was seen in the patient and normal controls (not shown). Since it has been demonstrated that fibronectin mediates the binding of IgG to denatured type II collagen in some patients with rheumatoid arthritis (8), patient serum at 1:10 dilution was added to increasing amounts of human plasma fibronectin (0, 0.1,

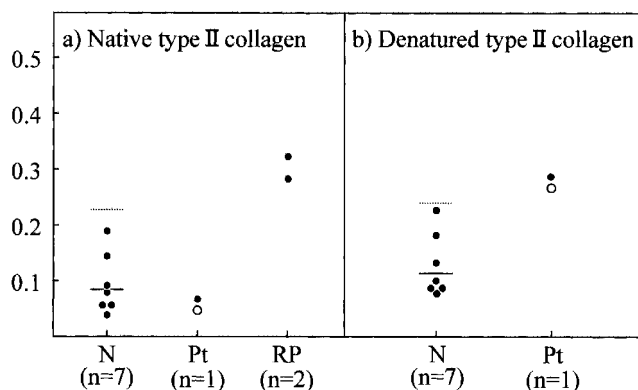


Fig. 1. Determination of autoantibody to type II collagen in patient serum by ELISA. Sera from the patient (Pt) and healthy volunteers (N) ($n = 7$) were diluted 1:10, then processed to ELISA using native (a) or denatured (b) type II collagen as a substrate. In patient serum ELISA titers before (closed circle) and after (open circle) the resection of the lesion were shown. In normal sera the solid bars indicate the means and the dotted lines indicate the value for means + 3 SD. For reference, the titers of the sera from the patients with relapsing polychondritis (RP) ($n = 2$) against native type II collagen were indicated in (a).

0.5, 1, 5 and 10 μg /assay) and binding of patient serum IgG to denatured type II collagen was measured by ELISA. There was no competitive inhibition of ELISA titer in patient serum against denatured type II collagen (ELISA titer: 0.30, 0.35, 0.38, 0.35, 0.37 and 0.34 at 0, 0.1, 0.5, 1, 5 and 10 μg of fibronectin added in the assay, respectively), indicating that IgG-fibronectin binding is not involved in the high titer of anti-denatured type II collagen antibody at least in this case.

DISCUSSION

CNCH is considered to be included in the category of perforating dermatosis, which is characterized by transepidermal elimination of dermal components. There are four other perforating disorders that show distinct eliminating materials. Elastosis perforans serpiginosa eliminates altered elastic fibers, reactive perforating collagenosis and perforating folliculitis eliminate degenerated collagen fibers, whereas Kyrle's disease does not contain elastic and collagen fibers in the eliminating materials (9). In most cases of CNCH, necrotic dermal tissues (mainly collagen) appeared to be eliminated through epidermis. However, it has been reported that the cartilage was protruding through the area of ulceration in some cases of CNCH (1, 2). It has been demonstrated that 67-kDa-elastin receptor is strongly expressed in the epidermis of elastosis perforans serpiginosa during the transepidermal elimination of dermal elastic materials (10). The question whether the eliminating material in CNCH is dermal matrix collagen, elastin or cartilage (type II collagen) is unclear. To address this question, we immunohistochemically examined the lesional skin using the antibody for 67 kDa elastin receptor, but failed to detect the significant immunoreactivity in the epidermis of this case (not shown).

Of particular interest is the detection of antibodies to denatured type II collagen, but not to native type II collagen in the serum of the patient. How can these antibodies to the collagen play a role in the pathogenesis of CNCH? Autoantibodies to native type II collagen have been detected in patients with relapsing polycondritis and are considered to be a causative factor (6). Antibodies to denatured type II collagen have also been detected in rheumatoid arthritis (7, 8, 11). However, the antibody may not be involved in the initiating event in this disease and CNCH. Once cartilage degeneration begins, leakage of denatured type II collagen could induce an immunological stimulus leading to production of the antibody. The association of CNCH with several autoimmune disorders, systemic scleroderma (12) or dermatomyositis (13) suggests that anti-type II collagen antibody may play a role in such cases of CNCH. The degree of cartilage damage in this disease varies from a minimal to a marked degeneration. The patient in the present study showed a marked degenerative change of the cartilage, which may be responsible for induction of anti-type II collagen antibody

that persisted after removal of the lesion. Any firm conclusion regarding the pathogenic role of the collagen II autoantibodies in CNCH must, however, await the results of a larger study of patients with CNCH.

REFERENCES

1. Santa Cruz DJ. Chondrodermatitis nodularis helioides: a transepidermal perforating disorder. *J Cutan Pathol* 1980; 7: 70–76.
2. Bard JW. Chondrodermatitis nodularis chronica helioides. *Dermatologica* 1981; 163: 376–384.
3. Carol EL, Van Haren HB. Über Clavus helioides, BZW. Chondrodermatitis nodularis chronica helioides. *Dermatologica* 1941; 83: 353–374.
4. Halter K. Zur Pathogenese der Chondrodermatitis nodularis chronica helioides. *Dermatologische Zeitschrift* 1936; 73: 270–284.
5. Delacretaz J, Gattren JM. Transepidermal elimination of traumatic altered collagen. *Dermatologica* 1976; 152: 65–71.
6. Foidart JM, Abe S, Martin GR, Zizix RM, Barnett EV, Lamley TJ, *et al.* Antibodies to type II collagen in relapsing polycondritis. *N Engl J Med* 1978; 299: 1203–1207.
7. Terao K, Shimozuru Y, Katayama K, Takemitsu Y, Yamashita I, Miyatsu M, *et al.* Specificity of antibodies to type II collagen in rheumatoid arthritis. *Arthritis Rheum* 1990; 33: 1943–1500.
8. Mannik M, Kapil S, Merrill CE. In patients with rheumatoid arthritis IgG binding to denatured type II collagen is in part mediated by IgG-fibronectin complexes. *J Immunol* 1997; 158: 1446–1452.
9. Sehgal VN, Jain S, Thappa DM, Bhattacharya SN, Logani K. Perforating dermatosis: a review and report of four cases. *J Dermatol (Tokyo)* 1993; 20: 329–340.
10. Fujimoto N, Tajima S, Ishibashi A. Elastin peptides induce migration and terminal differentiation of cultured keratinocytes via 67kDa elastin receptor *in vitro*: 67kDa elastin receptor is expressed in the keratinocytes eliminating elastic materials in elastosis perforans serpiginosa. *J Invest Dermatol* 2000; 115: 633–639.
11. Rowley M, Tait B, Mackay IR, Cunningham T, Phillips B. Collagen antibodies in rheumatoid arthritis. Significance of antibodies to denatured collagen and their association with HLA-DR4. *Arthritis Rheum* 1986; 29: 174–184.
12. Bottomley WW, Goodfield MDJ. Chondrodermatitis nodularis helioides occurring with systemic sclerosis – an under-reported association? *Clin Exp Dermatol* 1994; 19: 219–220.
13. Sasaki T, Nishikawa H, Sugita Y. Chondrodermatitis nodularis helioides in childhood dermatomyositis. *Br J Dermatol* 1999; 141: 363–365.

Accepted February 27, 2001.

Eiji Yoshinaga, Utayo Enomoto, Norihiro Fujimoto, Yoshihiro Ohnishi, Shingo Tajima* and Akira Ishibashi
Department of Dermatology, National Defense Medical College,
3-2 Namiki, Tokorozawa Saitama 359-8513, Japan.

*E-mail: tajimas@ndmc.ac.jp