

REVIEW ARTICLE

Angiotensin-converting Enzyme Inhibitors as Inducers of Adverse Cutaneous Reactions

U. M. STECKELINGS, M. ARTUC, T. WOLLSCHLÄGER, S. WIEHSTUTZ and B. M. HENZ

Department of Dermatology and Allergy, Charité, Humboldt University, Berlin, Germany

Since adverse effects due to angiotensin-converting enzyme (ACE) inhibitors frequently occur in cutaneous locations, this review summarizes the spectrum of expected and unexpected adverse effects of these drugs, possible associated mechanisms, and their basic functions for dermatologists. ACE inhibitors block the activity of the metalloproteinase ACE by binding to its active site, thus displacing angiotensin I and preventing its conversion to vasopressive angiotensin II. Furthermore, ACE degrades bradykinin, substance P, enkephalins and some of the reproductive peptide hormones. The overall incidence of adverse effects to ACE inhibitors is estimated at 28%, approximately half of which occurs in the skin. General reactions are first-dose hypotension, hyperkalaemia and renal failure. Cutaneous reactions comprise life-threatening angioedema, pruritus, bullous eruptions, urticaria, other generalized rashes, photosensitivity and hair loss. ACE inhibitors thus mimic a broad variety of skin diseases, why these drugs should be thought of when sudden, unexplainable skin eruptions are observed. **Key words:** ACE inhibitors; angiotensin; adverse events; angioedema; losartan.

(Accepted July 30, 2001.)

Acta Dermato Venereol 2001; 81: 321–325.

Ulrike M. Steckelings, Experimental Dermatology, Charité, Campus Virchow Klinikum, Augustenburger Platz 1, D-13344 Berlin, Germany. E-mail: steckelings@nexgo.de

Angiotensin-converting-enzyme (ACE) inhibitors are among the most commonly prescribed drugs, and are currently the standard medication in the treatment of hypertension and congestive heart failure (1, 2). They are the most frequently prescribed antihypertensive drugs because, apart from their high therapeutic efficiency, the incidence of severe adverse events from these agents is fairly low. Still, the overall incidence of adverse reactions (about 28%) is noteworthy, and, in particular, potentially life-threatening angioedema is feared (3). Adverse effects such as first-dose hypotension or hyperkalaemia can be explained by the physiology of ACE inhibition. The vast majority of adverse effects, however, is enigmatic and, although an explanation has been attempted in a number of studies, the nature of the underlying pathomechanisms remains speculative (4).

This review is aimed at familiarizing dermatologists with these drugs as well as their basic mechanisms and adverse effects in view of the potentially serious cutaneous reactions that may occur during their use. Initially, the known mechanisms of action of these drugs will be reviewed as a basis for an understanding of some of the most common adverse reactions to ACE inhibition. In the subsequent clinical part, the main focus will be on cutaneous adverse effects and their potential pathomechanisms. Finally, we present a novel explanation for ACE-inhibitor actions on skin.

BASIC ASPECTS OF ACE-INHIBITOR FUNCTION

ACE inhibitors block the activity of the metalloproteinase ACE by binding to its active site. They thereby neutralize the catalytic potency of the essential zinc ion and, coincidentally, displace angiotensin I (Ang I), its natural ligand and substrate (5).

Normally, Ang I is converted by ACE to angiotensin II (Ang II), the effective hormone of the renin-angiotensin system (RAS). Ang I, however, is not the only molecule which is cleaved by ACE. ACE acts in fact on a broad spectrum of substrates and is additionally responsible for the degradation of bradykinin, substance P, enkephalins and some of the reproductive peptide hormones (e.g. luteinizing hormone releasing factor (LHRH)). Thus, inhibition of ACE activity prevents not only the formation of Ang II, but also the breakdown of bradykinin, substance P and other peptides (Fig. 1) (5). The beneficial effect of ACE inhibitors on hypertension is based on several physiological mechanisms. A reduced supply of Ang II weakens its blood-pressure elevating actions, which are achieved by direct vasoconstriction, by an increase in body fluid volume through an enhanced release of mineralocorticoids, by an enhancement of vasopressin release, and by an activation of the sympathetic nervous system (1). In addition, bradykinin, if present in excess after ACE inhibition, has vasodilatory properties which contribute to the blood pressure lowering effect (1).

The beneficial effects of ACE inhibitors on heart failure are less well understood than those on hypertension. They most likely consist of a combination of limited left ventricular dilatation, lowered pre- and afterload, and reduced ventricular hypertrophy and fibrosis by opposing the trophic effects of Ang II on myocytes and fibroblasts (including collagen synthesis) (2). The latter effects may be enhanced by the antimitogenic properties of nitric oxide, which is released in response to bradykinin (6).

The acute effects of ACE inhibition (e.g. lowering of blood pressure) within the first 6 h after drug intake coincide with a reduction of circulating Ang II. After that, Ang II plasma levels rise progressively back to baseline values, while the effects of ACE inhibition still last or – in the case of improvement of cardiac failure – even only begin to be measurable after several weeks of treatment (5). It is theorized that inhibition of the so-called tissue RAS mainly contributes to the chronic or long-lasting effects of ACE inhibitors (7). Tissue RASs are defined as the presence of angiotensinogen, renin and ACE in close proximity within one tissue or organ, enabling the local, tissue-specific synthesis of Ang II independent of plasma-borne precursors (7). Such RASs have been described in various tissues, including rat skin (8) and, very recently, also in human skin (9).

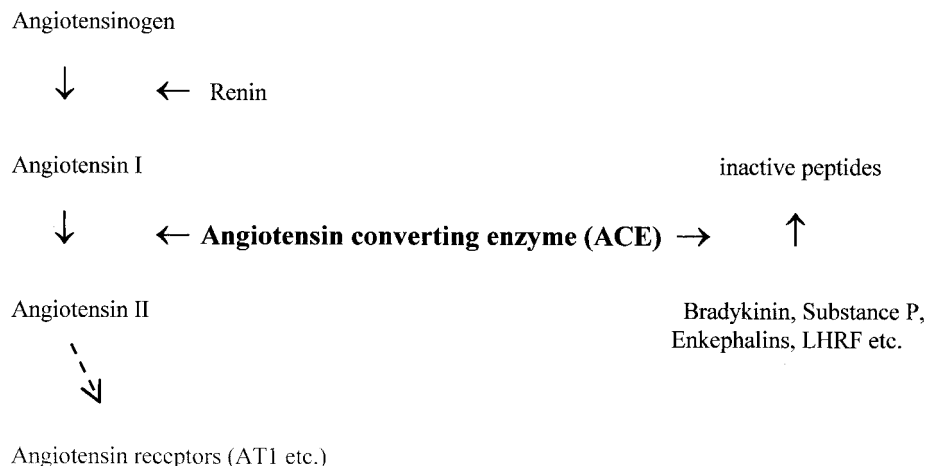


Fig. 1. Schematic presentation of the main ACE-inhibitor actions in the renin-angiotensin system (RAS) and other enzymatic processes (LHRF = luteinizing hormone releasing factor).

GENERAL ADVERSE REACTIONS TO ACE INHIBITORS

Based on the mechanisms of action of ACE inhibitors, there are a number of predictable adverse reactions. One of these is *first-dose hypotension*. Patients at risk for an abrupt fall in blood pressure after a first ACE-inhibitor intake are more likely to have high plasma renin before treatment. This group involves patients pretreated with high doses of diuretics, those with treatment-resistant hypertension, and patients with renovascular disease (4). Since a fall in systolic blood pressure of 50 mmHg and more can cause syncope, stroke or myocardial infarction, close monitoring at the start of treatment with ACE inhibitors is recommended in high-risk patients in an inpatient setting. Another common early effect of ACE treatment is *hyperkalaemia*. A rise in plasma potassium after ACE-inhibitor intake is a result of decreased aldosterone secretion and thereby of decreased renal potassium excretion. ACE inhibitor-induced hyperkalaemia is of clinical relevance, however, only in patients taking additional, potassium-raising drugs, especially potassium-sparing diuretics or potassium supplements (4).

Renal failure is another potentially serious adverse effect of ACE treatment. Angiotensin II is thought to maintain glomerular filtration by constriction of renal efferent arterioles in case the blood pressure within renal vessels is markedly decreased and that this status is not compensated by the contralateral kidney. Such a situation can be caused by stenosis or thrombosis of the renal artery or arteries. Since ACE inhibition blocks the compensating mechanism, renal failure may be the result (4).

Next to these predictable undesirable events, non-predictable adverse reactions may occur as well. These include dry, irritating *cough* as the probable most common adverse effect of ACE inhibitors. This cough occurs in about 10% of patients (10), and twice as much in women than in men (11). The pathomechanism is not clear. The ACE inhibitor-induced accumulation of bradykinin or substance P has been suspected as causing the cough, but in diverse studies no indication supporting this theory can be found (12, 13). ACE inhibitor-induced cough is often of such severity that ACE-inhibitor treatment has to be stopped.

Other relatively common reactions include *discomfort of the throat, voice changes or disturbances of taste*, with an incidence of 5% to 10% (4). These are less disturbing, however, and therefore not of great clinical or scientific interest.

CUTANEOUS ADVERSE EFFECTS

Angioedema

Among the long list of possible cutaneous adverse effects (Table I), ACE inhibitor-induced angioedema – despite the low incidence of 0.1% to 0.2% – is much feared because of its potentially life-threatening upper airway obstruction in classical locations such as the tongue and oropharynx (14, 15). Other less frequent and less dangerous locations are the skin, especially close to joints, and the intestine, where symptoms include severe abdominal pain, diarrhoea and emesis (16).

Some features of ACE inhibitor-induced angioedema make its diagnosis particularly difficult. Thus, although in most cases the lesions occur within the first 4 weeks after onset of treatment, they may also appear as late as several months after the first treatment dose (14, 17). To add to the diagnostic difficulties, ACE inhibitor-induced angioedema may regress spontaneously, despite continuation of treatment (18). In the literature, there are several reports of patients who have

Table I. Summary of general and cutaneous adverse effects of angiotensin-converting enzyme inhibitors

| General adverse effects | Cutaneous adverse effects |
|--------------------------|---|
| First-dose hypotension | Angioedema |
| Hyperkalaemia | Bullous eruptions |
| Renal failure | Pruritus |
| Dry cough | Urticaria |
| Discomfort of the throat | Pityriasis rosea |
| Voice changes | Erythema multiforme |
| Disturbances of taste | Psoriasiform, maculopapular and lichenoid eruptions |
| | Vasculitis |
| | Onycholysis |
| | Photosensitivity |

suffered from multiple episodes of angioedema until the correct diagnosis was finally made (18, 19).

The pathomechanisms of ACE inhibitor-induced angioedema are still a matter of debate. It is speculated that the accumulation of vasoactive peptides (bradykinin, histamine, substance P, prostaglandins) as a result of ACE inhibition are involved (14). Several studies have reported on increased wealing in response to intradermal bradykinin injections in volunteers who had previously taken ACE inhibitors (20, 21). Whether this experimental setting is suitable as a model for angioedema is, however, questionable and, moreover, other studies have failed to demonstrate any changes in the weal reaction to bradykinin under concomitant ACE inhibition (14, 22, 23). The currently favoured theory is that bradykinin – and/or other vasoactive peptides – may be involved in angioedema, but that they induce symptoms only in combination with certain genetic predispositions. The incidence of angioedema is for example significantly higher in Blacks of African origin (about 4.5 times), compared to Caucasians (19, 24), and angioedema more often seems to have a severe, life-threatening course in this group. Racial and genetic differences in the kallikrein-kinin system may be responsible since Blacks of African origin have an increased sensitivity to bradykinin (25). Other predispositions that are not related to ethnic aspects seem to exist as well, since patients with a history of idiopathic angioedema are at higher risk of developing angioedema in response to ACE inhibitors (26, 27). A history of previous manipulation or trauma of upper airways also seems to predispose to ACE inhibitor-induced angioedema (28).

Although many data support a role for bradykinin and/or other vasoactive peptides in ACE inhibitor-induced angioedema, some cases seem to be governed by a different pathomechanism, since angioedema has also been described after administration of the angiotensin AT1-receptor antagonist losartan (29, 30). (For further comments and explanations, see the section “Adverse reactions to losartan” below.)

It is generally recommended that treatment regimens should be completely changed and ACE inhibitors avoided in patients with a history of ACE-inhibitor-induced angioedema (15, 19). Although some patients appear to be sensitive only to specific ACE inhibitors (31), the reoccurrence of angioedema after switching from one ACE inhibitor to another has also been reported (32, 33). Taking into account that every episode of angioedema bears the risk of ending fatally, the continuation of ACE-inhibitor therapy after ACE-inhibitor-induced angioedema should be an exception and restricted to patients in whom ACE inhibitors are necessary for survival.

Urticaria

Compared to angioedema, urticaria is an even rarer adverse effect of ACE-inhibitor treatment. In most cases, it occurs during the first month of drug intake. Captopril, which in contrast to the vast majority of other ACE inhibitors carries a sulfhydryl group, seems to cause urticaria more often than the other drugs of this class (34).

Bullous eruptions and acantholysis

When one compiles case reports about cutaneous side effects of ACE inhibitors, it is striking that – apart from angioedema – the majority of eruptions include the formation of bullae.

The intracutaneous cleft can be localized at different levels within or in-between the epidermis or dermis, and thereby mimic diverse “classical” bullous skin diseases such as pemphigus vulgaris (35), pemphigus vegetans (36), bullous pemphigoid (37), linear IgA bullous dermatosis (38), and lichen planus pemphigoides (39). In some cases of ACE inhibitor-induced bullous eruptions, circulating or tissue-bound autoantibodies characteristic of the respective idiopathic bullous skin disease have also been detected (35, 40), but numerous other case reports have failed to document such autoantibodies in this condition (35, 41).

In vitro experiments have revealed that ACE inhibitors can cause acantholysis via at least two different non-immunological mechanisms. On the one hand, drugs containing sulfhydryl groups (thiols), such as the commonly used ACE inhibitor captopril, can evoke acantholysis by mechanisms interfering with the disulfide and thiol group balance (41, 42). On the other hand, enalapril, although lacking a sulfhydryl group, turned out to be an even stronger acantholytic agent than captopril or other thiol drugs (43). The mechanisms by which enalapril induces acantholytic effects are not completely clarified, but seem to involve the inhibition of transglutaminase activity (42). Therefore, ACE inhibitors may cause bullous eruptions by direct interference with cell cohesion without any involvement of immunologic mechanisms.

Other cutaneous adverse effects

Further types of cutaneous undesirable effects by ACE inhibitors have been reported only as single case reports. These comprise pityriasis rosea-like (44), psoriasiform (45), maculopapular (46) and lichenoid eruptions (47), erythema multiforme (48), vasculitis (46), onycholysis (49), photosensitivity (50) and hair-loss (51). Pruritus has also been recorded and is of special importance because it often precedes angioedema (19, 52). Thus, patients should be advised to report pruritus immediately, since in that case an interruption of ACE-inhibitor therapy must be considered.

ADVERSE REACTIONS TO LOSARTAN

Losartan was the first drug marketed from a novel class of antihypertensives which function via a blockade of the angiotensin AT1 receptor. Since the AT1 receptor mediates all “classical” cardiovascular actions of angiotensin II, the pharmacological effects of losartan were expected to resemble those of ACE inhibitors; i.e. the receptor blockade was thought to have similar effects as a reduced supply of the effective ligand. Clinical studies have indeed shown that losartan is comparable to ACE inhibitors in terms of its efficacy in the treatment of hypertension as well as cardiac failure (53–55).

A comparison of desirable and adverse effects of AT1 blockers and ACE inhibitors is of special interest inasmuch as – according to current knowledge – AT1 antagonists exclusively interfere with the RAS, while ACE inhibitors additionally lead to the accumulation of various vasoactive peptides. Consequently, beneficial and undesirable effects that are identical after AT1 antagonist or ACE-inhibitor treatment, respectively, are most likely caused by inhibition of angiotensin II actions, while those that are seen only after ACE-inhibitor exposure probably involve the action of vasoactive peptides such as bradykinin (56).

The two adverse effects very typical of ACE inhibitors, namely cough and angioedema, are thought to involve bradykinin actions. Therefore, losartan was expected to be free of these adverse reactions. Nevertheless, several reports can be found about losartan-induced angioedema (29, 30), thus not supporting an exclusive involvement of bradykinin. Patients with a history of ACE-inhibitor-induced angioedema even seem to be at higher risk of developing the same adverse reactions under losartan treatment (57). Although the precise incidence of losartan-induced angioedema seems not to be clear as yet, the vast majority of investigators share the opinion that it is lower than with ACE inhibitors (58).

Dry cough has also been reported after losartan. Recent studies, however, reveal that the incidence of cough in losartan-treated patients is not significantly different, compared to patients receiving placebo, and it is significantly lower than in patients taking ACE inhibitors (59, 60). Taken together, the comparison of losartan versus ACE-inhibitor-induced adverse effects suggests that bradykinin is involved in cough induced by these drugs, but less significantly in angioedema. Further experiments and clinical observations are necessary to prove this hypothesis.

NEW ASPECTS OF THE PATHOMECHANISM OF ACE-INHIBITOR-INDUCED ADVERSE EFFECTS

Unlike the cutaneous undesirable effects of most other drugs, ACE-inhibitor-induced adverse reactions affecting the skin seem mostly to be based on non-immunological mechanisms. The feared complication of angioedema, for example, seems to be caused at least in some cases by an interference of ACE inhibition with local hormonal systems (bradykinin or other vasoactive peptides). The pathomechanisms of ACE-inhibitor-induced bullous eruptions seem in many cases to involve a direct influence of ACE inhibition on intercellular cohesion.

We were recently able to demonstrate the expression of a complete RAS in human skin, including the precursor of angiotensin II, angiotensinogen, the enzymes necessary for angiotensin II synthesis, renin and ACE, as well as angiotensin receptors of the AT₁ and AT₂ subtype (9, 61). These data suggest a local synthesis of angiotensin II in human skin and the existence of autocrine and paracrine systems. Thus, the expression of ACE makes it likely that ACE inhibitors directly interact with the cutaneous RAS, resulting in an inhibition of the local synthesis of angiotensin II. The physiological functions of angiotensin II in human skin and the consequences of a diminished synthesis are currently not known. We suggest, however, that putative alterations within the cutaneous RAS by ACE-inhibitor treatment should be considered when looking for the pathomechanisms of its adverse reactions. This holds especially true for the ACE-inhibitor-induced bullous eruptions, because angiotensin II is known to influence the expression of adhesion molecules and integrins (62, 63). Taken together, cutaneous adverse reactions to ACE inhibitors are common but far from being understood. Some involve immunological, the majority non-immunological mechanisms, one of which may be an interference with the local cutaneous renin-angiotensin system. Since they can mimic a broad variety of "classical" skin diseases, dermatologists should always consider them as the cause of sudden, unexplained skin eruptions in patients taking ACE inhibitors, especially in the case of angioedema and bullous eruptions.

REFERENCES

- Schachter M. ACE inhibitors in hypertension. In: Schachter M, editor. ACE inhibitors: current use and future prospects. London: Martin Dunitz Ltd; 1995. p. 65–77.
- Kromer EP, Riegger GAJ. ACE inhibitors in the management of cardiac failure. In: Schachter M, editor. ACE inhibitors: current use and future prospects. London: Martin Dunitz Ltd; 1995. p. 95–121.
- Kostis JB, Shelton B, Gosselin G, Goulet C, Hood WB Jr, Kohn RM, et al. Adverse effects of enalapril in the studies of left ventricular dysfunction (SOLVD). *Am Heart J* 1996; 131: 350–355.
- Yeo WW, Morice AH. Adverse reactions to ACE inhibitors. In: Schachter M, editor. ACE inhibitors: current use and future prospects. London: Martin Dunitz Ltd; 1995. p. 145–157.
- Guidicelli JF, Berdeaux A, Richer C, Pussard E, Demolis P. Basic cardiovascular pharmacology of ACE inhibitors. In: Schachter M, editor. ACE inhibitors: current use and future prospects. London: Martin Dunitz Ltd; 1995. p. 43–62.
- Linz W, Schölkens BA. A specific β_2 -bradykinin receptor antagonist HOE 140 abolishes the antihypertrophic effect of ramipril. *Br J Pharmacol* 1992; 105: 771–772.
- Dzau VJ. Circulating versus local renin-angiotensin system in cardiovascular homeostasis. *Circulation* 1988; 77 Suppl 1: 14–13.
- Phillips MI, Kimura B, Gyurko R. Angiotensin receptor stimulation of transforming growth factor- β in rat skin and wound healing. In: Saavedra JM, Timmermans BMW, editors. Angiotensin receptors. New York: Plenum Press; 1994. p. 377–396.
- Hugow T, Artuc M, Henz BM, Mangoldt D, Peters J, Steckelings UM. Normal skin as a potential source for angiotensin II. *Arch Dermatol Res* 1998; 290: 49.
- Overlack A. ACE inhibitor-induced cough and bronchospasm. Incidence, mechanisms and management. *Drug Saf* 1996; 15: 72–78.
- Os I, Bratland B, Dahloff B, Gisholt K, Syvertsen JO, Tretli S. Female sex as an important determinant of lisinopril-induced cough. *Lancet* 1992; 339: 372.
- Overlack A, Muller B, Schmidt L, Scheid ML, Muller M, Stumpe KO. Airway responsiveness and cough induced by angiotensin converting enzyme inhibition. *J Hum Hypertens* 1992; 6: 387–392.
- Choudry NB, Fuller RW, Pride NB. Sensitivity of the human cough reflex: effect of inflammatory mediators prostaglandin E₂, bradykinin and histamine. *Am Rev Respir Dis* 1989; 140: 137–141.
- Vleeming W, van Amsterdam JG, Stricker BH, de Wildt DJ. ACE inhibitor-induced angioedema. Incidence, prevention and management. *Drug Saf* 1998; 18: 171–188.
- Langauer-Messmer S, Bircher AJ. Überempfindlichkeitsreaktionen auf Angiotensin-converting-enzyme-Hemmer (Hypersensitivity reactions to ACE inhibitors). *Allergologie* 1997; 8: 393–399.
- Mullins RJ, Shanahan TM, Dobson RT. Visceral angioedema related to treatment with an ACE inhibitor. *Med J Aust* 1996; 165: 319–321.
- Schiller PI, Messmer SL, Haefeli WE, Schlienger RG, Bircher AJ. Angiotensin-converting enzyme inhibitor-induced angioedema: late onset, irregular course, and potential role of triggers. *Allergy* 1997; 52: 432–435.
- Brown NJ, Snowden M, Griffin MR. Recurrent angiotensin-converting enzyme inhibitor-associated angioedema. *JAMA* 1997; 278: 232–233.
- Gibbs CR, Lip GYH, Beevers DG. Angioedema due to ACE inhibitors: increased risk in patients of African origin. *Br J Clin Pharmacol* 1999; 48: 861–865.
- Fuller RW, Warren JB, McCusker M, Dollery CT. Effect of enalapril on the skin response to bradykinin in man. *Br J Clin Pharmacol* 1987; 23: 88–90.
- Li Kam Wa TC, Cooke ED, Turner P. A comparison of captopril and enalapril on skin responses to intradermal bradykinin and

- skin blood flow in the human forearm. *Br J Clin Pharmacol* 1993; 35: 8–13.
22. Li Kam Wa TC, Cooke ED, Beacham J, Turner P. Absence of potentiation of the skin response to intradermal bradykinin by a long-acting angiotensin converting enzyme inhibitor, trandalopril, at conventional antihypertensive dosage in human volunteers: a double-blind, randomized, cross-over, placebo-controlled trial. *Postgrad Med J* 1992; 68: 742–745.
 23. Wa TC, Cooke ED, Turner P. Cutaneous blood flow changes and weal induced by intradermal bradykinin following pretreatment with indomethacin and captopril. *Eur J Clin Pharmacol* 1993; 44: 41–45.
 24. Brown N, Ray WA, Snowden M, Griffin MR. Black Americans have an increased rate of angiotensin-converting enzyme inhibitor-associated angioedema. *Clin Pharmacol Ther* 1996; 10: 8–13.
 25. Gainer JV, Nadeau JH, Ryder D, Brown NJ. Increased sensitivity to bradykinin among African Americans. *J Allergy Clin Immunol* 1996; 98: 283–287.
 26. Orfan N, Patterson R, Dykewicz MS. Severe angioedema related to ACE inhibitors in patients with a history of idiopathic angioedema. *JAMA* 1990; 264: 1287–1289.
 27. Agostini A, Cicardi M. Contraindications to the use of ACE inhibitors in patients with C1 esterase-inhibitor deficiency. *Am J Med* 1991; 90: 278.
 28. Jain M, Armstrong L, Hall J. Predisposition to and late onset of upper airway obstruction following angiotensin-converting enzyme inhibitor therapy. *Chest* 1992; 102: 871–874.
 29. Van Rijnsoever EW, Kwee Zuiderwijk WJ, Feenstra J. Angioneurotic edema attributed to the use of losartan. *Arch Intern Med* 1998; 158: 2063–2065.
 30. Cha YJ, Pearson VE. Angioedema due to losartan. *Ann Pharmacother* 1999; 33: 936–938.
 31. Slater AJ, Merrill DD, Guess HA, Roylance PJ, Cooper WD, Inman WHW, et al. Clinical profile of angioedema associated with angiotensin-converting enzyme inhibition. *JAMA* 1988; 260: 967–970.
 32. McElligot S, Perloth M, Raish L. Angioedema after substituting lisinopril for captopril. *Ann Intern Med* 1992; 116: 426–427.
 33. Singer DRJ, MacGregor GA. Angioneurotic oedema associated with two angiotensin-converting enzyme inhibitors. *BMJ* 1986; 293: 1243.
 34. Wood SM, Mann RD, Rawlins MD. Angioedema and urticaria associated with angiotensin-converting enzyme inhibitors. *BMJ* 1987; 294: 91–92.
 35. Kuechle MK, Hutton KP, Muller SA. Angiotensin-converting enzyme inhibitor-induced pemphigus: three case reports and literature review. *Mayo Clin Proc* 1994; 69: 1166–1171.
 36. Pinto GM, Lamarao P, Vale T. Captopril-induced pemphigus vegetans with Charcot-Leyden crystals. *J Am Acad Dermatol* 1992; 281: 428.
 37. Mallet L, Cooper JW, Thomas J. Bullous pemphigoid associated with captopril. *DICP* 1989; 23: 63.
 38. Kuechle MK, Stegemeir E, Maynard B, Gibson LE, Leiferman KM, Peters MS. Drug-induced linear IgA bullous dermatosis: report of six cases and review of the literature. *J Am Acad Dermatol* 1994; 30: 187–192.
 39. Flageul B, Foldes C, Wallach D, Vignon-Pennamen MD, Cottenot F. Captopril-induced lichen planus pemphigoides with pemphigus-like features. A case report. *Dermatologica* 1986; 173: 248–255.
 40. Smith EP, Taylor TB, Meyer LJ, Zone JJ. Antigen identification in drug-induced bullous pemphigoid. *J Am Acad Dermatol* 1993; 29: 879–882.
 41. Yokel BK, Hood AF, Anhalt GJ. Induction of acantholysis in organ explant culture by penicillamine and captopril. *Arch Dermatol* 1989; 126: 965–956.
 42. Esposito C, Ruocco V, Cozzolino A, LoSchiavo A, Lombardi ML, Porta R. Are acantholysis and transglutaminase inhibition related phenomena? *Dermatology* 1996; 193: 221–225.
 43. De Angelis E, Lombardi ML, Grassi M, Ruocco V. Enalapril: a powerful *in vitro* non-thiol acantholytic agent. *Int J Dermatol* 1992; 31:722–724.
 44. Ghersetich I, Rindi L, Teofilo P, Tsampau D, Palleschi GM, Lotti T. Pityriasis rosea-like skin eruptions caused by captopril (Eruzione cutanea da captopril “pityriasis rosea-like”). *G Ital Dermatol Venerol* 1990; 125: 457–459.
 45. Wolf R, Tamir A, Brenner S. Psoriasis related to angiotensin-converting enzyme inhibitors. *Dermatologica* 1990; 181: 51–53.
 46. Carrington PR, Sanusi ID, Zahradka S, Winder PR. Enalapril-associated erythema and vasculitis. *Cutis* 1993; 51: 121–123.
 47. Phillips WG, Vaughan Jones S, Jenkins R, Breathnach SM. Captopril-induced lichenoid eruption. *Clin Exp Dermatol* 1994; 19: 317–320.
 48. Nebenwirkungen von ACE-Hemmern. In: Rote Liste® Service GmbH ed. Rote Liste 2000 Aulendorf: ECV · Editio Cantor Verlag, 2000.
 49. Borders JV. Captopril and onycholysis. *Ann Intern Med* 1986; 105: 305–306.
 50. Smit AJ, Van der Laan S, de Monchy J, Kallenberg CG, Donker AJ. Cutaneous reactions to captopril. *Clin Allergy* 1984; 14: 413–419.
 51. Motel PJ. Captopril and alopecia: a case report and review of known cutaneous reactions in captopril use. *J Am Acad Dermatol* 1990; 23: 124–125.
 52. Thestrup-Pedersen K. Adverse reactions in the skin from anti-hypertensive drugs. *Dan Med Bull* 1987; 34 Suppl 1: 3–5.
 53. Weber MA. Comparison of type I angiotensin II receptor blockers and angiotensin converting enzyme inhibitors in the treatment of hypertension. *J Hypertens Suppl* 1997; 15: 31–36.
 54. Aronow AS. The ELITE study. What are its implications for the drug treatment of heart failure? Evaluation of losartan in the elderly study. *Drugs Aging* 1998; 12: 423–428.
 55. Pitt B, Poole-Wilson PA, Segal R, Martinez FA, Dickstein K, Camm AJ, et al. Effect of losartan compared with captopril on mortality in patients with symptomatic heart failure: randomised trial – the Losartan Heart Failure Survival Study ELITE II. *Lancet* 2000; 355: 1582–1587.
 56. Timmermans PB, Duncia JV, Carini DJ, Chiu AT, Wong PC, Wexler RR, et al. Discovery of losartan, the first angiotensin II receptor antagonist. *J Hum Hypertens* 1995; 9 Suppl 5: S3–18.
 57. Sharma PK, Yium JJ. Angioedema associated with angiotensin II receptor antagonist losartan. *Southern Med J* 1997; 90: 552–553.
 58. Howes LG, Christie N. Angiotensin receptor antagonists and ACE inhibitors. *Australian Fam Phys* 1998; 27: 914–917, 919–921.
 59. Paster RZ, Snavely DB, Sweet AR, Draper RA, Goldberg AI, Soffer BA, et al. Use of losartan in the treatment of hypertensive patients with a history of cough induced by angiotensin-converting enzyme inhibitors. *Clin Ther* 1998; 20: 978–989.
 60. Chan P, Tomlinson B, Huang TY, Ko JT, Lin TS, Lee YS. Double-blind comparison of losartan, lisinopril, and metolazone in elderly hypertensive patients with previous angiotensin-converting enzyme inhibitor-induced cough. *J Clin Pharmacol* 1997; 37: 253–257.
 61. Steckelings UM, Wiehstutz S, Henz BM, Artuc M. Expression of angiotensin AT₁- and AT₂-receptors in human skin. *Arch Dermatol Res* 2000; 292: 139.
 62. Pastore L, Tessitore A, Martinotti S, Toniato E, Alesse E, Bravi MC, et al. Angiotensin II stimulates intercellular adhesion molecule-1 (ICAM-1) expression by human vascular endothelial cells and increases soluble ICAM-1 release *in vivo*. *Circulation* 1999; 100: 1646–1652.
 63. Kawano H, Cody RJ, Graf K, Goetze S, Kawano Y, Schnee J, et al. Angiotensin II enhances integrin and alpha-actinin expression in adult rat cardiac fibroblasts. *Hypertension* 2000; 35: 273–279.