

CLINICAL REPORT

Intradermal Buried Vertical Mattress Suture as Sole Skin Closure: Evaluation of 149 Cases

ULRICH HOHENLEUTNER, NICOLE EGNER, SILVIA HOHENLEUTNER and MICHAEL LANDTHALER

Department of Dermatology, University of Regensburg, Regensburg, Germany

Various buried suture techniques have been reported for dermatological surgery, but in most cases, superficial non-absorbable sutures are placed additionally. The aim of this study was to evaluate whether the intradermal buried vertical mattress suture can be safely used without additional skin suturing. Following 149 procedures in 126 patients, the colour and dehiscence of the scar and the presence of hypertrophy, granulomas or keloids were analysed. The cosmetic results were excellent to good in 78.5%, satisfactory in 19.5% and poor in 2%. Single additional superficial sutures had to be placed in only 14.7%. Suture marks were absent. Hypertrophic scarring was significantly more frequent in scars sutured with polyglactine than in scars sutured with polydioxanone. Early wound dehiscence, secondary wound healing and infection due to missing superficial skin sutures did not occur. This suture technique is safe, easy and fast to perform, and achieves good cosmetic results without leaving suture marks. **Key words:** suture techniques; polydioxanone; polyglactine. (Accepted August 21, 2000.)

Acta Derm Venereol 2000; 80: 344–347.

Ulrich Hohenleutner, Department of Dermatology, University of Regensburg, Franz-Josef-Strauß Allee 11, D-93053, Regensburg, Germany.
E-mail: Ulrich.Hohenleutner@klinikuni-regensburg.de

A wide array of suturing techniques exists for cutaneous surgery. Wound closure can be achieved by a variety of continuous and interrupted, surface and buried suturing techniques (1). The final cosmetic result in a surgical wound depends on many parameters, but the suturing technique is one of the most important. It has to reduce tension on the wound edges, evert skin edges to produce exact wound adaptation and avoid permanent suture marks. At the same time, the technique should not be time-consuming or difficult to place (1).

The intradermal vertical mattress suture with resorbable material is a buried suture which fulfils the above-mentioned criteria. The postoperative care is minimal, no sutures have to be removed and suture marks are avoided. Nevertheless, most authors recommend additional superficial skin sutures (1) as necessary for sufficient epidermal wound edge apposition (2–4).

To evaluate whether this technique can be used safely without additional, superficial sutures for routine skin closure in dermatological surgery, follow-up examinations were performed in 126 patients with 149 procedures.

MATERIAL AND METHODS

Suturing technique

For the intradermal vertical mattress suture, the needle is inserted in the deep reticular dermis or the superficial subcutaneous tissue, describes an upward arch perpendicular to the surface and is brought

out very close to the epidermis (Fig. 1A). With the opposing skin margin gently everted, the needle describes the same arc on the opposite site except that it starts immediately below the epidermis, ending in the same depth as the initial insertion site. The knot is tied and buries itself subdermally in the wound (Fig. 1B). To achieve perfect adaptation of the wound edges without additional skin sutures, it is necessary to place the upper part of the suture as superficially as possible without severing the skin surface.

Study design

This investigation analysed the outcome in patients for whom, over a 1-year period, the intradermal vertical mattress suture as described above had been used for skin closure in the Department of Dermatological Surgery.

The suture material used was either absorbable monofilament polydioxanone (PDS IITM) or absorbable polyfilament polyglactine 910 (VicrylTM; both by Ethicon GmbH, Norderstedt, Germany). The gauges used were 6/0 to 2/0 for polydioxanone and 5/0 to 0 for polyglactine according to the thickness of the dermis and the amount of tension on the wound remaining after adequate undermining. Routinely, no additional superficial skin sutures were performed. Only if exact epidermal adaptation could not be achieved by the intradermal sutures alone, single conventional, superficial skin sutures were placed additionally using a non-absorbable monofilament material (SeralonTM; Serag-Wiessner, Naila, Germany, gauges from 6/0 to 3/0).

Wound closure tapes (Steri-StripTM, 3M HealthCare, St. Paul, MN, USA) were then applied to the surgical wound, and simple sterile gauze dressings without any antibiotic ointments were used as bandage. The tapes were removed after 5 days. If additional non-absorbable sutures had been necessary, these were also removed after 5 days, independent of the anatomical region. In addition to the usual operation report, the amount of tension on the wound was documented (none or mild, moderate, strong) immediately after surgery.

At the follow-up examination, the patients were evaluated by 2 dermatological surgeons with respect to suture length, colour and width of the scar, presence of permanent suture marks, hypertrophic scarring, granuloma or keloid formation and scar dehiscence.

The dehiscence was defined as the actual scar width at the time of evaluation calculated in per cent of the entire suture length (e.g. scar length 10 cm, width 0.4 cm, dehiscence 4%).

The results were classified as follows:

1. excellent (score= 1): less than 5% dehiscence, no hypertrophic scarring and no granuloma or keloid formation;
2. good (score= 2): dehiscence between 5 and 10%, no hypertrophic scarring, no granulomas or keloid;
3. acceptable (score= 3): dehiscence between 10 and 20%, either hypertrophic scarring or granulomas, no keloids;
4. poor (score= 4): dehiscence greater than 20%, with or without hypertrophy or granulomas, or keloid formation.

The results were analysed and compared using Fisher's exact test, Mann-Whitney *U*-test or Pearson's correlation coefficients, as applicable.

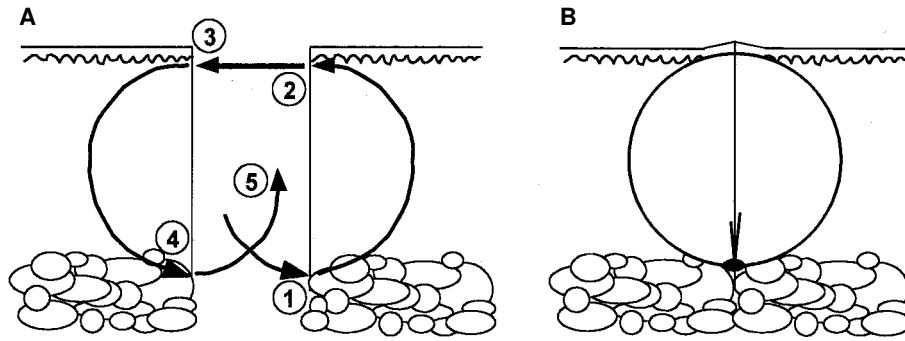


Fig. 1. (A) Diagram of the intradermal buried suture technique as described in the text. Especially important is the very superficial, almost subepidermal, placement of the superior arc of the suture. (B) After tying the buried knot, the closed loop of the suture should lead to exact epidermal adaptation with slight eversion of the wound edges.

RESULTS

The results of 149 procedures in 126 patients could be evaluated with a mean follow-up time of 28 weeks (13–64 weeks). Fusiform excisions and M-plasties (92.6%) for removal of skin tumours or naevi were the most frequent of the procedures performed, including some regional flaps (6.7%) and incisions (for cysts or lipomas, 0.7%).

Polydioxanone had been used in 91.3% and polyglactine in 8.7%, with the surgeon choosing the suture material. The wound tension had been judged as none or mild in 74.5%, moderate in 24.2% and strong in 1.3%. The suture lengths varied between 1 and 30 cm with a mean of 6.6 cm (± 4.0 cm).

In 43% the procedures were located in the face, followed by the trunk (29.5%), the upper extremities (13.4%), the head/neck area (10.7%), the anogenital area (2.7%) and the lower extremities (0.7%). The mean patient age in the 149 procedures (at the time of surgery) was 41.4 years (median 45.0, range 1–89).

The overall cosmetic results, as classified above, were excellent in 65.1%, good in 13.4%, acceptable in 19.5% and poor in 2% (mean result score 1.58). A representative result is shown in Fig. 2.

In 85.3%, the buried intradermal suture alone was sufficient for exact adaptation. Only in 22 cases (14.7%) did single additional skin sutures have to be placed. In no case it was necessary to use additional sutures over the entire wound length.

The wound dehiscence in correlation to the suture length was <5% in 68.5%, 5–10% in 20.8%, 10–20% in 9.3% and <20% in only 1.4%. The scar was skin-coloured in 42.3%, reddish in 43.6%, hyperpigmented in 2% and hypopigmented in 12.1%. Hypertrophic scarring was present in 10.1%, keloid formation in 1.3% and granulomas in 3.4%. According to the patients, there had been no case of wound infection, delayed wound healing or early scar dehiscence.

There was a significantly higher frequency of hypertrophic scarring and keloids in scars sutured with polyglactine (31%) than in scars sutured with polydioxanone (8%) ($p < 0.0001$, Fisher's exact test). The anatomical location as well as the tension and length of the wound were not significantly different in the polyglactine and the polydioxanone groups (Mann-Whitney *U*-test).

The cosmetic result also depended on the body region and the mean result scores are given in Fig. 3. The mean result

score of all non-facial localizations was 1.76, while the mean result score in the face was significantly better (1.34, $p = 0.029$, Mann-Whitney *U*-test). In detail, in the face the results were excellent in 78.1%, good in 10.9%, acceptable in 9.4% and poor in 1.6%. The mean suture length in the face was 5.9 cm (± 3.8 cm) and thus not fundamentally different from the entire population (6.6 cm, see above).

A significant (and predictable) positive correlation could be found between the length of the suture and the dehiscence of the scar ($p = 0.009$). The overall cosmetic result, nevertheless,

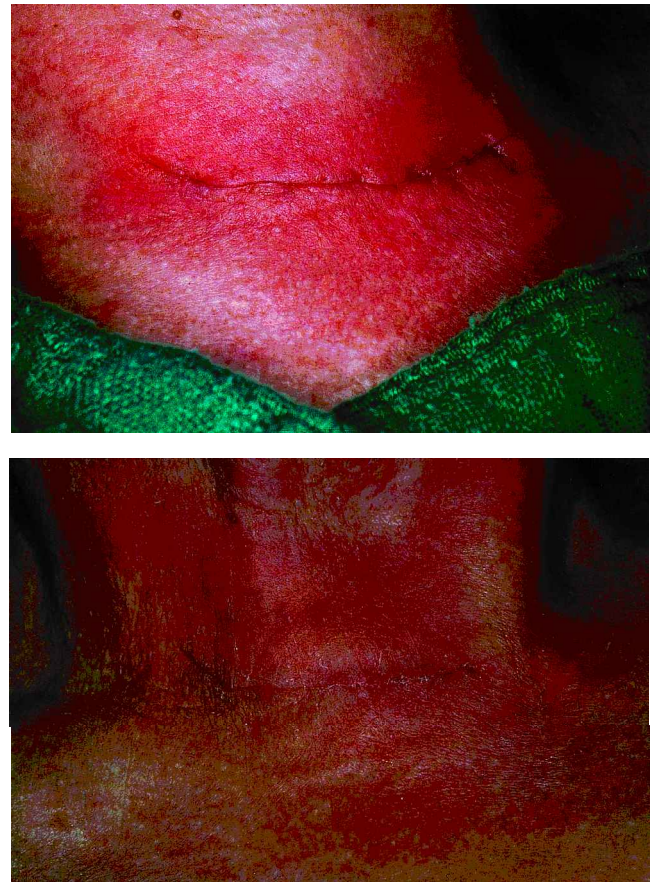


Fig. 2. (A) Typical aspect of buried intradermal suture immediately after excision of a congenital naevus in the suprajugular area of the neck. (B) Early excellent result 7 days after surgery.

was not influenced by the length of the wound (Pearson's correlation coefficients, 2-sided).

Although a tendency was noticed towards better overall results with less wound tension, this correlation was not significant ($p=0.06$). There was no significant correlation between wound tension and scar dehiscence (Pearson's correlation coefficients, 2-sided).

DISCUSSION

According to Moy et al. (1), the ideal wound closure technique should provide maximal wound eversion and maintain tensile strength throughout the healing process, be technically simple and fast to perform, and allow precise wound edge adaptation without leaving suture marks.

Most of these criteria are already met by the standard intradermal buried vertical mattress suture (1, 3). However, additional superficial skin sutures are often necessary to achieve exact epidermal apposition (2–4) and have to be removed early to avoid permanent suture marks.

The standard technique was slightly modified by placing the superior part of the suture as superficial as possible below the epidermis, so that a perfect adaptation of the wound edges became possible. As the results show, by using this modified technique additional sutures can be omitted in most cases without worsening the cosmetic result or increasing the frequency of complications.

As in all buried sutures, great care has to be taken to place the initial insertion of the needle, and thus the buried knot, deep enough in the dermis or the subcutaneous tissue and to cut the suture ends as short as possible. Otherwise, especially if polydioxanone with its relative stiffness is used, there is a possibility that either the knots or the suture ends will "spit" through the surface. Taking this into account, this suture technique can even be used safely in areas with relatively thin skin, as in the face. This is underscored by this study, in that the cosmetic results in the face were even better than in any other anatomical region.

Other variations on the buried vertical mattress suture that are performed without additional superficial sutures include the modified buried vertical mattress suture as described by Sadick et al. (5), Wong's variant of the running locked intradermal suture (2) and the intracutaneous butterfly suture by Breuninger et al. (6).

In Sadick's technique, the needle is inserted in the deep dermis, exits the skin close to the wound, is reinserted through the same hole, crosses the wound subepidermally, is exited and reinserted through the same hole, again, and a buried

knot is tied (5). According to the authors, this technique, however, is contraindicated in the face and other areas with a thin dermis, and suture fraying is possible. The advantages of this technique, as described by the authors, include easy mastery and rapid performance, one suture material for both deep and superficial skin closure, minimal infection potential, excellent cosmesis without suture marks, excellent haemostasis due to the dermal suture component, excellent tensile strength by longstanding retention of the buried suture, minimal need for postoperative care and early resumption of patient activity (5).

In the authors' opinion, all of these advantages also hold true for the modified technique of the simple buried vertical mattress suture, which is still simple and quick to perform, with a theoretically even lower infection potential (no exiting and reinsertion through the skin). As the results show, it is also well suited for areas with a thin dermis, as in the face (Fig. 3).

The running locked intradermal suture is described by Wong as an elegant technique for closure of wounds under light tension (2). It has all of the advantages cited above, but compared with interrupted buried sutures, it is more difficult to learn and to perform and there is more suture material in the wound (2). As in all running sutures, it is suited well for fusiform excisions but only partially practicable in M-, Z- and V-Y-plasties, etc., and in locoregional flaps, where interrupted sutures allow better compensation of unequal incision lengths and better adaptation of tips and edges.

The intracutaneous butterfly suture of Breuninger et al. (6) starts deep in the dermis, describes an oblique arch reaching the superficial dermis besides the wound edge and exits again deep in the dermis of the same wound side. The suture is completed by an corresponding arch on the other wound side, then the knot is tied. Tying the knot is reportedly more easy than in vertical buried mattress sutures since the knot lies not under but besides the loop of the suture. The outline of the completed suture resembles the margins of a butterfly's wings in an oblique position (6). This technique provides a maximum skin eversion with exact epidermal apposition leading to good cosmesis (good results in approximately 71%, $n=855$) but is somewhat difficult to learn and requires a certain amount of practice to achieve good results (6).

The modified buried vertical mattress suture is easier to learn and to perform and leads to comparable, if not at least tendentially better results (in the present study, excellent and good results in 78.5%). In the face, the results are even better (excellent and good results in 89.1%), even if, with a mean scar length of 5.9 cm, most of these facial procedures have to be classified as medium or large.

In contrast to Breuninger et al. (6), a significantly higher percentage of hypertrophic scarring was found when polyglactine was used in the present study. This may be due to the very superficial placement of the suture material: the relatively rough surface of the polyfilament polyglactine may lead to wound irritation and consequent hypertrophy.

As with all buried intradermal sutures, the limitations of this technique lie in areas with very fine, thin skin such as the lips, the periorbital areas or the ears, where the dermal thickness is not sufficient to place these sutures. In addition, intradermal sutures are very difficult to place in dog ear repair, in the adaptation of fine skin tips as necessary in V-Y, M- or Z-plasties and in very short incisions. In these cases, conventional superficial sutures using fine threads prove superior.

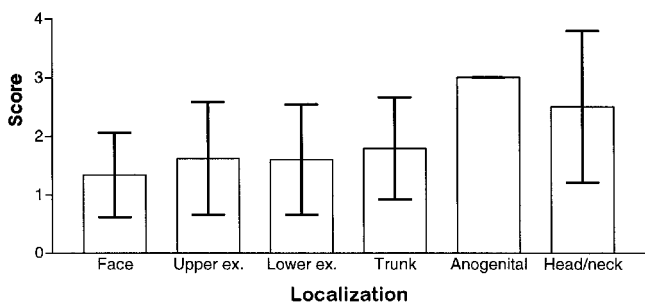


Fig. 3. Mean result scores depending on the body region (bars represent \pm SEM). Excellent=1; good=2; acceptable=3; and poor=4.

It must be stressed that, as in all suture techniques, the exact epidermal adaptation of the wound edges is crucial. If this cannot be achieved by intradermal suturing alone, as many additional superficial sutures as necessary have to be placed to reach this goal.

In the authors' opinion, the buried vertical mattress suture with a superficially placed upper loop is a very useful addition to the available dermatological suture techniques. If performed skilfully, it provides sufficient wound eversion and precise epidermal approximation leading to good cosmetic results without suture marks. It is a safe technique without side-effects such as wound infections or disturbance of wound healing. It is easy to learn and fast to perform, postoperative wound care is minimal and suture removal is not necessary, making this technique ideal for surgery in children.

REFERENCES

1. Moy RL, Waldman B, Hein DW. A review of sutures and suturing techniques. *J Dermatol Surg Oncol* 1992; 18: 785–795.
2. Wong NL. The running locked intradermal suture. *J Dermatol Surg Oncol* 1993; 19: 30–36.
3. Zitelli JA, Moy RL. Buried vertical mattress suture. *J Dermatol Surg Oncol* 1989; 15: 17–19.
4. Ftaiha Z, Snow SN. The buried running dermal subcutaneous suture technique. *J Dermatol Surg Oncol* 1989; 15: 264–266.
5. Sadick NS, D'Amelio DL, Weinstein C. The modified buried vertical mattress suture. A new technique of buried absorbable wound closure associated with excellent cosmesis for wounds under tension. *J Dermatol Surg Oncol* 1994; 20: 735–739.
6. Breuninger H, Keilbach J, Haaf U. Intracutaneous butterfly suture with absorbable synthetic suture material. Technique, tissue reactions, and results. *J Dermatol Surg Oncol* 1993; 19: 607–610.