

CLINICAL REPORT

Coexistence of Xeroderma Pigmentosum with Sarcoidosis and Adenocarcinoma of the Digestive Organs

MIKIKO OKADA¹, MISAKO TANAKA², NORIHISA HORIUCHI³, TAIZO KATO⁴ and HACHIRO TAGAMI¹

Departments of Dermatology, ¹Tohoku University School of Medicine, ²Sendai Shakaihoken Hospital, ³Sendai Red Cross Hospital and ⁴Tohoku Kouseinenkin Hospital, Sendai, Japan

Xeroderma pigmentosum has not been reported in association with any specific diseases except for skin malignancy. We observed a case of its coexistence with sarcoidosis and adenocarcinoma of the digestive organs, which has been reported only once in the past. A 54-year-old Japanese female with a variant type of xeroderma pigmentosum developed successively multiple lesions of basal cell carcinoma and squamous cell carcinoma on her face. Intensive metastasis studies led to the incidental detection of non-caseating epithelioid cell granulomas in one of the palpable right supraclavicular lymph nodes. Similar granulomas were also revealed in the excised tissue specimen of squamous cell carcinomas of her left cheek. She was also found to have bilateral hilar lymphadenopathy and chronic uveitis. Three years later, she died of colon adenocarcinoma and its liver metastasis. **Key words:** xeroderma pigmentosum; sarcoidosis; adenocarcinoma; digestive organs.

(Accepted June 15, 2000.)

Acta Derm Venereol 2000; 80: 376–377.

Hachiro Tagami, MD, Ph.D., Department of Dermatology, Tohoku University School of Medicine, 1-1 Seiryomachi, Aobaku, Sendai 980-8574, Japan

Xeroderma pigmentosum (XP) is a rare autosomal recessive disease which is characterized by photosensitivity and a high risk of skin malignancy and neurological defects. It is divided into 8 subtypes (1), i.e. complementation groups A–G and the variant type, from the characteristics of unscheduled DNA synthesis, photosensitivity and neurological symptoms. In Japan, the group A and variant type account for most XP patients (1). The variant type is clinically indistinguishable from classical XP but there is a defect in post-replication DNA repair following ultraviolet (UV) exposure, rather than nucleotide excision repair (2). Recently, we encountered a female patient showing the coexistence of the variant type of XP, sarcoidosis and colonic adenocarcinoma, which has previously been reported only once (3).

CASE REPORT

A 54-year-old Japanese female presented with numerous pigmented spots on her exposed skin and some tumors on her face. The pigmented spots had appeared when she was aged 7 years and the tumors had developed just a few years before the present examination. Based on the lack of any neurological symptoms, as well as her past history of lesions on exposed skin, she was suspected of having the variant type of XP. Her parents were not consanguineous and none of her family members, including 2 sons aged 30 and 25 years and a 1-year-old granddaughter, suffered from XP. Physical

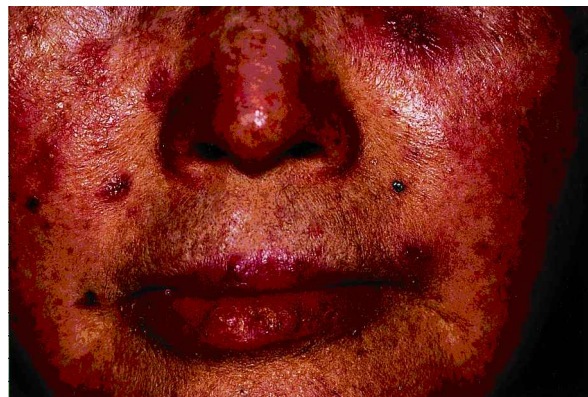

Fig. 1. The presence of basal cell carcinoma and squamous cell carcinoma.

examination revealed 2 black papules 3 mm in diameter and 3 ulcers, 2 of which were 5 mm long, along her nasolabial folds, in addition to a 3 mm red ulcerated nodule on her left cheek (Fig. 1).

We surgically excised all the tumorous lesions. Those along her nasolabial folds were found to be basal cell carcinomas (BCCs) and the ulcerated nodule on the cheek was found to be a squamous cell carcinoma (SCC) on histology. After surgery, she was administered oral etretinate 10 mg daily.

Six months later, another SCC lesion that appeared on her lower lip was surgically removed. Searching for its metastasis, we performed further examinations such as computerized tomography and Ga scintigram, which enabled us to diagnose bilateral hilar lymphadenopathy. A biopsy specimen from one of the palpable right supraclavicular lymph nodes revealed the presence of non-caseating epithelioid cell granulomas with giant cells (Fig. 2). Further laboratory tests performed on the basis of a suspected diagnosis of sarcoidosis disclosed anemia, negative tuberculin reaction and elevations in serum lysozyme levels and the erythrocyte sedimentation

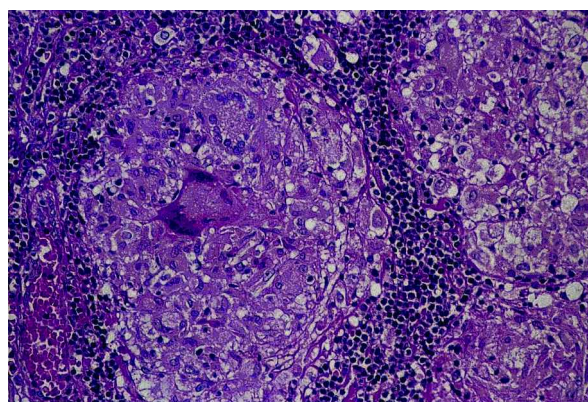


Fig. 2. Non-caseating epithelioid cell granulomas with giant cells found in the tissue of the palpable right supraclavicular lymph node. Hematoxylin–eosin stain; original magnification $\times 50$.

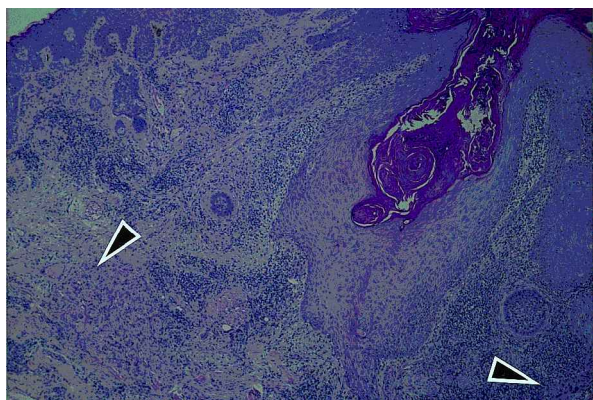


Fig. 3. Lower magnification image showing the coexistence of non-caseating epithelioid granuloma with giant cells (left arrow) and atypical squamoid cells in the dermis of the left cheek (right arrow). Hematoxylin–eosin stain; original magnification $\times 10$.

rate. However, her serum levels of immunoglobulins, angiotensin-converting enzyme and calcium were within normal limits. In her right eye, there were mutton-fat precipitates and a small trabecular nodule suggestive of uveitis. Echocardiography and electrocardiogram did not reveal any signs of cardiac involvement.

Six months later, another new tumor appeared on her left cheek. The histology of the removed lesion showed the coexistence of non-caseating epithelioid granuloma with giant cells of sarcoidosis and SCC (Fig. 3). Studies of unscheduled DNA synthesis of fibroblasts from this patient showed normal results by the DNA repair test. Cutaneous UV sensitivity or caffeine sensitization of cultured fibroblasts were not determined. The results indicated that the patient had the variant type of XP.

Two years later, she was admitted to another hospital because of lower abdominal pain. She was found to have adenocarcinoma of the colon with multiple liver metastasis. She died several months later.

DISCUSSION

The present case is unique because the skin symptoms of XP were so mild that the successive development of skin malignancy started after the patient had attained the age of 50 years. Moreover, intensive studies for metastasis from cutaneous SCC led to the incidental detection of sarcoidosis and, a few years later, she developed colon cancer with multiple liver metastasis. Although there is a possibility of this case representing a mere coincidence, we cannot rule out some possible relationship between XP, sarcoidosis and adenocarcinoma of the digestive organs that occurred in this patient, based on the case reported by Maradona Hidalgo et al. (3).

Mamada et al. (4) have described the age-related increased incidence of internal malignancies in Japanese patients with XP. A review of the recent literature showed that the immunologic status of patients with XP was usually normal (5), despite numerous reports of immune abnormalities in

such patients (6–13). In our patient we suspect an underlying deficiency in tumor immunosurveillance, because sarcoidosis is well known to be associated with systemic immune deficiency.

ACKNOWLEDGEMENTS

The biopsy of one of the palpable right supraclavicular lymph nodes was conducted by Dr. K. Aikawa and Dr. H. Yoshida, Division of Surgery, Sendai Kosei Hospital, Sendai, Japan. Dr. Takashi Yagi at the Department of Radiation Genetics, Faculty of Medicine, Kyoto University kindly conducted the DNA repair test. Dr. Yoshiaki Satoh kindly gave us advice.

REFERENCES

1. Ichihashi M, Kondo M, Ueda M. Clinical and molecular characteristics of xeroderma pigmentosum. *J Pediatr Dermatol* 1994; 13: 43–49.
2. De Silva BD, Nawroz I, Doherty VR. Angiosarcoma of the head and neck associated with xeroderma pigmentosum variant. *Br J Dermatol* 1999; 141: 166–167.
3. Maradona Hidalgo JA, Alvarez Alvarez C, Fernandez Rippe ML, Suarez Garcia E, Soler Sanchez T. Sarcoidosis, adenocarcinoma pancreático y granulomas de origen indeterminado en un paciente con xeroderma pigmentosum. *Rev Clin Esp* 1983; 168: 357–360.
4. Mamada A, Miura K, Tsunoda K, Hirose I, Furuya M, Kondo S. Xeroderma pigmentosum variant associated with multiple skin cancers and a lung cancer. *Dermatology* 1992; 184: 177–181.
5. Goldstein B, Khilnani P, Lapey A, Cleaver JE, Rhodes AR. Combined immunodeficiency associated with xeroderma pigmentosum. *Pediatr Dermatol* 1990; 7: 132–135.
6. Lafforet D, Dupuy JM. Inhibitory factors of lymphocyte proliferation in serum from patients with xeroderma pigmentosum. *Clin Immunol Immunopathol* 1975; 4: 165–173.
7. Dupuy JM, Lafforet D. A defect of cellular immunity in xeroderma pigmentosum. *Clin Immunol Immunopathol* 1974; 3: 52–58.
8. Berkel AI, Kiran O. Immunological studies in children with xeroderma pigmentosum. *Turk J Pediatr* 1974; 16: 43–52.
9. Giraldo G, Degos L, Beth E, Sasportes M, Marcelli A, Gharbi R, et al. C8 deficiency in a family with xeroderma pigmentosum: lack of linkage to the HLA region. *Clin Immunol Immunopathol* 1977; 8: 377–384.
10. Wysenbeek AJ, Weiss H, Duczyminer-Kahana M, Grunwald MH, Pick AI. Immunologic alterations in xeroderma pigmentosum patients. *Cancer* 1986; 58: 219–221.
11. Sälamon T, Stojaković M, Bogdanović B. Delayed hypersensitivity in xeroderma pigmentosum. *Arch Dermatol Forsch* 1975; 251: 277–280.
12. Wysenbeek AJ, Pick AI, Weiss H, Vana D, Atsmon A. Impaired humoral and cellular immunity in xeroderma pigmentosum. *Clin Oncol* 1980; 6: 361–365.
13. Kraemer HK, Lee MM, Scotto J. Xeroderma pigmentosum: cutaneous, ocular, and neurologic abnormalities in 830 published cases. *Arch Dermatol* 1987; 123: 241–250.