

Woolly Hair Associated with Loose Anagen Hair

Sir,

Loose anagen hair syndrome is a form of alopecia that was first described in 1986 (1, 2). Subsequently, >60 cases have been reported (3–14). This syndrome features sparse scalp hair that does not grow long, and which can be easily and painlessly extracted from the scalp. Although children of both sexes are affected, the syndrome predominates in girls, most of whom are blond, although children with hair of all colors and from all parts of the world may be affected. Loose anagen hair syndrome usually presents in childhood, most commonly between the ages of 2 and 7. Although hair density and length increase with time and hair color usually darkens, the looseness persists.

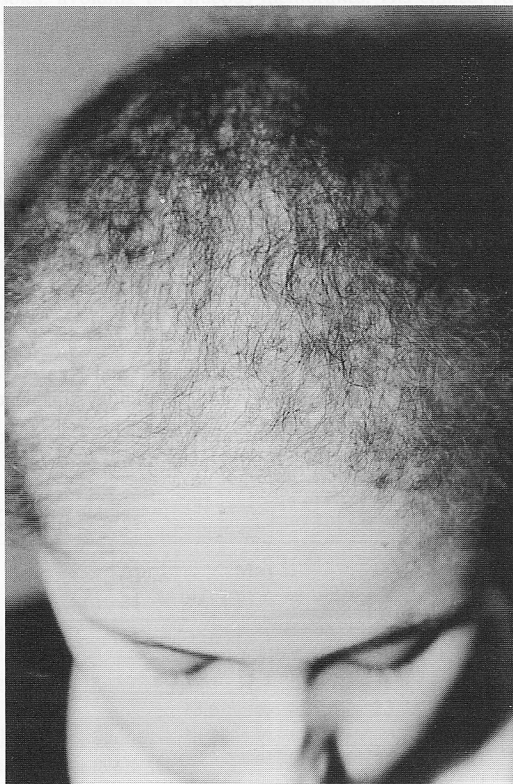
It is useful to classify loose anagen hair into 2 categories. In the first category, there are no associated abnormalities: this category includes the loose anagen hair syndrome and sporadic loose anagen hair that may be found in normal scalps. In the second category, loose anagen hair may be associated with developmental defects including nail-patella syndrome, Noonan's syndrome, EEC (ectrodactyly, ectodermal dysplasia, cleft lip/palate) (7), tricho-rhino-phalangeal syndrome, ocular coloboma (8) and hypohidrotic ectodermal dysplasia (9). We report here the first association of loose anagen hair with woolly hair.

CASE REPORT

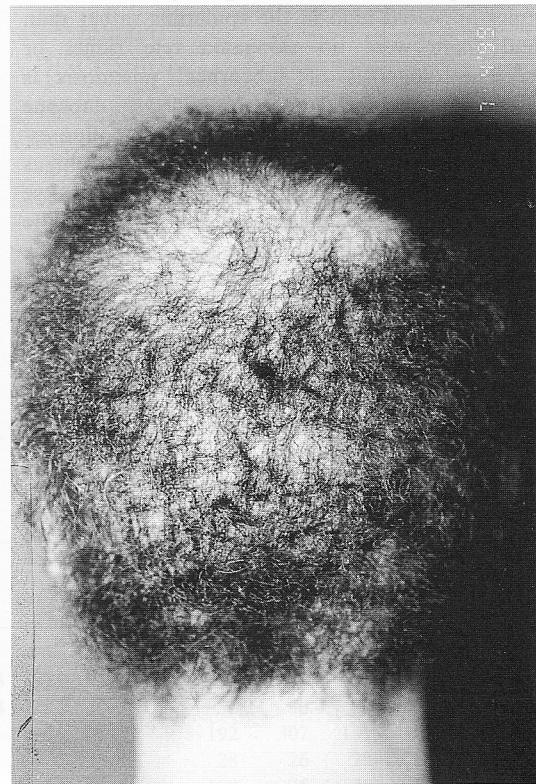A fair-haired girl first presented with woolly hair at 1 year with no family history of woolly hair. Initially her hair was noted to be short, fine and sparse over the entire scalp. At age 17 her hair was still short and fine in the frontoparietal and vertex regions (Fig. 1a), but thicker, longer, twisted, straighter and darker in the occipital region (Fig. 1b). The main concern of the parents was that the hair was still easy to pull from the scalp. A hair mount from the frontoparietal region showed that the hair had twisted bulbs and absent inner root sheaths and, as ruffled cuticles distal to the bulb were not seen, we sent some hairs for electron microscopic examination. This confirmed the presence of twisted anagen bulbs, loss of sheaths and ruffled cuticles.

DISCUSSION

When a patient presents with a history of easily extractable hairs or when this finding is demonstrated by the physician during a hair pull test it is necessary to examine the hairs using light microscopy. If easily extracted hairs have the characteristic features of twisted anagen bulbs, absent root sheaths and ruffled cuticles, then a diagnosis of loose anagen hair can be made. Ruffled cuticles may be absent if the pull test is done rapidly or if performed with dressing forceps.



(a)



(b)

Fig. 1. Woolly hair in a 17-year-old woman: (a) hair is very fine in texture, sparse and lightly pigmented in the frontoparietal region, allowing the scalp to be visible (woolly hair); (b) in the occipital region, hair is thicker, twisted, more darkly pigmented and can be easily pulled from the scalp (loose anagen hair).

The pathogenesis is probably related to the vacuolization of Huxley's layer, intercellular edema and dyskeratotic changes of Henle's cells (11, 13, 14). Cuticle cells of both the inner root sheath and the hair shaft also showed dyskeratotic changes. The structural abnormalities of the inner root sheath appeared to disturb the normal interdigitation between cuticle cells of the inner sheath and those of the hair shaft, altering the anchoring function of the inner sheath. Ultimately this alteration allows anagen hairs to be easily pulled out from the follicle.

REFERENCES

- Price VH The short anagen hair syndrome. 106th Annual Meeting of the American Dermatological Association, Inc. White Sulphur Springs, WV, 1986: 18 (Abstract).
- Nödl F, Zaun H, Zinn KH. Gesteigerte Epilierbarkeit von Anagenhaaren bei Kindern als Folge eines Reifungsdefekts der Follikel mit gestörter Verhaftung von Haarschaft und Wurzelscheiden. Das phänomen der leicht ausziehbaren Haare. *Akt Dermatol* 1986; 12: 55–57.
- Price VH, Gummer CL. Loose anagen hair. *J Am Acad Dermatol* 1989; 20: 249–256.
- Tosti A, Misciali C, Borello P, Fanti PA, Bardazzi F, Patrizi A. Loose anagen hair in child with Noonan's syndrome. *Dermatologica* 1991; 182: 247–249.
- Grimalt R, Barbareschi M, Manni S, Caputo R. Loose anagen hair of childhood: report of a case and review of the literature. *Eur J Dermatol* 1992; 2: 570–572.
- Martinez JA, Velasco M, Vilata JJ, Quecedo E, Aliaga A. Loose anagen syndrome: A new case. *Acta Derm Venereol* 1994; 74: 473.
- Camacho F, Gata I. Hypotrichosis and loose anagen hair in EEC syndrome. *Eur J Dermatol* 1995; 5: 300–302.
- Murphy MF, McGinnity FG, Allen GE. New familial association between ocular coloboma and loose anagen syndrome. *Clin Genet* 1995; 47: 214–216.
- Azon-Masoliver A, Ferrando J. Loose anagen hair in hypohidrotic ectodermal dysplasia. *Pediatr Dermatol* 1996; 13: 29–32.
- Boyer JD, Cobb MW, Sperling LC, Rushin JM. Loose anagen hair syndrome mimicking the uncombable hair syndrome. *Cutis* 1996; 57: 111–112.
- Chapman DM, Miller RA. An objective measurement of the anchoring strength of anagen hair in an adult with loose anagen hair syndrome. *J Cutan Pathol* 1996; 23: 288–292.
- Tosti A, Peluso AM, Misciali C, Ventura N, Patrizi A, Fanti A. Loose anagen hair. *Arch Dermatol* 1997; 133: 1089–1093.
- Uno H, Cappas A, Dong S, Price VH. Abnormal keratinization of the inner root sheath and cuticles of hair follicles in the scalp with "loose anagen syndrome". *J Invest Dermatol* 1989; 92: 536.
- Price V, Camacho F. Loose anagen syndrome. In: Camacho F, Montagna W, eds. *Trichology. Diseases of the pilosebaceous follicle*. Madrid: Grupo Aula Médica Ed. 1997: 397–402.

Accepted August 23, 2000.

María-José García-Hernández¹, Vera H. Price² and Francisco M. Camacho¹
 Departments of Dermatology, ¹Faculty of Medicine, Avda Dr Fedriani s/n, ES-41071, Seville, Spain and ²School of Medicine, University of California, San Francisco, California, USA.
 E-mail: camachodp@meditex.es

Leukotriene Inhibitor May Be Effective in Treatment of Psoriasis

Sir,

It is reasonable to suppose that a systemic inhibitor of leukotriene synthesis may inhibit the inflammatory process observed in psoriasis. Szmurlo (1) attempted to use a topical leukotriene inhibitor in the treatment of psoriasis but unfortunately the results were not encouraging. Nevertheless, other preliminary studies suggest that leukotriene inhibitors may be effective in the treatment of other skin diseases (2). Recently, two leukotriene inhibitors, zafirlukast and montelukast, have become available in the USA for the treatment of asthma. We report here a case where zafirlukast (Accolate[®]) induced improvement in a patient with psoriasis.

CASE REPORT

A 58-year-old woman with a long-standing history of severe psoriasis was recently diagnosed with systemic lupus erythematosus (SLE). Her psoriasis was initially controlled with PUVA treatments; however, they were later discontinued because of her SLE. The antinuclear antibody level was elevated at 1:640 with a homogenous pattern. The patient was administered prednisone by her rheumatologist; however, despite the use of moderate doses of the drug the psoriasis worsened. At the request of the primary care physician, skin biopsies were performed to confirm that the skin lesions were indeed psoriasis.

The patient completed a trial of topical calcipotriene, oral calcitriol and tazarotene gel without improvement. She was subsequently administered methotrexate 50 mg/week for several weeks. Following

an elevation in liver enzymes methotrexate was discontinued. At this time we decided to administer zafirlukast 20 mg b.i.d. Within 4 weeks, there was a dramatic improvement in the psoriasis. The patient tolerated zafirlukast without any side-effects. She maintained this regimen for over 2 years with satisfactory results. In the spring of 1998 the patient ran out of zafirlukast and, 2 months later, there was a severe flare-up of her psoriasis. Zafirlukast was restarted and the psoriasis resolved.

Zafirlukast was the primary therapy used to control this patient's psoriasis. Zafirlukast has been available in the USA for over 3 years and has an excellent safety profile, comparable to that of placebo (3).

REFERENCES

- Szmurlo A. Local use of leukotriene inhibitor-NDGA in psoriasis. *Przegl Dermatol* 1990; 77: 269–271.
- Iversen L, Kragballe K, Ziboh VA. Significance of leukotriene-A4 hydrolase in the pathogenesis of psoriasis. *Skin Pharmacol* 1997; 10: 169–177.
- Physicians desk reference, p. 536, 54th edn., Montvale (USA), Medical Economical Company, 2000.

Accepted 15 May 2000.

Alexander Zemtsov and Shelley Ali-Moncada
 University Dermatology Center, 2525 University Ave., Ste. 402,
 Muncie, IN 47303, USA.