

Absence of Azathioprine Hypersensitivity After Administration of its Active Metabolite 6-Mercaptopurine

Sir,

Urticarial vasculitis is a syndrome characterized by a chronic intermittent urticaria and the histological features of necrotizing vasculitis. The skin lesions are often accompanied by arthritis or arthralgia and other systemic diseases.

The use of immunosuppressive agents, such as cyclophosphamide and prednisolone, as drugs of choice is well established (1). Alternative therapy with azathioprine (AZA) has been described as beneficial in systemic vasculitis (2, 3).

We describe a case of hypersensitivity-like reaction after AZA. The administration of the AZA-metabolite 6-mercaptopurine (6-MP) did not induce allergic symptoms.

CASE REPORT

A 56-year-old woman with a 10-year history of chronic intermittent urticarial vasculitis with efflorescences characterized by granulocytes with concomitant arthralgia and cephalgia was first treated with oral AZA at a dosage of 100 mg/day for 10 days. Severe nausea and vomiting led to discontinuation of therapy. After an oral re-challenge 1 year later with the same agent, similar symptoms occurred.

Since resiquine, gold-preparations, corticosteroids and methotrexate were not effective, a second re-challenge with a single dose of 50 mg AZA applied intravenously was performed.

Immediately after the infusion the patient developed severe vomiting, fever and urticarial rash, with a decrease in blood pressure from 125/80 to 100/60 mmHg, followed by myalgia. Two days after cessation of therapy the symptoms disappeared.

Laboratory testing

Laboratory examinations showed leukocytosis with 19.2/nl white blood cells (lymphocytes 51%, eosinophils 6%). The level of the C-reactive protein was elevated (44.8 mg/l; normal range 0.07–8.2 mg/l). Immunoelectrophoresis revealed normal values for IgE with 0.2 g/l. Thiopurine-methyltransferase activity was determined and was apparently within the normal range (31 nmol 6-methyl-thioguanine/g Hb/h).

The concentration of the methylated intraerythrocytic metabolites of AZA in blood samples, collected 1 day after administration of AZA, did not exceed the detectable limits by much (26 pmol/8 × 10⁸ erythrocytes 24 h after i.v. application). At the same time the concentration of the metabolite 6-thioguanine came to 5 pmol/8 × 10⁸ erythrocytes.

Hypersensitivity testing

A prick test verified a strong hypersensitivity to AZA, but not to its active metabolite 6-MP. The scratch test showed a significant less intensive reaction to 6-MP compared with AZA.

Re-challenge with the active metabolite 6-MP

Therapy with 6-MP was started, with slightly increasing doses up to 300 mg daily. This regimen was well tolerated by the patient. Although the patient recovered from cephalgia, the remaining symptoms of vasculitis did not improve.

DISCUSSION

In this case treatment with AZA caused a hypersensitivity reaction, with gastrointestinal symptoms, fever, rash and hypotension. The probability of a drug-induced adverse drug effect was confirmed by a double re-challenge.

AZA undergoes thiol methylation in red blood cells, catalysed by the enzyme thiopurine-methyltransferase (TPMT) (4). Since neither decreased activity of TPMT nor elevated levels of AZA metabolites could be detected, we assume a hypersensitivity-like reaction. Typical for AZA-induced hypersensitivity reactions, symptoms occurred after several days upon first administration, following re-challenge the reaction developed rapidly due to sensitization (5). A similar case has been reported by Riedel et al. (6), whereby a pronounced eosinophilia was observed in the duodenal biopsy, but not in the peripheral blood cell count. Severe hypotension, which occurs in about two-third of patients after re-challenge of AZA, is presumed to be cytokine-mediated (7).

A positive re-challenge 1 year after the last administration of AZA is in accordance with the literature, where hypersensitivity reactions are described up to 7 years following first dosage of the drug (5, 7).

Whereas adverse reactions, such as fever, gastrointestinal symptoms, affections of the skin, liver and renal damage and neuropathy, are frequently reported for AZA (5–7), few cases of hypersensitivity-like reactions are described following administration of its metabolite 6-MP (8). Only 3 cases with application of 6-MP following hypersensitivity to AZA are reported in the literature: 2 patients revealed no, or a less intensive, adverse reaction (9, 10), 1 patient showed no difference in hypersensitivity (11).

As the patient showed a severe adverse reaction to AZA, but not to its active metabolite 6-MP, we suggest that the imidazole side-chain was the immunoreactive compound of azathioprine for this patient (9).

Continuation of therapy with the active metabolite 6-MP should be considered after skin testing for hypersensitivity, when a successful treatment with AZA has to be interrupted after severe allergic reactions.

REFERENCES

1. Asherson RA, D'Cruz D, Stephens CJ, McKee PH, Hughes GR. Urticarial vasculitis in a connective disease clinic: patterns, presentations, and treatment. *Semin Arthritis Rheum* 1991; 20: 285–296.
2. Berlit P. Vasculitis. *Ther Umsch* 1996; 53: 559–567.
3. McCune WJ, Friedman AW. Immunosuppressive drug therapy for rheumatic disease. *Curr Opin Rheumatol* 1992; 4: 314–321.
4. Lennard L. The clinical pharmacology of 6-mercaptopurine. *Eur J Clin Pharmacol* 1992; 43: 329–339.
5. Fields CL, Robinson JW, Roy TM, Ossori MA, Byrd RP Jr. Hypersensitivity reaction to azathioprine. *South Med J* 1998; 91: 471–474.
6. Riedel RR, Schmitt A, de Jonge JPA, Hartmann A. Gastrointestinal type I hypersensitivity to azathioprine. *Klin Wochenschr* 1990; 68: 50–52.
7. Knowles SR, Gupta AK, Shear NH, Sauder D. Azathioprine

- hypersensitivity-like reactions — a case report and a review of the literature. *Clin Exp Dermatol* 1995; 20: 353–356.
8. Present DH, Meltzer SJ, Krumholz MP, Wolke A, Korelitz BI. 6-Mercaptopurine in the management of inflammatory bowel disease: short- and long-term toxicity. *Ann Intern Med* 1989; 111: 641–649.
 9. Godeau B, Paul M, Autegarden JE, Leynadier F, Astier A, Schaeffer A. Hypersensitivity to azathioprine mimicking gastroenteritis. Absence of recurrence with 6-mercaptopurine. *Gastroenterol Clin Biol* 1995; 19: 117–119.
 10. Davis M, Eddlestone AL, Williams R. Hypersensitivity and jaundice due to azathioprine. *Postgrad Med J* 1980; 56: 274–275.

11. Farthing M, Coxon A, Sheaff P. Polyneuritis associated with azathioprine reaction. *BMJ* 1980; 280: 367.

Accepted October 18, 1999.

Klaus Schmitt¹, Uli Pfeiffer², Helmut E. Stiehrle² and Petra A. Thuermann¹

¹Philipp Klee-Institute of Clinical Pharmacology, Klinikum Wuppertal GmbH, University of Witten/Herdecke, Arrenberger Str. 20, D-42117, Wuppertal, Germany and ²Department of Medicine, St. Josephs-Hospital, Wuppertal, Germany.
schmitt@klinikum-wuppertal.de

Aquagenic Urticaria: A Case Report

Sir,

Aquagenic urticaria is a rare form of physical urticaria, characterized by small follicular wheals, with an erythematous halo upon exposure to aqueous solutions. We describe here a case of this disorder, whose lesions were maximally reproduced by a combination of pretreatment with acetone and contact with saline.

CASE REPORT

A non-atopic 19-year-old man had noticed the development of small wheals accompanied by itching when he took bath. This reaction had occurred since the age of 13 years. The wheals also appeared when he got wet in the rain, went swimming, or sweated. They disappeared spontaneously about 30 min later. More wheals were induced by seawater than by tap water, and by hot water than cold water, but the wheals failed to appear upon exposure to sunlight or cold air. No enhanced dermographic reaction was observed. A general physical examination showed no abnormal findings. No similar episode has been observed in his family.

Laboratory investigations, including complete blood cell count, liver and renal function tests, serum protein electrophoresis, immunoglobulins (IgG, A, M, and E), serum complement components of C3 and C4, anti-nuclear antibody and serological test for syphilis, were all negative or within normal limits. Serum and whole blood histamine concentrations were 4.7 nM and 34.0 ng/ml, measured by enzyme immunoassay (Immunotech, Marseille, France) and HPLC, respectively. Skin tests showed a somewhat large erythema for 0.2 µg histamine (50 × 30 mm), but no exaggerated reaction was observed with physiological saline (1 × 1 mm).

The immersion of his forearm in tap water at 35°C for 15 min caused the development of 2 small erythemas with itching. Consequently, 4 conditions of aqueous challenges were applied to his back at room temperature. Sites 1–3 were directly challenged by compresses with distilled water (site 1), 99.5% ethanol (site 2) and 5% saline (site 3), respectively. Site 4 was wiped with a compress with acetone, then applied with 5% saline. After 15 min, when the compresses were removed, 3 pinhead-sized wheals were observed, corresponding to hair follicles at site 4 (Fig. 1a). After a further 15 min, additional wheals appeared especially at site 4 (Fig. 1b). No eruption or itching was induced at sites 1 and 2.

Oral anti-histamines, terfenadine 60 mg and mequitazine 6 mg per day partially reduced the symptoms. This combination, with topical application of 1% diphenhydramine ointment, prevented further wheal formation to some extent.

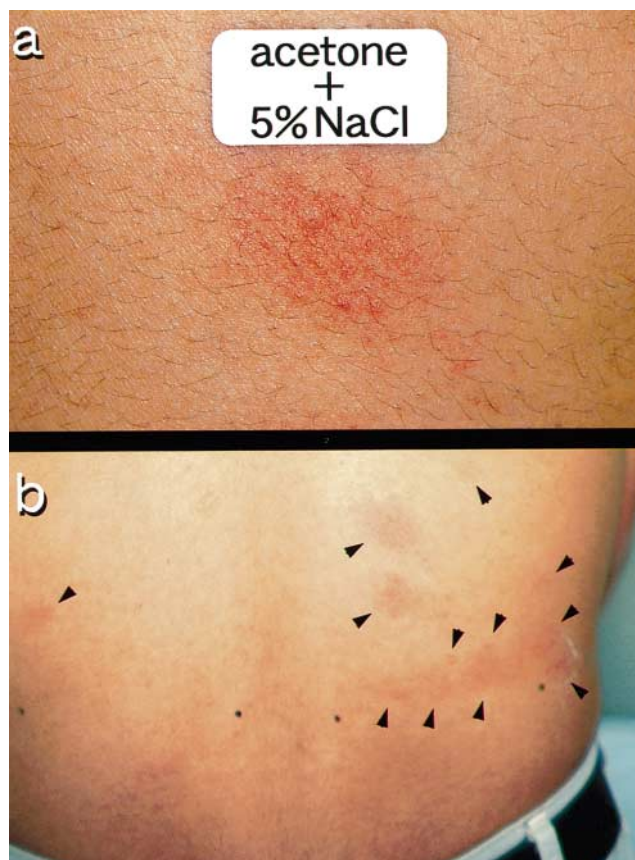


Fig. 1. Wheal-and-flare reactions induced by contact with 5% saline on the back. (a) After 15 min a wheal with flare appeared at a hair follicle. (b) After 30 min acetone pretreatment induced more wheals and flares (site 4, right) than control (site 3, left).