

An Intensely Pruritic Eruption on the Back Occurring after Stopping Dieting

Sir,

Dieting to reduce weight for cosmetic reasons is popular, especially among women. We report here the case of a Japanese woman who developed an intensely pruritic eruption on her back, concomitantly with a modest weight gain that occurred after she had stopped dieting. While topical corticosteroids were not effective in our case, systemic antibiotics, namely cefdinir and minocycline, produced excellent effects. To our knowledge, such a case has not previously been described.

CASE REPORT

A 42-year-old woman was referred to our clinic on 17 December 1997, with a 1-month history of an intensely pruritic eruption on her upper back. She had been treated by her general practitioner with topical clobetasol propionate and gentamicin sulphate for 2 weeks, but the eruption gradually spread. She was slightly obese, weighing 50 kg. She had started a low-calorie diet in spring 1997 for aesthetic reasons, and lost 3 kg slowly. She stopped dieting at the beginning of November and her weight increased rapidly, returning to the pre-diet level within a month. She had had acne on the face and trunk in her teenage years and a low-grade acneform eruption had continued into her 40s. On examination, irregular, confluent, erythematous plaques with small crusted erosions were present on the upper back. In addition, 1–2 mm diameter, reddish papules were found scattered on and close to the erythematous lesions (Fig. 1). The skin of the face and upper trunk showed seborrhoea. A skin biopsy taken from a solitary papule revealed that a hair follicle was located in the centre. There was a mononuclear cell infiltrate not only in the vicinity of the hair follicle, but also in the follicular wall with spongiosis (Fig. 2). The epidermis outside the hair follicle showed mild acanthosis, exocytosis of lymphoid cells, liquefaction degeneration of the basal cells and scattered apoptotic keratinocytes. There was no evidence of amyloid or mucin deposition in the dermis. Direct immunofluorescence studies gave negative results. A culture of exudate from the erosions yielded *Staphylococcus aureus*. The results of the following laboratory tests were within normal limits: complete blood count,

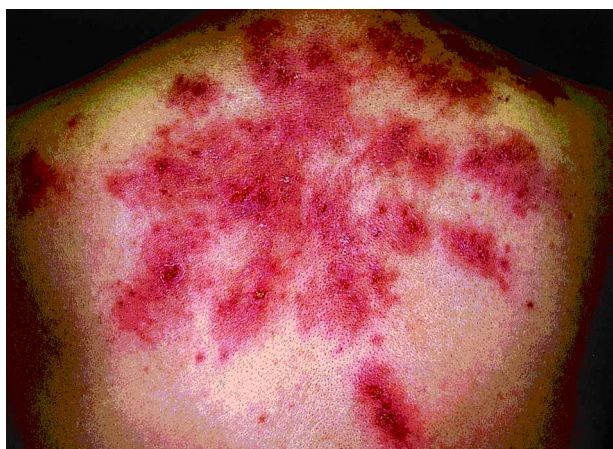

Fig. 1. Irregular, confluent, erythematous plaques with small crusted erosions present on the upper back. Reddish papules (1–2 mm diameter) are seen scattered on and close to the erythematous lesions.

urinalysis, liver function, serum creatinine, serum protein electrophoresis, IgG, IgA and IgM. Urine was negative for ketones.

The patient was told to stop using the topical medications given to her by the general practitioner, because contact allergy to them could not be excluded on the basis of the course of the disease. Although she followed this instruction for 1 week, there was no significant improvement. Despite administering topical diflucortolone valerate for 2 weeks the eruption showed gradual exacerbation. Patch testing with all topical medications used up to this point (clobetasol propionate, gentamicin sulphate and diflucortolone valerate) revealed negative reactions, even though we made observations for 7 days in order to avoid missing delayed reactions. As a trial, we administered 100 mg of the cephalosporin cefdinir (Fujisawa Pharmaceutical Co., Ltd.) three times daily, which produced significant effects within 1 week. However, after cefdinir was discontinued, the eruption and severe pruritus rapidly recurred. Subsequently, 100 mg of minocycline daily was given, resulting in a complete cure of the rash within about 3 weeks, leaving a mottled pigmentation. After stopping minocycline, there has been no sign of a relapse for about 2 years.

DISCUSSION

At first, contact dermatitis was suspected in this case on clinical grounds. However, topical steroids produced no

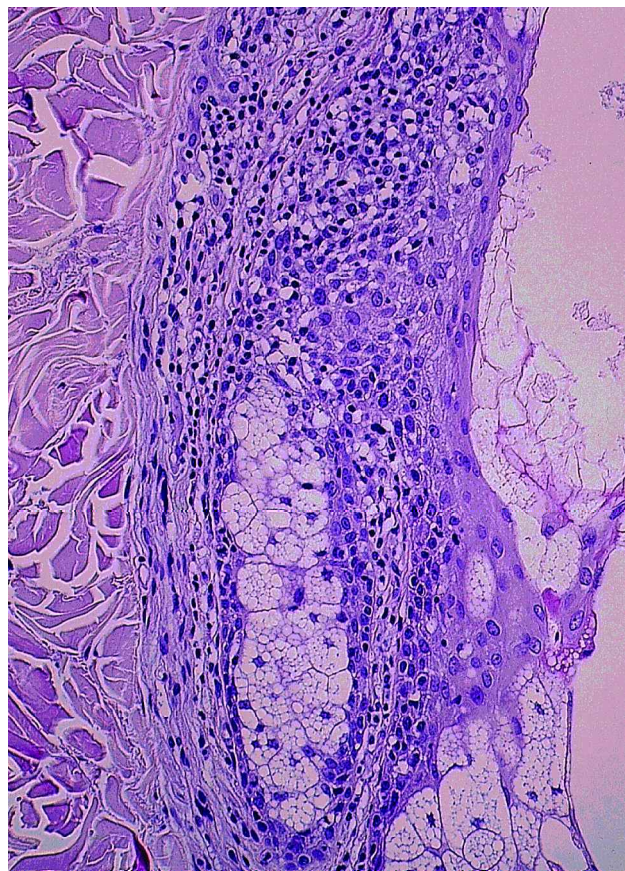


Fig. 2. A mononuclear cell infiltrate is seen not only in the vicinity of a hair follicle, but also in the follicular wall with spongiosis. Haematoxylin and eosin staining; original magnification $\times 50$.

effects, and the results of patch testing with all the topical medications used were all negative. It seems likely that the primary event in the inflammatory cascade, leading to the development of the unique conditions in our patient, might have occurred in the hair follicles, as histopathology from a solitary papule revealed that a hair follicle was located in the centre. Such histological findings also argue against the diagnosis of contact dermatitis. A rather bizarre morphology of the eruption might be accounted for, to some extent, by scratching resulting from intense pruritus. However, dermatitis artefacta could be excluded in our patient, because the papular lesions which revealed the characteristic histological features are not seen in dermatitis artefacta. Impetigo might be considered in the differential diagnosis, because a bacterial culture of exudate yielded *S. aureus* and systemic antimicrobials produced excellent effects. However, the clinical picture and histology are quite different from those of impetigo.

Nummular eczema should also be included in the differential diagnosis, because it often shows a poor response to topical corticosteroids but reacts favourably to systemic antibiotics (1). However, histopathological findings in this case argue against the diagnosis of nummular eczema. Pityrosporal folliculitis involves follicles, and is often localized on the back. However, the plaque lesions seen in our patient are not a feature of this condition (2).

Prurigo pigmentosa, as first described by Nagashima (3), is characterized by recurrent pruritic erythematous papules that subside in about 1 week, leaving a peculiar, reticulate hyperpigmentation. The sites of predilection are the anterior chest, back, clavicular, scapular and nuchal regions. The histological picture is characterized by a lichenoid tissue reaction with a mild degree of spongiosis, intracellular oedema and exocytosis. Treatment with dapson or minocycline is extremely effective, whereas the response to topical and systemic corticosteroids is poor. The cause of prurigo pigmentosa remains obscure, although it was recently suggested that ketosis associated with fasting, dieting and insulin-dependent diabetes mellitus may play a significant role (4). Our case has some resemblance to prurigo pigmentosa, as the pruritic eruption on the patient's back was successfully treated with minocycline, leaving a pigmentation, and the histological changes in the area outside a hair follicle resemble those of this condition. However, our case seems to be distinct from this entity because the lesions were persistent, and consisted mainly of confluent, erythematous plaques. Further-

more, the patient developed eruption concomitantly with the rapid weight gain that occurred after stopping dieting, in contrast to prurigo pigmentosa in which the onset is often associated with fasting or dieting.

It seems unlikely that systemic antibiotics were efficacious in our case through their activity against *S. aureus* because, as mentioned above, the clinical picture and histology were quite different from those of staphylococcal skin infections such as impetigo. A possible explanation for the efficacy of the antibiotics is that they may have suppressed the normal resident flora on the skin, thus having a favourable effect on the course of the disease. In addition, minocycline may produce an excellent result through its unique, inhibitory effects on the immunological system (5).

To our knowledge, such a case has not previously been described in the literature. The cause is unknown but we can speculate that, in this case, the eruption occurred as a result of the metabolic response to a rapid weight gain after stopping dieting. High sebum secretion may have been an important precipitating factor. In addition, psychological factors, such as disappointment and frustration that the attempt to reduce weight had failed, might have been involved in the aetiology of the condition.

REFERENCES

1. Burton JL. Discoid eczema. In: Champion RH, Burton JL, Ebling FJG, eds. *Textbook of dermatology*, 5th edn., Vol. 1. Oxford: Blackwell Scientific, 1992: 555–557.
2. Bäck O, Faergemann J, Hornqvist R. Pityrosporum folliculitis: a common disease of the young and middle-aged. *J Am Acad Dermatol* 1985; 12: 56–61.
3. Nagashima M. Prurigo pigmentosa—clinical observations of our 14 cases. *J Dermatol* 1978; 5: 61–67.
4. Teraki Y, Teraki E, Kawashima M, Nagashima M, Shiohara T. Ketosis is involved in the origin of prurigo pigmentosa. *J Am Acad Dermatol* 1996; 34: 509–511.
5. Humbert P, Treffel P, Capuis J-F, Buchet S, Derancourt C, Agache P. The tetracyclines in dermatology. *J Am Acad Dermatol* 1991; 25: 691–697.

Accepted September 27, 2000.

Kazuhiro Hayakawa and Tetsuo Shiohara
Department of Dermatology, Kyorin University School of Medicine,
6-20-2 Shinkawa, Mitaka, Tokyo 181-8611, Japan.