

## INVESTIGATIVE REPORT

# Modulation of Urokinase-type and Tissue-type Plasminogen Activator Occurs at an Early Stage of Progressing Stages of Chronic Venous Insufficiency

MANFRED PESCHEN<sup>1</sup>, ALAN A. ROGERS<sup>2</sup>, W. Y. JOHN CHEN<sup>2</sup> and WOLFGANG VANSCHIEDT<sup>1</sup>

<sup>1</sup>Department of Dermatology, University of Freiburg, Germany and <sup>2</sup>Convatec Wound Healing Research Institute, Flintshire, UK

Chronic venous insufficiency (CVI) progresses through a series of clinical stages, from healthy skin to poorly healing leg ulcers. The aim of this study was to analyse the distribution pattern and activity level of urokinase-type (uPA) and tissue-type plasminogen activators (tPA) in normal skin and in tissue biopsies of progressing stages of CVI, prior to and including venous ulceration. Biopsies 6 mm thick were taken from 14 healthy volunteers and 37 patients with 5 different stages of CVI: telangiectases; stasis dermatitis; hyperpigmentation; lipodermatosclerosis; and leg ulcer. Changes in the enzymatic activity and spatial localization of uPA and tPA during the progression of CVI were examined using *in situ* histological zymography. Normal skin and skin with telangiectases showed a punctate PA activity, consisting of both uPA and tPA activity. As CVI progressed, an increase in the distribution of uPA and a decrease in tPA activity was observed. The spatial localization of uPA was widespread within the dermis of biopsies from stasis dermatitis and lipodermatosclerosis and was associated in particular with the dermoepidermal junction. Hyperpigmented skin revealed a pattern of PA expression similar to that of healthy skin. However, leg ulcer specimens exhibited peak levels of uPA with little tPA. Furthermore, a plasminogen-independent protease activity that was not present in any of the earlier stages of CVI appeared. Our results indicate that there are profound changes in PA activity during the progression of CVI and that these changes begin early in CVI, for example, in stasis dermatitis. We hypothesize that the balance or imbalance of the PA activity in the later stages of CVI is an important pathogenic factor for the development of venous leg ulcer. **Key words:** phlebology; microcirculation; plasminogen activator.

(Accepted December 15, 1999.)

Acta Derm Venereol 2000; 80: 162–166.

Manfred Peschen, Department of Dermatology, University of Freiburg, Hauptstr. 7, D-79104, Freiburg, Germany. E-mail: Peschen@haut.ukl.uni-freiburg.de

Progress in research into the pathophysiological stages of chronic venous insufficiency (CVI) due to ambulatory venous hypertension, leading from healthy skin through various clinical stages, such as telangiectases, stasis dermatitis, hyperpigmentation and lipodermatosclerosis to poorly healing venous leg ulcers, have focused recently on changes in the microcirculation (1–3). These changes are accompanied by a complex interaction of cytokines, growth factors, adhesion molecules, proteins of the extracellular matrix and various proteases, which seem to be stage-dependently disturbed in CVI, compared with in normal skin (3–9).

Recent observations of the protein and mRNA levels of late stages of CVI, such as lipodermatosclerosis and leg ulceration, have described an imbalance of matrix metalloproteinases (MMPs) and their tissue inhibitors (TIMPs), possibly contributing to a breakdown of the extracellular matrix and formation of ulcers (9, 10).

Moreover, the well-known altered fibrinolytic activity in patients with CVI contributes to an increased activation of the plasminogen activator/plasmin system, which has been implicated in such diverse processes as angiogenesis, inflammatory reaction, wound healing and the control and activation of MMPs (11, 12). Although the localization of, for example, MMPs, TIMPs and other proteases by PCR, *in situ* hybridization or immunohistochemical techniques is important and useful for the understanding of the pathology of CVI, these techniques do not address the question “it may be there, but is it active?”

Plasminogen activators (PAs) are another important, endogenously produced, class of proteases that have been studied recently in chronic wounds (11, 13, 14). The aim of this investigation was therefore to determine the distribution pattern and activity level of the plasminogen activators uPA and tPA by *in situ* zymography in progressing stages of CVI, and to define their role in the development of CVI.

## MATERIAL AND METHODS

### Patients

The study group comprised 14 healthy volunteers (average age 52.8 years, age range 32–69 years, 7 females and 7 males) and 37 patients with 5 different clinical stages of CVI (mean age 60.3 years, age range 29–87 years, 25 females and 12 males), according to the severity of skin changes ascribed to venous disease (15). Doppler-sonography and photoplethysmography confirmed the clinical classification of CVI, which is based on a classification system that takes into account clinical signs (C), aetiology (E), anatomical distribution (A) and pathophysiological dysfunction (P), as described previously (CEAP classification) (16). A concomitant arteriosclerosis of the extremities was excluded by an ankle-brachial index >0.9. Six millimetre skin punch biopsies from clinically affected skin of the lower limb were taken under local anaesthesia (1% Scandicain) with primary wound closure, following informed consent from all subjects included in the study. All patients were informed about the risk of the biopsy inducing an ulcer. No patient developed an ulcer during the 3-month follow-up period. The biopsies from controls were site-matched relative to patient biopsies. Patients were assigned to one of six of the clinical stages of CVI, which were defined as follows: telangiectases (6 patients); stasis dermatitis (6 patients); hyperpigmentation (6 patients); lipodermatosclerosis (7 patients); and venous leg ulcer (12 patients) (15). Patients with leg ulcers were divided into 2 groups, each consisting of 6 patients; in one group biopsies were taken from

the leg ulcer margin, containing both adjacent skin and ulcer base tissue and in the other group biopsies were obtained from the leg ulcer base only. Immediately after biopsy, specimens were snap frozen in liquid nitrogen and stored at  $-80^{\circ}\text{C}$  until further processing.

#### *In situ* zymography.

Plasminogen activator (PA) activity in unfixed frozen sections was assessed by *in situ* histological zymography, performed according to the method of Sappino et al. (17), with modifications (11). Ten  $\mu\text{m}$  thick sections were mounted on clean glass slides, allowed to dry at room temperature and stored at  $-20^{\circ}\text{C}$  until use. This technique is based on the principle that the endogenous PAs are detected by an overlay, which contains plasminogen (the substrate for the endogenous PAs) and casein (a substrate for plasmin). Endogenous PA activity will convert the plasminogen in the overlay to plasmin (a general protease), which will degrade the casein and can be viewed experimentally. Therefore, an overlay mixture for the detection of PA activity, containing 5% (w/v) commercially available non-fat dry milk powder (Marvel<sup>®</sup>, Premier Beverages, Stafford, UK), 1% (w/v) agar (Bio-Rad Laboratories, Hercules, CA, USA) and 0.03 mg/ml human plasminogen (Quadrachem, Epsom, UK), was prepared and maintained at approximately  $50^{\circ}\text{C}$  prior to use. This overlay was applied evenly over the biopsy sections, which had been pre-warmed to approximately  $40^{\circ}\text{C}$  on a heated platform. The section and added overlay were covered with  $22 \times 22$  mm square glass cover slips to provide an overlay of even thickness and then were transferred briefly to a cold surface to allow the overlay to set. The slides were incubated at  $37^{\circ}\text{C}$  in humid chambers for 3–6 h to allow the zymograms to develop. To detect tPA activity, the plasminogen activator inhibitor amiloride (Sigma Chemicals Ltd, Poole, UK) (18) was added (200  $\mu\text{l}$  10 mmol/l) to the overlay. Control slide overlay gels contained no plasminogen. Photomicrographs (FP4 (125 ASA) film) were taken using dark field illumination (Nikon F-301 35 mm SLR camera system).

#### *Semiquantitative evaluation of plasminogen-dependent and -independent protease activity.*

Two independent double-blind investigators scored the profile of protease activity and the spatial localization in the skin biopsies. Activity was based on the extent of degradation of the overlay, i.e. the level of black seen in the section, as described previously (14). This can therefore be only a semiquantitative assessment, the more the activity the more the "blackness" of the section. For the semiquantitative evaluation, 6 serial sections per patient biopsy were scored, i.e. 2 sections for total PA activity, 2 for tPA activity and 2 for the non-plasminogen-dependent activity; thus each sample was examined in duplicate. A series of 3 consecutive sections were used for the total tPA and non-plasminogen-dependent protease activity.

The second, duplicate series was the 4th, 5th and 6th section of the biopsy. The occurrence of the main classes of enzyme activity was analysed, expressed as a ratio of patients showing enzyme activity in each stage compared with the total number of patients investigated at each clinical stage.

## RESULTS

Table I summarizes the protease activity profiles for all biopsies in progressing stages of CVI, and representative examples of the distribution patterns for the various stages are seen in Fig. 1. In normal skin, PA activity appeared predominantly as a punctate activity in the papillary layer of dermis (Fig. 1A). Amiloride-containing overlays, representing the tPA activity, showed a decreased punctate activity (Fig. 1B). Control slides showed no non-plasminogen-dependent protease activity in normal skin (Fig. 1C).

Specimens of telangiectases again showed a distribution pattern of PA activity in the dermis, which was similar to that of healthy skin (Fig. 1A). Amiloride-exposed slides showed punctate tPA activity (5/6 patients) (Fig. 1B, Table I). The activity level of both uPA and tPA appeared to be decreased in comparison with normal skin. As with normal skin, no non-plasminogen-dependent activity was observed at this stage of CVI (Fig. 1C).

The CVI stage described as stasis dermatitis exhibited some punctate PA activity plus the appearance of a uniform activity (Fig. 1A), which appeared to be associated with the dermoepidermal junction. In the presence of amiloride the majority of this activity was inhibited suggesting that there was a reduced level of tPA activity (Fig. 1B) compared with normal skin. These biopsies, as with previous stages of CVI, exhibited no protease activity in the absence of plasminogen (Fig. 1C).

Biopsies from patients with hyperpigmentation showed a mostly punctate PA activity throughout the dermis (Fig. 1A), which was similar to the pattern of activity seen in healthy skin and patients with telangiectases. In particular, punctate tPA activity was present (Fig. 1B). No non-plasminogen-dependent activity was detected (Fig. 1C).

In lipodermatosclerosis, there appeared to be both a punctate and uniform distribution of PA activity (Fig. 1A). As with stasis dermatitis biopsies, a uniform band of PA activity was detected at the dermoepidermal junction region (Fig. 1A), which was inhibited by amiloride (Fig. 1B), suggesting that this activity was uPA. Activity not inhibited

Table I. The occurrence of protease activity, expressed as a ratio of patients showing activity, compared with the total number of patients investigated at each clinical stage ( $n$ =number of patients)

CVI-stage	Total plasminogen activator activity	tPA activity (without uPA activity)	Non-plasminogen-dependent protease activity
Normal skin ( $n=14$ )	14/14	14/14	0/14
Telangiectases ( $n=6$ )	5/6	5/6	0/6
Stasis dermatitis ( $n=6$ )	6/6	1/6	0/6
Hyperpigmentation ( $n=6$ )	6/6	4/6	0/6
Lipodermatosclerosis ( $n=7$ )	7/7	2/7	0/7
Leg ulcer base ( $n=6$ )	6/6	6/6	6/6
Leg ulcer margin ( $n=6$ )	6/6	4/6	3/6

CVI=chronic venous insufficiency; tPA=tissue-type plasminogen activator; uPA=urokinase type plasminogen activator.

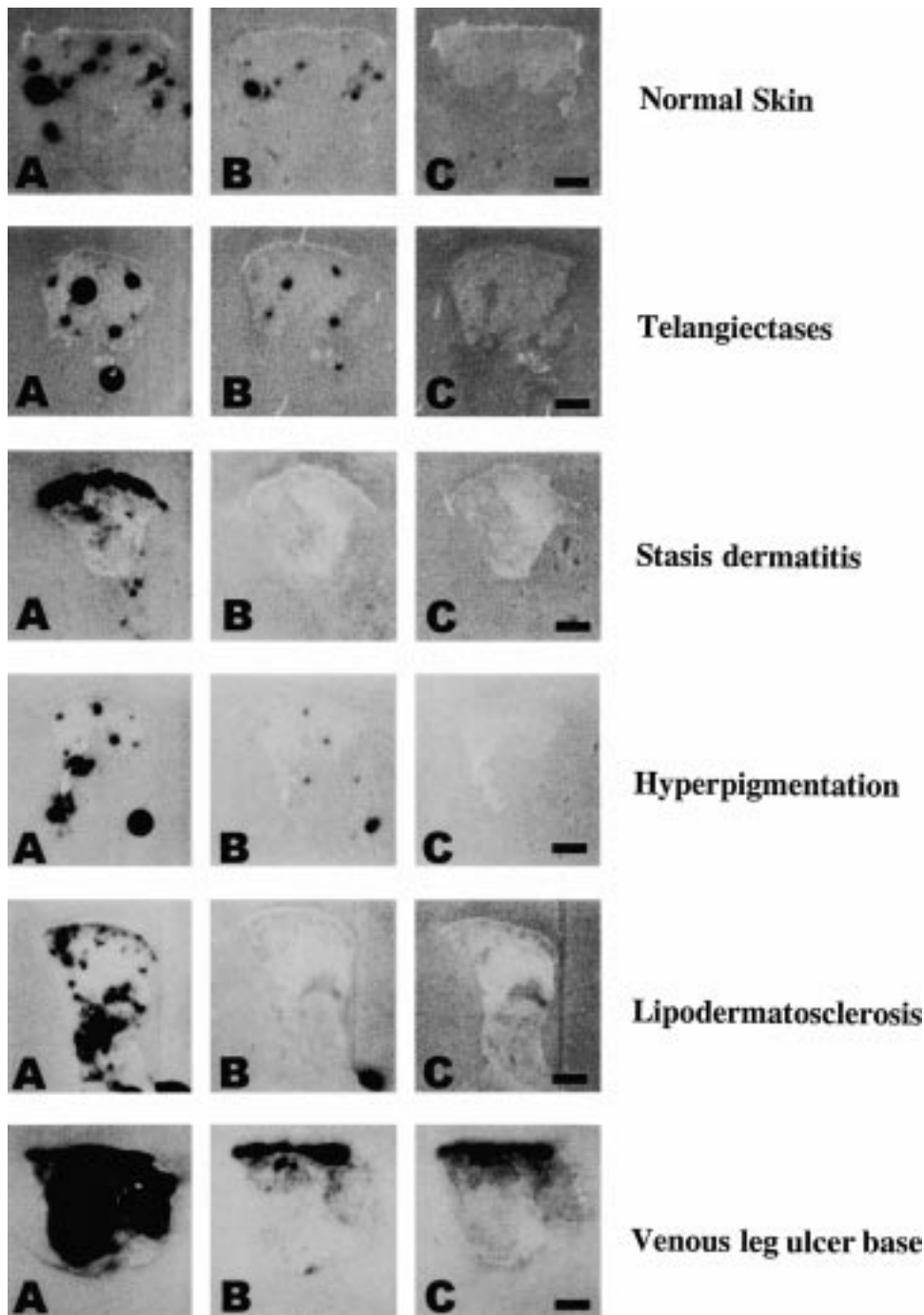


Fig. 1. The spatial localization and activity level of urokinase-type- (uPA) and tissue-type- plasminogen activator (tPA) shows an early change in chronic venous insufficiency (e.g. stasis dermatitis) and marked changes in the later stages of lipodermatosclerosis and venous leg ulcer. Distribution pattern and activity level of uPA and tPA and non-plasminogen-dependent proteases in normal skin ( $n=14$ ) and progressing stages of CVI, such as telangiectases ( $n=6$ ), stasis dermatitis ( $n=6$ ), hyperpigmentation ( $n=6$ ), lipodermatosclerosis ( $n=7$ ) and leg ulcer base ( $n=6$ ). Cryosections of skin samples incubated with plasminogen-containing casein-agar overlay, showing total PA activity (A for each stage), plasminogen-containing casein-agar overlay with the addition of amiloride (uPA inhibitor) showing total PA activity without urokinase activity (B for each stage) and plasminogen-deficient casein-agar overlay (control), revealing plasminogen-independent activity (C for each stage) were analysed by *in situ* histological zymography, as described in the material and methods section (scale bar = 1 mm).

by amiloride was detected in the deep tissue (Fig. 1B), however there was little of this activity in the upper dermis. As with normal skin biopsies and all previous stages of CVI, no non-plasminogen-dependent protease activity could be detected (Fig. 1C).

Specimens from the base of the venous leg ulcer revealed an increased level of protease activity throughout the tissue (Fig. 1A). Most of this activity was inhibited by amiloride (Fig. 1B). The majority of the remaining activity (Fig. 1B) was associated with the upper ulcer granulation tissue and was not inhibited by the absence of plasminogen, suggesting that this activity is plasminogen-independent (Fig. 1C).

Biopsies of leg ulcer margin presented a mixed pattern of PA activity, which reflected whether the specimen contained ulcer base or adjacent skin tissue. In the case of adjacent skin tissue (3/6), these biopsies showed an increased uniform or diffuse activity at all levels of the tissue similar to the pattern seen in lipodermatosclerosis. A large proportion of this activity could be inhibited by amiloride, indicating the presence of uPA. No non-plasminogen-dependent protease activity was detected in these biopsies of the ulcer margin tissue (data not shown). The remainder of the ulcer margin biopsies (3/6), presenting leg ulcer base tissue exhibited a pattern similar to the ulcer base biopsies.

## DISCUSSION

In this study we demonstrate that: (i) there are profound changes in the activity and spatial localization of both uPA and tPA during the progression of CVI; (ii) these changes begin early in CVI (e.g. stasis dermatitis); and (iii) the most striking changes in uPA and tPA activity occurs in the later stages of CVI, namely, lipodermatosclerosis and leg ulceration.

uPA and tPA are specific proteases at the top of the protease cascade in the conversion of the zymogen plasminogen to active plasmin, a general protease involved in the proteolysis of pericellular glycoproteins (19). uPA bound to a specific cellular receptor is involved in tissue remodelling processes and cell matrix interactions that are important in wound healing (20, 21). tPA, which is stored in endothelial cells, can be released acutely in the blood vessel lumen upon stimulation of the endothelium, stimulating fibrinolysis and preventing fibrin deposition (21).

Our *in situ* zymography results for normal skin and the earliest stage of CVI, clinically defined as telangiectases, show in accordance to previous studies that both uPA and tPA contributes to the total PA activity in normal skin (14, 22). Our studies provide evidence that, *in situ*, both these PAs are physiologically active. The punctate distribution pattern suggests blood vessel association of the PA activity. In the case of tPA, this activity is necessary for blood vessel patency (21).

Previous reports suggest that, in the inflammatory stage of stasis dermatitis, profound changes in the complex cascade of cytokines, adhesion molecules and growth factors take place (3). *In vitro* experiments showed that pro-inflammatory cytokines, such as tumour necrosis factor- $\alpha$  and interleukin-1 $\beta$  induce a co-ordinated increase in uPA expression in keratinocytes with an increased pericellular plasmin-mediated proteolysis (23). Recently, we could show by immunofluorescence investigation of the extracellular matrix components laminin, fibronectin and tenascin, that increased fragmentation of the extracellular matrix could be seen first in biopsies from stasis dermatitis patients (24). Fibronectin fragments induce the expression of specific proteases, such as MMPs (25). Chronic wounds also contain elevated levels of MMPs (26, 27), and it has been shown that uPA is a major controller of MMP activation (28).

In comparison with normal skin and stasis dermatitis, our PA analysis suggests that biopsies of hyperpigmented skin may represent a "resting phase" in CVI, and is thus in agreement with other investigations studying growth factor and cytokeratin expression in hyperpigmented skin of CVI (5–7). We hypothesize that in the stage of hyperpigmentation, the most important region for the progressing pathophysiological changes is not in the overlying skin, but in the deeper layers of the skin, e.g. muscles, tendons and bones (29, 30).

Our results show a marked change in the distribution of PA activity in lipodermatosclerosis, clinically characterized by a strong level of fibroblast activation, which is in accordance with an increased platelet-derived growth factor expression, resulting in fibrosis and sclerosis of all structures of the affected area (7, 30, 31). *In vitro* studies have shown a promotive effect of this growth factor on the migration of human fibroblasts on titanium surfaces, which was correlated with the release of uPA from fibroblasts (32).

Reduced endothelial cell tPA activity is suggested as a major cause of decreased fibrinolytic activity in impaired wound healing and our results for venous leg ulcers clearly show a reduction in blood vessel-associated tPA activity (14). The expression of uPA is confined to the proliferative population of keratinocytes during epidermal wound healing, rather than to keratinocytes of the normal epidermis (23, 33), suggesting that the change in uPA activity at the dermo-epidermal junction in leg ulcer patients may stimulate the proliferation of the overlying keratinocytes (5, 13). Additionally, the enzymatic effect of uPA and the activation of plasmin may provide an environment that is more migratory for keratinocytes, thus inducing re-epithelialization (34). It has been shown by *in situ* hybridization that in poorly healing wounds, such as venous ulcers, uPA is expressed in keratinocytes (33). However, it may be that the degradative effects of high uPA activity levels are more important than the stimulatory effects of uPA on keratinocyte migration.

Previous studies have shown the presence of a non-plasminogen-dependent protease activity that appears specific for chronic ulcers, including pressure ulcers (11) and venous ulcers (14). This activity has not been detected in normal skin (11) or acute wounds (20). Results presented here confirm the presence of a non-plasminogen-dependent protease activity (9) and extend the data on this activity by showing that this activity does not appear until ulceration has occurred; it is not present in earlier stages of CVI.

We hypothesize that the balance or imbalance of the PA activity in the later stages of CVI is a central pathogenic factor for the development of venous leg ulceration. Overall, the down-regulation of uPA and tPA appears to be an important event in epidermal healing and restoration of a normal epidermal tissue structure (35).

## ACKNOWLEDGEMENTS

We thank Drs A. Glöggler and J. Hutchinson for providing technical assistance regarding the collaboration between both research centres involved in this study.

## REFERENCES

1. Bollinger A, Leu AJ, Hoffmann U, Franzeck UK. Microvascular changes in venous disease: an update. *Angiology* 1997; 48: 27–32.
2. Shami SK, Sarin S, Scurr JH. Chronic venous insufficiency disease. *Int J Angiol* 1997; 6: 30–48.
3. Peschen M, Vanscheidt W. Immunohistochemistry and molecular biology of skin with chronic venous insufficiency and venous ulceration. *Prog Appl Microcirc* 1999; 23: 165–179.
4. Weyl A, Vanscheidt W, Weiss JM, Peschen M, Schoepf E, Simon J, et al. Expression of the adhesion molecules ICAM-1, VCAM-1, and E-selectin and their ligands VLA-4 and LFA-1 in chronic venous leg ulcers. *J Am Acad Dermatol* 1996; 34: 418–423.
5. Peschen M, Grenz H, Lahaye T, Brand-Saberi B, Simon JC, Schoepf E, et al. Changes of cytokeratin expression in the epidermis with chronic venous insufficiency. *Vasa* 1997; 26: 76–80.
6. Peschen M, Grenz H, Grothe C, Schoepf E, Vanscheidt W. Patterns of epidermal growth factor receptor, basic fibroblast growth factor and transforming growth factor beta 3 expression in the skin with chronic venous insufficiency. *Eur J Dermatol* 1998; 8: 334–338.
7. Peschen M, Grenz H, Brand-Saberi B, Bunaes M, Simon JC, Schoepf E, et al. Increased expression of platelet derived growth

- factor receptor alpha and beta and vascular endothelial growth factor in the skin with chronic venous insufficiency. *Arch Dermatol Res* 1998; 290: 291–297.
8. Peschen M, Lahaye T, Hennig B, Weyl A, Simon JC, Vanscheidt W. Expression of the adhesion molecules ICAM-1, VCAM-1, LFA-1 and VLA-4 in the skin is modulated in progressing stages of chronic venous insufficiency. *Acta Derm Venereol* 1999; 79: 27–32.
  9. Herouy Y, Nockowski P, Schoepf E, Norgauer J. Lipodermatosclerosis and the significance of proteolytic remodeling in the pathogenesis of venous ulceration. *Int J Mol Med* 1999; 3: 511–515.
  10. Weckroth M, Vaheri A, Lauharanta J, Sorsa T, Konttinen YT. Matrix metalloproteinases, gelatinase and collagenase, in chronic leg ulcers. *J Invest Dermatol* 1996; 106: 1119–1124.
  11. Rogers AA, Burnett S, Moore JC, Shakespeare PG, Chen WYJ. Involvement of proteolytic enzymes—plasminogen activators and matrix metalloproteinases—in the pathophysiology of pressure ulcers. *Wound Rep Reg* 1995; 3: 273–283.
  12. Chapman HA. Plasminogen activators, integrins, and the coordinated regulation of cell adhesion and migration. *Curr Opin Cell Biol* 1997; 9: 714–724.
  13. Stacey MC, Burnand KG, Mahmoud-Alexandroni M, Gaffney PJ, Bhogal BS. Tissue and urokinase plasminogen activators in the environs of venous and ischaemic leg ulcers. *Br J Surg* 1993; 80: 596–599.
  14. Rogers AA, Burnett S, Lindholm C, Bjellerup M, Christensen OB, Zederfeldt B, et al. Expression of tissue-type and urokinase-type plasminogen activator activities in chronic venous leg ulcers. *Vasa* 1999; 28: 101–105.
  15. Porter JM, Moneta GL. Reporting standards in venous disease: an update. International Consensus Committee on Chronic Venous Disease. *J Vasc Surg* 1995; 21: 635–645.
  16. Beebe HG, Bergan JJ, Bergqvist D, Eklof B, Eriksson I, Goldman MP, et al. Classification and grading of chronic venous disease in the lower limbs. A consensus statement. *Int Angiol* 1995; 14: 197–201.
  17. Sappino AP, Huarte J, Vassalli JD, Belin D. Sites of synthesis of urokinase and tissue-type plasminogen activators in the murine kidney. *J Clin Invest* 1991; 87: 962–970.
  18. Vassalli JD, Belin D. Amiloride selectively inhibits the urokinase-type plasminogen activator. *FEBS Letters* 1987; 214: 187–191.
  19. Schaefer BM, Maier K, Eickhoff U, Todd RF, Kramer MD. Plasminogen activation in healing human wounds. *Am J Pathol* 1994; 144: 1269–1280.
  20. Chen WYJ, Rogers AA. Studies of growth factor and matrix proteinase activities during early stages of wound healing. In: Altmeyer P, El Gammal S, Hoffmann K, Hutchinson J, eds. *Wound healing and skin physiology*. Berlin: Springer-Verlag, 1995: 239–243.
  21. van Hinsbergh VW, Koolwijk P, Hanemaaijer R. Role of fibrin and plasminogen activators in repair-associated angiogenesis: in vitro studies with human endothelial cells. *EXS* 1997; 79: 391–411.
  22. Spiers EM, Lazarus GS, Lyons-Giordano B. Expression of plasminogen activator enzymes in psoriatic epidermis. *J Invest Dermatol* 1994; 102: 333–338.
  23. Bechtel MJ, Reinartz J, Rox JM, Inndorf S, Schaefer BM, Kramer MD. Upregulation of cell-surface-associated plasminogen activation in cultured keratinocytes by interleukin-1 beta and tumour necrosis factor-alpha. *Exp Cell Res* 1996; 223: 395–404.
  24. Peschen M, Schild A, Brand-Saberi B, Rogers AA, Augustin M, Schoepf E, et al. Expression and distribution of laminin, fibronectin and tenascin is stage dependently modulated in the skin of chronic venous insufficiency. *Phlebology* 1998; 13: 113–119.
  25. Kapila YL, Kapila S, Johnson PW. Fibronectin and fibronectin fragments modulate the expression of proteinases and proteinase inhibitors in human periodontal ligament cells. *Matrix Biol* 1996; 15: 251–261.
  26. Yager DR, Zhang LY, Liang HX, Diegelmann RF, Cohen IK. Wound fluids from human pressure ulcers contain elevated matrix metalloproteinase levels and activity compared to surgical wound fluids. *J Invest Dermatol* 1996; 107: 743–748.
  27. Saarialho-Kere UK. Patterns of matrix metalloproteinase and TIMP expression in chronic ulcers. *Arch Dermatol Res* 1998; Suppl 290: S47–54.
  28. Mazzieri R, Masiero L, Zanetta L, Monea S, Onisto M, Garbisa S, et al. Control of type IV collagenase activity by components of the urokinase-plasmin system: a regulatory mechanism with cell-bound reactants. *EMBO J* 1997; 16: 2319–2332.
  29. Leu AJ, Leu HJ, Franzeck UK, Bollinger A. Microvascular changes in chronic venous insufficiency – a review. *Cardiovasc Surg* 1995; 3: 237–245.
  30. Peschen M, Vanscheidt W, Sigmund G, Behrens JO, Schoepf E. Computerized tomography and magnetic resonance tomography studies before and after paratibial fasciotomy. *Hautarzt* 1996; 47: 521–525.
  31. Mackie EJ, Ramsey S. Modulation of osteoblast behaviour by tenascin. *J Cell Sci* 1996; 109: 1597–1604.
  32. Abiko Y, Arai J, Matsuzawa K, Inoue T, Shimono M, Kaku T. Human gingival fibroblast migration promoted by platelet-derived growth factor on titanium is correlated with release of urokinase type plasminogen activator. *Bull Tokyo Dental College* 1996; 37: 113–118.
  33. Jensen PJ, Lavker RM. Modulation of the plasminogen activator cascade during enhanced epidermal proliferation in vivo. *Cell Growth Differ* 1996; 7: 1793–1804.
  34. Lotti T, Benci M. Plasminogen activators, venous leg ulcers and reepithelialization. *Int J Dermatol* 1995; 34: 696–699.
  35. Schaefer BM, Stark HJ, Fusenig NE, Todd RF, 3rd, Kramer MD. Differential expression of urokinase-type plasminogen activator (uPA), its receptor (uPA-R), and inhibitor type-2 (PAI-2) during differentiation of keratinocytes in an organotypic coculture system. *Exp Cell Res* 1995; 220: 415–423.