

CLINICAL REPORT

Ultrasound Investigation of Port Wine Stains

AGNETA TROILIUS¹, GUNNAR SVENDSEN² and BO LJUNGGREN¹

¹Department of Dermatology, University Hospital, Malmö, Sweden. and ²Cortex Technology, Hadsund, Denmark.

Congenital capillary malformation, or port wine stains (PWS), have been treated with the pulsed dye laser since the late 1980s. Some studies have shown better results when the malformation has been located on the lateral face, forehead, neck, trunk or shoulder and inferior results, with more treatments required, when it is located on the central face area, dermatome V2 or the extremities. The purpose of this study was to determine the depth of the lesion in various locations. A total of 55 patients with untreated PWS were investigated with a high-resolution 20 MHz ultrasound system. The mean maximum depth of all PWS that were measurable (45 out of 55) was 1.00 mm (± 0.50 SD), with a range of 0.2–3.7 mm. Lesions located on the forehead (1.26 ± 0.44 mm) and on the medial face (1.23 ± 0.65 mm), were deeper than lesions on the trunk and extremities. PWS involving areas that respond poorly to treatment were on average 0.14 mm deeper than PWS involving areas that responded well. The depth of the PWS, as determined with high-resolution ultrasound, seems to correlate only to some degree with the response to pulsed dye laser treatment. Since this treatment, with its superficial penetration, cannot reach the deeper vessels of a PWS, skin ultrasound could be a good complement in the prognostic investigation as well as for planning treatment. Key words: PWS; depth; capillary malformations; good response; bad responder; pulsed dye laser.

(Accepted January 3, 2000.)

Acta Derm Venereol 2000; 80: 196–199.

A. Troilius, Department of Dermatology, University Hospital, S-205 02 Malmö, Sweden.

Congenital capillary malformations, commonly known as port wine stains (PWS), are macular reddish lesions, which are characterized by ectatic venular-sized channels within both the papillary and reticular dermis (1). According to laser Doppler perfusion imaging studies, a high proportion of PWSs have increased bloodflow in comparison with normal contralateral skin (2). Thermography, on the other hand, demonstrated a higher temperature with respect to surrounding skin in only 2 out of 12 patients with PWS (3).

Since the late 1980s the treatment of choice for PWS has been the pulsed dye laser (PDL), with a 585 nm wavelength and a 450 μ s pulse duration. More recently, modifications in the form of a longer wavelength and a longer pulsewidth have been introduced. Renfro & Geronemus found significantly different treatment responses in PWS of different anatomical locations (4). In addition to this, the age of the patient, the maturation (colour, thickness and degree of hypertrophy) and the size of the PWS and scarring from prior treatments affect the result. Fewer treatments were required for forehead, temple, lateral aspects of the face, neck and chest and shoulder lesions. Facial dermatome V2, medial and central aspects of the face and the extremities required more

treatments (5). Many investigators have addressed the question of these treatment failures (4–6). The penetration depth of the PDL is approximately 1.2 mm according to Tan et al. (7), but is limited to a maximum of 0.65 mm (mean 0.37 mm) according to Hohenleutner et al. (8). Because of the limited penetration of the PDL the depth of the PWS may be a factor determining the outcome of PDL (6). Fiskerstrand et al. (9), studying punch biopsies, postulated that PWS with good blanching after PDL had significantly more superficially located vessels than the PWS of the moderate and poor responders. Vessels of a small calibre, around 20 μ m, have been shown to be another reason for poor response (9). At present, there is no laser or intense pulsed light source that can treat every type of vascular lesions successfully.

Haedersdahl et al. (10) have demonstrated with ultrasonography, lower dermal echogenicity in PWS before PDL treatment than after. As far as we know, no previous study has measured PWS with ultrasound, in an attempt to correlate the depth of the PWS vessels with various anatomical locations.

MATERIALS AND METHODS

Patients

A total of 55 patients (37 females) with untreated PWS were studied with skin ultrasound. All had macular PWS. The mean age of the patients was 18.9 years (range 3 months to 69 years; median 15 years). The anatomical location of the PWS varied. In total, 1–8 ultrasound measurements were made on each patient, depending on the size and location of the PWS. In 19 of the 55 patients we performed 3 measurements on the same PWS macula, i.e. anatomical unit. Skin ultrasound was also always measured on the normal contralateral side of the site of the PWS.

Skin ultrasound

Throughout this study the depth of the lesions was evaluated using a high-resolution ultrasound system dedicated to skin applications (11). A DermaScan C Ver. 3 (Cortex Technology ApS, Hadsund, Denmark) was used. The system configuration for this study operated at 20 MHz and provided a resolution of $60 \times 130 \mu$ m (axial \times lateral) with 10 mm penetration.

The system consists of a main unit accommodating the signal processing and computing components, a colour monitor to display the two-dimensional recordings and a handheld B-scanning ultrasound probe. The size of the probe was 19×33 mm and the scan length 12.1 mm.

The principle of ultrasound imaging is based on the ultrasonic wave being partly reflected at the boundary of adjacent structures when travelling through tissue. The strength of this reflection depends on differences in the density of such structures, which leads to an amplitude variation of the reflected signal. Finally, processing of the signal received from multiple ultrasound pulses over an area of the skin forms a two-dimensional image; a so-called B-scan.

The system calculates distance (*a*) using the equation:

$$a = 1/2ct$$

where *c* is the average velocity of sound in the tissue and *t* is the time required for the ultrasound pulse to travel from the transducer into the tissue and back to the transducer. *c* was set at 1580 m/s as an average speed of sound.

Depth measurements were based on A-scans, i.e. individual point-to-point measurements perpendicular to the skin surface, which were then averaged. All images were stored on disk for later analysis and printing. The DermaScan C Ver. 3 was set up to use a colour coded greyscale, which displays less reflective tissue as dark/dark green colour and highly reflective tissue as yellow/white colour.

In order to compare with later recordings the lesion was carefully mapped on a transparent plastic overlay film and the scan position marked. The same interpreter (G.S.) evaluated all ultrasound images.

Ultrasound image

The visual appearance of an ultrasound image depends on the body site from which it originates. Homogeneous components (fat, water, blood) show less internal reflections than non-homogeneous tissue (dermis). For this reason, blood in the dermis can be clearly distinguished from surrounding structures. A PWS appears as a superficial dark band right under the epidermal entrance reflection (Fig. 1A). Our measurements have been taken from the deepest part of each PWS image.

Statistics

In the calculations, the mean values from patients and localization were used. The Mann-Whitney U test was used when comparing depth between groups. Spearman rank correlation coefficient was calculated for studying the relationship between age and depth.

RESULTS

In 10 of 55 patients (18%) there was no clear indication of a PWS on the ultrasound image and therefore no possibility to measure the depth. Clinically, however, these PWS were clearly visible. In the remaining 45 patients the PWS could be evaluated ultrasonically, showing a variation in depth from 0.2 to 3.7 mm. The mean (\pm SD) maximum depth of all PWS was 1.00 ± 0.50 mm. The deepest PWS were seen on the lips, nose and chin. Eight measurements were made on 7 upper lips with a mean depth of 1.21 mm (± 0.37 , range 0.78–1.8). With increasing age there was a tendency towards deeper PWS, although there was not a significant correlation (Fig. 2). When we looked for differences between the anatomical locations there were no significant differences compared with, for example, medial face (Table I). Only the forehead demonstrated some significant changes in comparison with the other locations.

We divided all of our PWS into two groups, in order to determine whether or not there was a correlation with previously published data on the response to PDL treatment on certain anatomical locations (5, 8):

- I. **Good responding locations:** forehead (including the temple), lateral face, neck, trunk had a mean depth of 0.94 mm (range 0.21–2.2, ± 0.47).
- II. **Bad responding locations:** medial face (including the nose, lip, chin, dermatome V2, extremities (including the buttocks)) had a mean depth of 1.08 mm (range 0.28–2.67, ± 0.53).

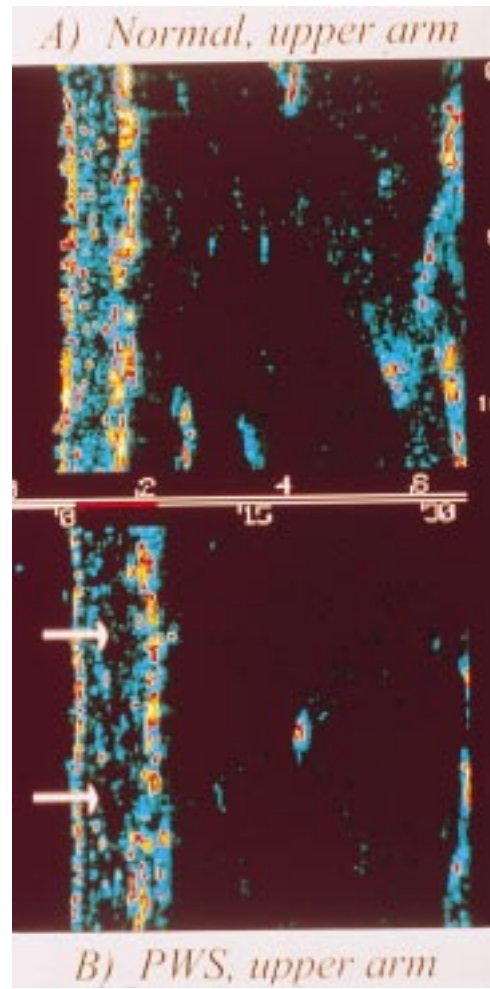


Fig. 1. Ultrasound images of (A) normal skin on upper arm and (B) PWS upper arm (arrows). (For explanation of colour code see text).

Although there was a trend to more superficial vessels in good responding locations the difference between the groups was not significant.

In order to study the intra-PWS variability, 19 patients in this study had 3 measurements performed within 1 confluent capillary macula (Fig. 3). All except 3 PWS showed a

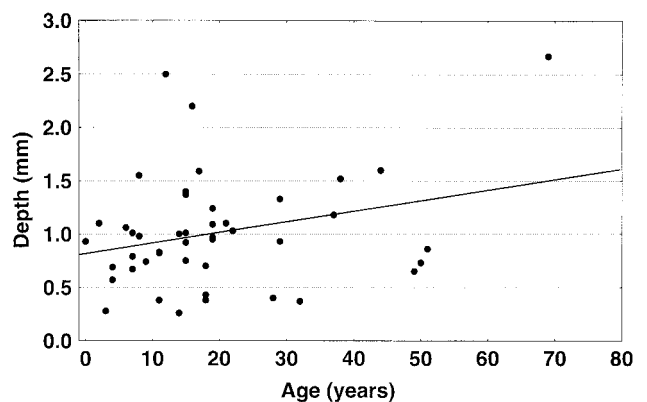


Fig. 2. Mean depth of each PWS on 45 patients with correlation to their age. Each point represents 1 patient with the average of his/her measurements within his/her PWS. $r_s = 0.19$. ns.

Table I. Anatomical locations and depth of PWS

Location	n	Mean (mm)	SD	p*
Forehead	8	1.26	0.44	
Medial face	14	1.23	0.65	n.s.
Lateral face	12	0.92	0.25	n.s.
Neck	10	0.90	0.62	n.s.
Extremities	12	0.89	0.28	0.045
Trunk	6	0.64	0.45	0.023

* p Statistical significance of difference vs. forehead (n.s.=not significant). $p < 0.05$.

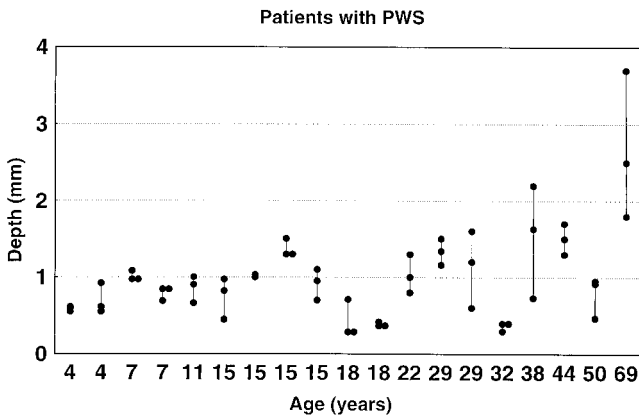


Fig. 3. Nineteen patients (arranged in order of increasing age) with 3 ultrasound measurements of the same port wine stain in order to study the intra-individual variation.

variation of 0.5 mm or less within different parts of the lesion. A variation of only around 0.1 mm was seen in 7/19. There was a tendency towards greater variability of the depths with increasing age, although this was not significant.

DISCUSSION

High-resolution ultrasound is an objective and non-invasive technique that provides valuable information about the depth of the majority of PWS prior to treatment and during follow-up with no discomfort to the patient. This technique has been shown to provide accurate and reproducible dimensional measurements of structures within the dermis and subcutaneous tissue (10–14). The probe is easy to handle and its relatively small dimensions provide access to most body regions, although scanning around the nose, eyes and ears may prove difficult. This would have been even more difficult if we had used a C-mode probe, that is available on the market. A C-mode probe can scan a bigger area (22.4×22.4 mm) than the B-mode probe, but according to our knowledge the B-mode probe is better when investigation PWS, because of its smaller size and shorter scanning time.

Attenuation of the ultrasound signal varies due to body composition, measurement site, depth, frequency etc. and, accordingly, the gain setting may need to be individually adjusted to obtain the best image quality. No other set-up parameters need attention during scanning. Horizontal shadows in the image caused by tiny air bubbles trapped in the coupling gel are frequently seen. This is a well-known

artefact in high-frequency ultrasound imaging, which is easily identified and corrected for simply by wiping off the membrane and skin surface prior to applying fresh gel.

One must pay attention to other skin conditions capable of causing subepidermal dark bands in the image. Particularly in sun-exposed areas solar elastosis may provide similar ultrasonic patterns. Consequently, it is important to perform a reference scan of normal skin adjacent to the lesion for comparison.

Histological evaluation of the depth of a PWS has earlier been used as the standard method of depth determination. However, punch biopsies cause scarring and are of limited value for comparative study, since they undergo retraction on fixation and change of dimension on cutting (11). Earlier histology studies of PWS demonstrated a mean vessel depth of 0.46 mm (15) which is less than half the depth we have found.

When we studied the intra-PWS variability by ultrasound we noted that this variation had a tendency to increase with age (Fig. 3). Therefore, we took several measurements within each PWS, especially if they varied in colour and surface area.

The penetration depth of the 20 MHz ultrasound is 10 mm, which is adequate for registering all PWS. The penetration depth of the PDL is, according to earlier punch biopsy studies on albino pigs, a maximum of 0.65 mm with a mean depth of 0.37 mm (8), down to 1.2 mm measured on patients (7). It is obvious that many of the deeper PWS, e.g. of the medial face, might not respond well to PDL. Deeper vessels may not be coagulated because of shadow effects caused by superficial vessel layers (8). According to Motley et al. there are 2 types of microvascular abnormalities (17). Type 1 consists of superficial, tortuous, dilated end capillary loops (blobs), which are readily treated with PDL and type 2 of dilated, ectatic vessels in the superficial horizontal vascular plexus (rings), which are more deeply situated and do not respond as well to the PDL.

Ultrasonography seems to evaluate parameters different from skin redness (10). Ten out of 55 PWS were not visible on the ultrasound image. This was probably due to the superficial location of the vessels or alternatively, a too thin calibre of the vessel. All of these 10 PWS were pale in colour and 9 were geographic in pattern and not confluent. Seven were at good, 2 at bad responding locations and one PWS covered both types of locations.

Two previous studies have also suggested that there is a correlation between the depth of the vessels, as determined histologically, and the response to treatment (6, 18). The level of the vessels of lesions in the bad responding areas, was only 0.14 mm deeper than the vessels of the good responding areas, a difference not statistically significant. Interestingly, the forehead, which according to earlier experience is a good responding location (Table I), had almost the same maximum mean depth as the medial face, which has been shown to be difficult to treat. Both locations should theoretically be too deep to be reached by the PDL.

Our earlier studies have shown that there are potential psychological benefits from early treatment of PWS in children (19). Some studies have found that younger patients with PWS responded better than older patients (20, 21). It has been postulated that PWS in adults need more treatments because the vessels are significantly wider than in children (21). Our study however, could not show a significant increase

of the depth of the PWS with increasing age, but our material represents several anatomical locations and may have been too small from some of the locations. Tang et al. suggested that with advancing age, both normal skin and PWS have a greater total haemoglobin content and an increased proportion of deoxyhaemoglobin, consistent with increasing vascular dilatation and tortuosity; and that the age-associated changes in PWS are an exaggeration of those in normal skin (22).

Haedersdahl et al. (10) using the same equipment as in our study, scanned 12 children with facial PWS before and after 1 PDL treatment. There was no correlation between the change in echogenicity and the clinically assessed treatment response, but lower dermal echogenicity of preoperative PWS than of postoperative PWS and healthy skin were revealed. Their median value of skin thickness was 1.00 mm (0.92–1.13 mm) before PDL treatment. This figure correlates well with our findings of the mean maximum depth of 1.00 mm in our untreated PWS. They concluded that lesional thickness correlated inversely with the ultrasound assessed treatment response.

Although the depth of the vessels is not the only prognostic factor it should be taken into consideration together with the rate of blood flow (2) and the vessel diameter (9) when considering treatment of a PWS. It is not surprising that some lesions fail to respond to the fixed wavelength and pulse duration of the PDL. In the presence of deeper vessel, one should probably use a wavelength longer than the 585 nm of the PDL or 532 nm with a cooling tip.

ACKNOWLEDGEMENTS

We are grateful for suggestions and comments from Milton Waner, MD, FACS, Little Rocks, USA. The authors also would like to thank Jan-Åke Nilsson, BS, for help with the statistics. This study was supported by the Edvard Welander and the Finsen foundations.

REFERENCES

- Mulliken JB, Glowacki J. Hemangiomas and vascular malformations in infants and children: a classification based on endothelial characteristics. *Plast Reconstr Surg* 1982; 69: 412–420.
- Troilius A, Ljunggren B. Evaluation of port wine stains by laser doppler perfusion imaging and reflectance photometry before and after pulsed dye laser treatment. *Acta Derm Venereol* 1996; 76: 291–294.
- Troilius A, Wårdell K, Bornmyr S, Nilsson GE, Ljunggren B. Evaluation of port wine stain perfusion by laser doppler imaging and thermography before and after argon laser. *Acta Derm Venereol* 1992; 72: 6–10.
- Renfro L, Geronemus RG. Anatomical differences of port wine stains in response to treatment with the pulsed dye. *Arch Dermatol* 1993; 129: 182–188.
- Orten SS, Waner M, Flock S, Roberson PK, Kincannon J. Port wine stains: an assessment of 5 years of treatment. *Arch Otolaryngol Head Neck Surg* 1996; 122: 1174–1179.
- Onizuka K, Tsuneda K, Shibata Y, Ito M, Sekine I. Efficacy of flashlamp-pumped pulsed dye laser therapy for port wine stains: clinical assessment and histopathological characteristics. *Br J Plast Surg* 1995; 48: 271–279.
- Tan OT, Murray S, Kuran SK. Action spectrum of vascular specific injury using pulsed irradiation. *J Invest Dermatol* 1989; 92: 868–871.
- Hohenleutner U, Hilbert M, Landthaler M. Epidermal damage and limited coagulation depth with the flashlamp-pumped pulsed dye laser: a histochemical study. *J Invest Dermatol* 1995; 10: 235–243.
- Fiskerstrand EJ, Svaasand LO, Kopstad G, Ryggen K, Aase S. Photothermally induced vessel-wall necrosis after pulsed dye laser treatment: lack of response in port wine stains with small sized or deeply located vessels. *J Invest Dermatol* 1996; 107: 671–675.
- Haedersdal M, Efsen J, Gniadecka M, Fogh H, Keiding J, Wulf HC. Changes in skin redness, pigmentation, echostructure, thickness, and surface contour after 1 pulsed dye laser treatment of port wine stains in children. *Arch Dermatol* 1998; 134: 175–181.
- Serup J, Keiding J, Fullerton A, Gniadecka M, Gniadecka R. High-frequency ultrasound examination of skin: introduction and guide. In: Serup J, Jemec BE, eds. *Handbook of non-invasive methods and the skin*. USA: CRC Press, 1995; 239–256.
- Harlan CC, Barber JC, Gusterson BA, Mortimer PS. High frequency, high resolution B-scan ultrasound in the assessment of skin tumours. *Br J Dermatol* 1993; 128: 525–532.
- Nielsen TN, Iversen HK, Tfelt-Hansen P, Olesen J. Small arteries can be accurately studied in vivo, using high frequency ultrasound. *Ultrasound Med Biol* 1993; 19: 717–725.
- Rippon MG, Springett K, Walmsley R, Patrick K, Millson S. Ultrasound assessment of skin and wound tissue: comparison with histology. *Skin Res Technol* 1998; 4: 147–154.
- Barsky SH, Rosen, Ger DE, Noe J. The nature and evolution of port wine stains: a computer-assisted study. *J Invest Dermatol* 1980; 74: 154–157.
- de Rigal J, Escoffier C, Pharm M, Querleux B, Faivre B, Agache P, Leveque J. Assessment of ageing of the human skin by in vivo ultrasonic imaging. *J Invest Dermatol* 1989; 93: 621–625.
- Motley RJ, Lanigan SW, Katugampola GA. Videomicroscopy predicts outcome in treatment of port wine stains. *Arch Dermatol* 1997; 133: 921–922.
- Fiskerstrand EJ, Svaasand LO, Kopstad G, Dalakaer M, Norvang LT, Volden G. Laser treatment of port wine stains: therapeutic outcome in relation to morphological parameters. *Br J Dermatol* 1996; 134: 1039–1043.
- Troilius A, Wrangsjö B, Ljunggren B. Potential psychological benefits from early treatment of port wine stains in children. *Br J Dermatol* 1998; 139: 59–65.
- Geronemus RG. Pulsed dye laser treatment of vascular lesions in children. *J Dermatol Surg Oncol* 1993; 19: 303–310.
- Tan OT, Sherwood K, Gilchrist BA. Treatment of children with port wine stains using the flashlamp-pulsed tunable dye laser. *N Engl J Med* 1989; 320: 416–421.
- Tang SV, Gilchrist BA, Noe JM, et al. In vivo spectrophotometric evaluation of normal lesional and laser treated skin in patients with portwine stains. *J Invest Dermatol* 1983; 80: 420–423.