

may irritate skin, facilitate the development of contact dermatitis or bacterial and mycological infections (1).

BTXA has been used recently to treat focal hyperhidrosis (gustatory sweating, palmo-plantar and axillary hyperhidrosis) (4, 5). There are no data available for the treatment of stump hyperhidrosis. We used BTXA for stump hyperhidrosis in a dosage comparable to that used in palmar hyperhidrosis, i.e. 100 U of Botox<sup>®</sup>. The treatment was very effective not only for focal hyperhidrosis of the stump but it also showed a preventive effect on the associated eczema. In another study with tap water iontophoresis for hyperhidrotic hand eczema, it could be demonstrated that effective treatment of hyperhidrosis is an important factor for prolongation of disease-free interval in atopic eczema and contact dermatitis (9). Further studies should be performed to investigate this positive side-effect of hyperhidrosis treatment.

## REFERENCES

1. Levy SW. Amputees: skin problems and prostheses. *Cutis* 1995; 55: 297–301.
2. Hildebrandt D, Ziegler K, Wollina U. Electrical impedance and transepidermal water loss of healthy human skin under different conditions. *Skin Res Technol* 2000; 4: 130–134.
3. Stoman LP. Treatment of hyperhidrosis. *Dermatol Clin* 2000; 16: 863–869.

4. Schnider P, Binder M, Auff E, Kittler H, Berger T, Wolff K. Double-blind trial of botulinum A toxin for the treatment of focal hyperhidrosis of the palms. *Br J Dermatol* 1997; 136: 548–552.
5. Naumann M, Hofmann U, Bergmann I, Hamm H, Toyka KV, Reiners K. Focal hyperhidrosis: effective treatment with intracutaneous botulinum toxin. *Arch Dermatol* 2000; 134: 301–304.
6. Brin MF. Botulinum toxin: chemistry, pharmacology, toxicity, and immunology. *Muscle Nerve* 1997; Suppl. 6: S146–S168.
7. Brasch J, Henseler T, Aberer W, et al. Reproducibility of patch tests. A multicenter study of synchronous left-versus right-sided patch tests by the German Contact Dermatitis Research Group. *J Am Acad Dermatol* 1994; 31: 584–591.
8. Minor V. Ein neues Verfahren zu der klinischen Untersuchung der Schweißabsonderung. *Dtsch Z Nervenheilkd* 1927; 101: 301–306.
9. Wollina U, Uhlemann C, Elstermann D, Köber L, Barta U. Therapie der Hyperhidrosis mittels Leitungswasser-Iontophorese-positive Effekte auf Abheilungszeit und Rezidivfreiheit bei Hand-Fuß-Ekzemen. *Hautarzt* 2000; 49: 19–113.

Accepted January 19, 2000.

Uwe Wollina, Helga Konrad, Tim Graefe and Jens Thiele  
Department of Dermatology and Allergology, Friedrich-Schiller-University of Jena, Erfurter Strasse 35, D-07740 Jena, Germany.  
E-mail: uwol@derma.uni-jena.de.

## Basal Cell Carcinoma Arising in a Localized Linear Verrucous Epidermal Naevus

Sir,

A 40-year-old female had had multiple, firm, brown verrucous papules arranged in a linear plaque over her left cheek since birth. The lesion had been static until 2 months before presentation, when she noticed an asymptomatic, erythematous papule that appeared spontaneously in the centre of the lesion. She had not received any treatment previously for the condition. Her general physical and systemic examination were within normal limits. Local examination revealed a 5 × 1 cm linear band-shaped plaque composed of multiple, 1–3 mm, brown verrucous papules over her left cheek. There was a single, firm, erythematous, dome-shaped, smooth-surfaced, 1.0 cm papule in the centre of the lesion (Fig. 1). A clinical diagnosis of localized linear verrucous epidermal naevus was made.

Biopsy from the centre of the lesion showed hyperkeratosis, parakeratosis, irregular acanthosis and papillomatosis. Budding of basaloid cells from the basal layer into the dermis was seen (Fig. 2). A histopathological diagnosis of verrucous epidermal naevus with basal cell carcinoma (BCC) change was considered. Excision biopsy of the remaining portion of the dome-shaped papule with an adequate margin revealed features of BCC. The section showed islands of basaloid cells with dense chronic inflammatory cell infiltrate in the dermal stroma (Fig. 3). The peripheral cells of the tumour had a palisading arrangement of nuclei, confirming the diagnosis of solid type of BCC change occurring in the verrucous

epidermal naevus lesion. The patient has been on follow-up for the last 18 months with uneventful course.

## DISCUSSION

Verrucous epidermal naevus are circumscribed developmental (hamartomatous) lesions comprised of keratinocytes (1). BCC is a known complication of epidermal naevi. It occurs more

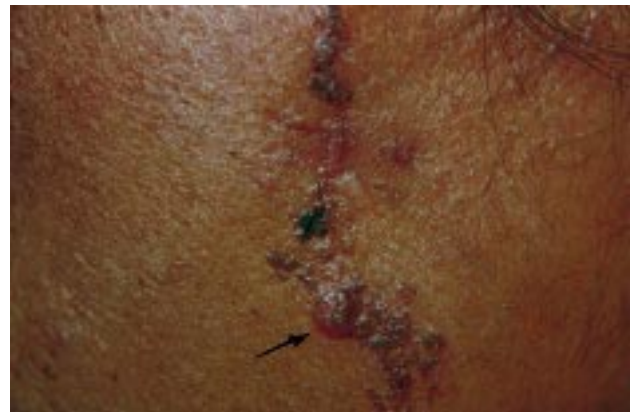

Fig. 1. Plaque of localized linear verrucous epidermal naevus with a recently visible dome-shaped papule of basal cell carcinoma (arrow).

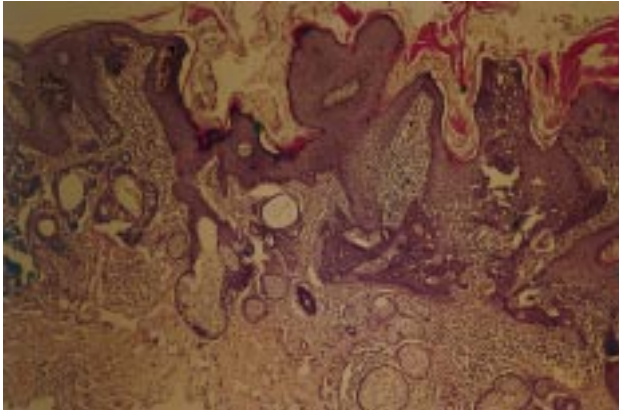


Fig. 2. Biopsy from the centre of the lesion, showing hyperkeratosis, parakeratosis, acanthosis and papillomatosis. Budding of basaloid cells invading the dermis is seen in the centre and on the left edge of the photomicrograph. (H & E stain  $\times 40$ ).

frequently in naevus sebaceus and syringocystadenoma papilleferum, but rarely in verrucous epidermal naevi (1). To the best of our knowledge, only 7 case reports, comprising 8 patients (7 men and 1 woman), have so far been published in the world literature in which BCC appeared in a verrucous epidermal naevus (2–8). Five of these cases are from western countries and one from Japan. All of the patients had fair skin. Verrucous epidermal naevus was present on the exposed areas of the body in 5 patients (2, 4–6). The naevi were localized in 3 patients (4, 6) and extensive or generalized in 4 patients (2, 3, 5, 7). Multiple BCCs arose in 4 patients (3–6). In 3 patients, squamous cell carcinoma also developed along with BCC within the verrucous epidermal naevus (2, 3, 8). A history of preceding trauma, such as excision, electrocautery,



Fig. 3. Section of excised papule of BCC showing islands of basaloid cells attached to the epidermis (at the right edge of the section) with dense chronic inflammatory cell infiltrate in the stroma. (H & E stain  $\times 100$ ).

nicks while shaving, and burns, was reported in many of these patients. The interval between such injuries and the appearance of BCC varied from 6 months to as long as 56 years (4, 6). Bleeding and appearance of a new nodule were the common presenting complaints. Histopathologically, pigmented, cystic and ulcerated variants of BCC were seen in these patients.

The patient described here was a housewife with no history of working outdoors for prolonged periods or of preceding trauma. There was no history of exposure to ionizing radiation or immunosuppression. Appearance of a new lesion prompted her to seek medical help. As the practice of dermatology is becoming more procedure-oriented, patients will be asking for and dermatologists will be offering and doing more excisions of such lesions. It is advocated that the excised lesion be subjected to histopathological examination to rule out malignant transformation, especially if there is a history of recent change in the appearance of the lesion. Complete excision of the localized type of verrucous epidermal naevus with an adequate margin is advised wherever feasible, as BCC may be clinically evident in only one portion, while histopathologically it may also be present elsewhere, as suspected in the case reported by Goldberg (6). Regular follow-up after excision is recommended in order to detect recurrence or residual tumour early on.

#### REFERENCES

1. Atherton DJ. Naevi and other developmental defects. In: Champion RH, Burton JL, Burns DJ, Breathnach SM, eds. Textbook of dermatology, 6th edition, Vol. 1. London: Blackwell Scientific Publications, 1998: 519–616.
2. Toyama I, Kojima R. A case of verrucous epidermal nevus associated with basal cell epitheliomas, Bowen's disease and squamous cell epithelioma. *Jap J Dermatol Urol* 1936; 40: 116.
3. Pack GT, Sunderland DA. Nevus unius lateris. *Arch Surg* 1941; 43: 341–375.
4. Winer LH, Levin GH. Pigmented basal cell carcinoma in verrucous nevi. *Arch Dermatol* 1961; 83: 960–964.
5. Litzow TJ, Engel S. Multiple basal cell carcinomas arising in a linear nevus. *Am J Surg* 1961; 101: 378.
6. Goldberg HS. Basal cell epithelioma developing in a localized linear epidermal nevus. *Cutis* 1980; 25: 295–299.
7. Horn MC, Sausker WF, Pierson DL. Basal cell epithelioma arising in a linear epidermal nevus. *Arch Dermatol* 1981; 117: 247.
8. Kono E, Izumi Y, Hirai A, et al. A case of squamous cell carcinoma and basal cell carcinoma arising in a linear epidermal nevus. *Rinsho Dermatol* 1992; 34: 687–691.

Accepted 31 January 2000.

Arun Joshi<sup>1</sup>, Shatrughan P. Sah<sup>2</sup>, Arun Agarwalla<sup>1</sup>, Sudha Agrawal<sup>1</sup> and Mary Jacob<sup>1</sup>  
Departments of, <sup>1</sup>Dermatology and Venereology and <sup>2</sup>Pathology, BP Koirala Institute of Health Sciences, Dharan, Nepal.  
E-mail: lovjosh@hotmail.com