

Unilateral Linear Lichen Planus with Mucous Membrane Involvement

CHRISTOPH HARTL¹, KAY H. STEEN¹, HOLGER WEGNER¹, HEINZ-WERNER SEIFERT² and THOMAS BIEBER¹

¹Department of Dermatology, University of Bonn and ²Dermatological Practice, Bonn, Germany

Linear lichen planus is a rare distinctive variant of lichen planus (LP) characterized by a pruritic eruption of lichenoid, violaceous papules in a linear distribution that sometimes assume a Blaschko line pattern. We describe a 33-year-old woman who presented with a 4-month history of a slightly pruritic unilateral linear array of papular lesions on the left side of her neck that were clinically and histologically consistent with linear LP. Two months after the onset of her skin disease she developed typical lesions with a lacy white pattern on the left lateral aspect of her tongue and the left buccal mucosa with a striking predominance for the left side. Clinically the lesions on the patient's neck were similar to lichen striatus or lichenoid epidermal naevus, a variant of linear verrucous epidermal naevus. However, the histological features and the fact that later in the course of her disease the patient developed typical LP of the oral mucosa suggest that this patient has the rare condition of linear LP with unilateral restriction. Key words: linear lichen planus; linear skin eruptions.

(Accepted September 7, 1998.)

Acta Derm Venereol (Stockh) 1999; 79: 145–146.

C. Hartl, Department of Dermatology, University of Bonn, Sigmund-Freud-Strasse 25, DE-53105 Bonn, Germany.

Lichen planus (LP) is a pruritic cutaneous and mucous membrane disorder of unknown aetiology, characterized by crops of pruritic, planar, polyangular, purple papules with a white, lacy reticular surface on close inspection. Histology reveals a lichenoid tissue reaction underlying an acanthotic epidermis with an accentuated granular layer. The disease is benign and self-limiting, although recurrences can occur. There is a higher incidence of chronic liver disease and hepatitis C virus infection in LP patients (1). Several variants of this disorder have been delineated, including the most common localized papular form, hypertrophic LP, generalized LP, follicular LP, actinic LP, erosive and non-erosive mucous membrane LP, LP of the nails, as well as annular, vesiculobullous and linear forms. We describe a patient who has the rare variant of linear LP associated with ipsilateral mucous membrane involvement.

CASE REPORT

A 33-year-old, previously healthy woman presented with a 4-month history of slightly pruritic lesions on the left side of her neck. She denied any trauma or scratching prior to the eruption and she was on no oral medication. Her past medical history and family history were both completely unremarkable.

On physical examination she had a pruritic, linear eruption of slightly keratotic lichenoid, flat papules with a violaceous hue on the left side of her neck (Fig. 1). At that time there were no nail changes and there was no evidence of mucous membrane involvement. A routine laboratory panel failed to disclose any abnormalities. Serological tests for hepatitis A, B and C virus infection were negative.

Microscopic examination of a skin biopsy showed hyperkeratosis and a vacuolated dermal-epidermal junction, obscured by a band-like lymphocytic infiltrate, consistent with lichen planus.

The patient responded well to a 3-week course of high-potency topical corticosteroid treatment.

Three months after the onset of her skin disease the patient complained of newly developed lesions on her oral mucosa and tongue. Typical white plaques with a lacy surface pattern were seen on the left lateral aspect of her tongue and the left buccal mucosa (Fig. 2A and B).

The mucous membrane lesions improved rapidly over a period of 2 weeks with the application of high-potency topical corticosteroids.

DISCUSSION

We observed a patient with a linear eruption on the neck, which was compatible with linear LP clinically and upon microscopic examination. The occurrence of typical mucous membrane LP later in the course of the disease further supports this diagnosis. The differential diagnosis of the linear variant of LP includes congenital/nevoid (ILVEN) and acquired skin diseases (lichen striatus, linear lichen nitidus, linear graft-versus-host disease and linear lichenoid drug eruption) (2). In one

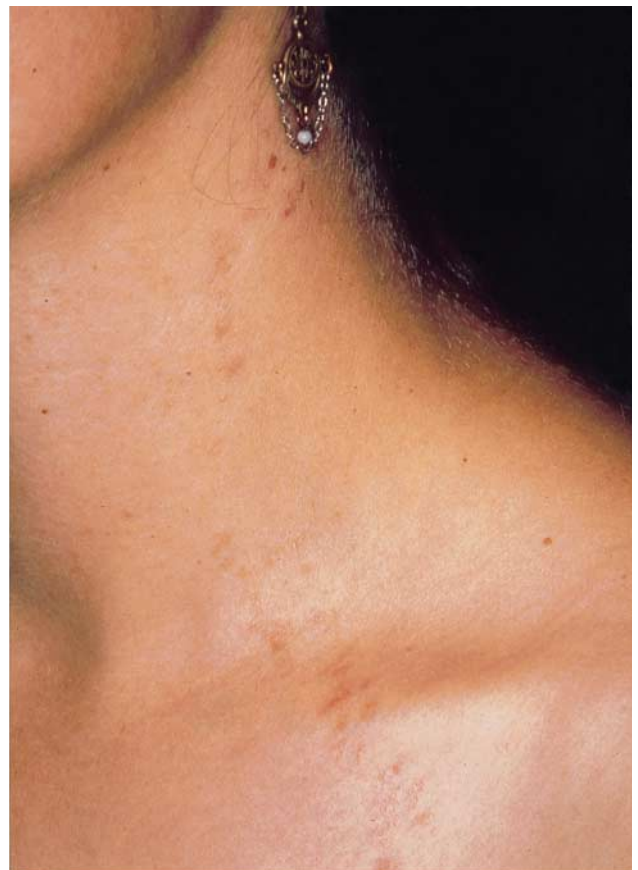


Fig. 1. A linear lichenoid eruption on the left side of the neck.

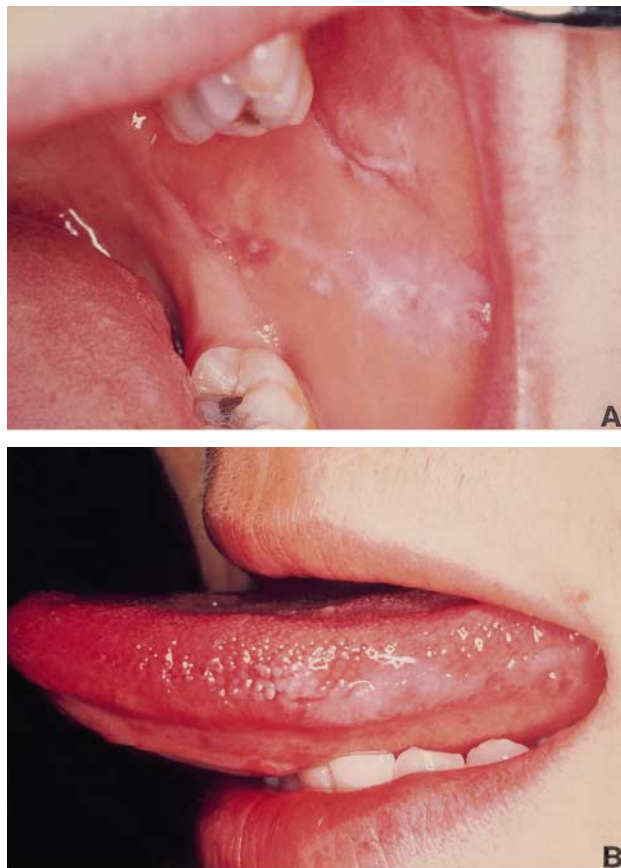


Fig. 2. (A) Left buccal mucosa. (B) Left lateral border of the tongue.

report linear LP mimicked “creeping-eruption” due to nematodes (3). Linear lesions frequently occur in patients with LP and are attributed to scratching as a consequence of severe pruritus (Köbner phenomenon) (4). In our patient, however, trauma or scratching prior to the eruption were denied and no other skin lesions were present elsewhere. Interestingly, the lesions displayed unilateral restriction with involvement of the left side of the oral mucosa and the left side of the patient’s neck. We therefore believe that this case represents true linear LP with unilateral restriction.

A distribution along the lines of Blaschko was evident in a number of patients (5 for ref.). During early foetal development a clone of cells migrate to certain areas of the integument congruent with the Blaschko lines. This subpopulation of cells is believed to acquire distinct qualities allowing for certain dermatosis to occur exclusively along these lines.

Gupta & Gorsulowsky reported one patient with unilateral LP, involving the left extremities and the left side of the trunk (6).

Brownstein et al. (7) favour the term lichenoid epidermal naevus, over “linear lichen planus”, based on the observation that most patients lack evidence of LP on distant sites from the linear eruption. Our patient, however, showed typical LP of the oral mucosa later in the course of her disease. Several other cases of concomitant mucous membrane involvement have been observed (8–11).

REFERENCES

1. Bellmann B, Reddy RK, Falanga V. Lichen planus associated with hepatitis C. *Lancet* 1995; 346: 1234.
2. Bologna JL, Seth JO, et al. Lines of Blaschko. *J Am Acad Dermatol* 1994; 31: 157–190.
3. Taniguchi Y, Minamikawa M, et al. Linear lichen planus mimicking creeping eruption. *J Dermatol* 1993; 20: 118–121.
4. Munoz MA, Perez-Bernal AM, Camacho FM. Lichenoid drug eruption following the Blaschko lines. *Dermatology* 1996; 193: 66–67.
5. Long CC, Finlay AY. Multiple linear lichen planus in the lines of Blaschko. *Br J Dermatol* 1996; 135: 275–276.
6. Gupta AK, Gorsulowsky DC. Unilateral lichen planus: An unusual presentation. *Arch Dermatol* 1987; 123: 295–296.
7. Brownstein MH, Silverstein L, Lefing W. Lichenoid epidermal nevus: “Linear lichen planus”. *J Am Acad Dermatol* 1989; 20: 913–915.
8. Katz M, Weinrauch L. Differentiating vesicular linear lichen planus and lichen striatus. *Cutis* 1987; 40: 151–153.
9. Davis ML. Zosteriform lichen planus. *Arch Dermatol Syphilol* 1938; 37: 615–618.
10. Irgang S. Zosteriform lichen planus: case report. *Cutis* 1968; 4: 1076–1078.
11. Brunsting LA. Discussion of a case report of zosteriform lichen planus presented by JF Madison at Minnesota Dermatologic Society. *Arch Dermatol Syphilol* 1940; 41: 620.