

## LETTERS TO THE EDITOR

### Annular Pustular Psoriasis Localized to the Dorsa of the Feet

Sir,

Annular pustular psoriasis (APP) is a rare form of psoriasis characterized by gyrate, annular lesions with an erythematous, scaly, pustular margin (1). Although usually generalized, in some instances it appears as a localized form (2). We herein report a case of APP localized to the dorsa of feet of a 23-year-old woman. She had a 4-year history of similar lesions on the same area, but there was no evidence of other cutaneous involvement.

#### CASE REPORT

A 23-year-old woman presented with a 2-week history of annular erythematous patches on the dorsal part of the feet (Fig. 1). They first developed as slightly pruritic erythematous plaques. For the last 4 years episodic flares had occurred every 3–4 months, especially in summer, and generally lasted 3–4 months. Approximately the same area was affected each time.

Closer examination revealed some minute pustules underlying the inner collarette of scales and crusts on the spreading margin of the lesions. As the lesions progressed peripherally, they slowly resolved with central hyperpigmentation. There were no other skin lesions elsewhere. She had no family history of similar eruptions or of atopic eczema. Repeated KOH examination and fungal culture were all negative. A bacterial culture demonstrated a moderate growth of coagulase-negative staphylococci. A routine patch test revealed no positive reac-

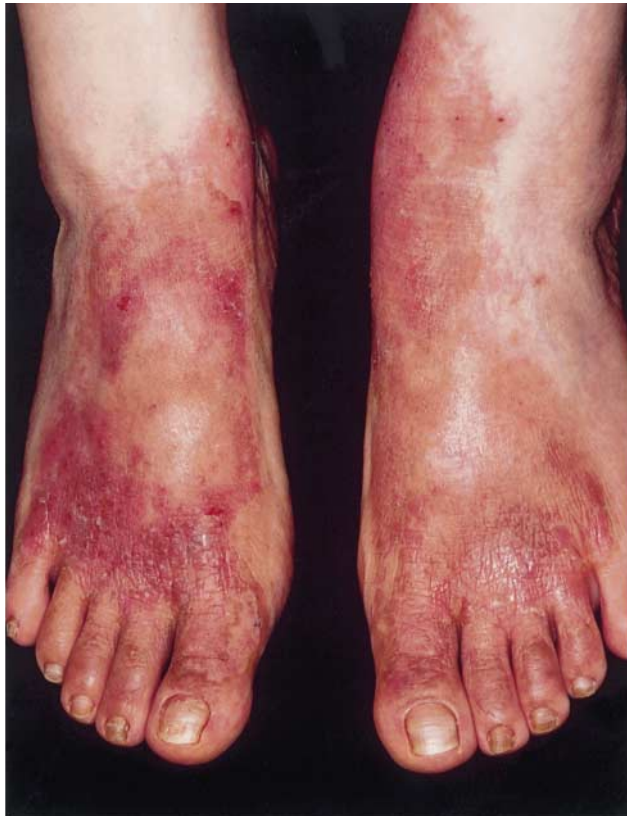

Fig. 1. Symmetrically distributed annular erythematous plaques with central clearing on the dorsa of the feet.

tion. Laboratory values including complete blood cell count, VDRL, anti-streptolysin O titre, antinuclear antibody, chemistry panels and urinalysis were all within normal limits.

A skin biopsy was taken from the residual pustule of inflammatory annular edge on the dorsum of her left foot. Histology showed a large subcorneal neutrophilic aggregation with spongiosis of the involved epidermis (Fig. 2). There were also parakeratosis, hypogranulosis and elongation of rete ridges in the epidermis, and tortuous capillaries and perivascular lymphocytic inflammatory infiltrate in the papillary dermis. These histopathological features were typical for pustular psoriasis.

She was treated initially with prednisolone 30 mg and erythromycin 2 g orally, along with wet dressing with a weak concentration of potassium permanganate solution. The lesions dried up and there was a marked improvement of the eruption, but on a maintenance dose of 10 mg prednisolone, the lesions slowly spread peripherally and some new pustules were found on the edge. Subsequent histological evaluations demonstrated pathological changes consistent with pustular psoriasis. Increasing the dose of steroid again was only partially effective and treatment was changed to dapsone (100 mg daily). The lesions resolved and were stabilized on a lower maintenance dose of dapsone (50 mg daily) for 1 month. Thereafter, however, further exacerbation was noted at times, probably after periods of emotional stress. We subsequently recommended a Re-PUVA (combined therapy with systemic etretinate and PUVA), but the patient refused the treatment because she wanted to conceive.

#### DISCUSSION

Differential diagnosis of our patient should include tinea pedis, contact dermatitis, infectious eczematoid dermatitis, nummular eczema, atopic dermatitis, erythema multiforme and erythema annulare centrifugum. In addition, erythema chronicum migrans, subcorneal pustular dermatosis, necrolytic migratory erythema, subcutaneous lupus erythematosus, ichthyosis linearis circumflexa, granuloma annulare and borderline leprosy can be included in the differential diagnosis; these dermatoses can also largely be excluded on the clinical, histological, and laboratory evaluations. Thus, based on the

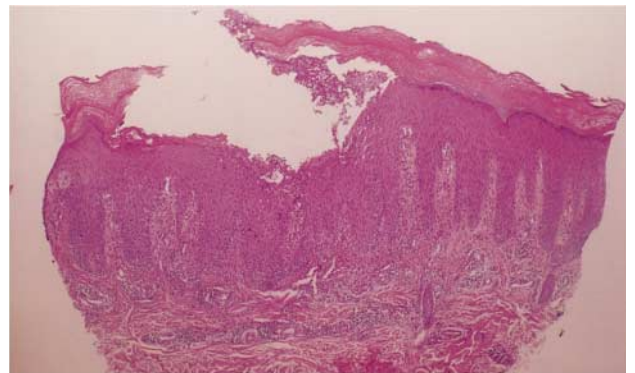


Fig. 2. Histology showing a large subcorneal neutrophilic aggregation with spongiosis, parakeratosis, hypogranulosis and elongation of rete ridges in the epidermis, and tortuous capillaries and perivascular lymphocytic inflammatory infiltrate in the papillary dermis (H & E,  $\times 100$ ).

recurrent clinical course and typical histological features, our case was finally diagnosed as pustular psoriasis, although the clinical feature was atypical.

Classification of pustular psoriasis is sometimes difficult (3). Our case could be distinguished from palmoplantar pustulosis and acrodermatitis continua. Her lesions resembled APP, which is a rare condition of recurrent erythema annulare-like lesions with psoriasiform histopathological features (1). Other names for APP are erythema circine recidivants (4), Lapière-type psoriasis (5), and erythema annulare centrifugum-type psoriasis (6). APP typically runs a cyclically recurrent course that may span decades (1). It may occur alone, in the complete absence of any stage of recognizable psoriasis and a family history of psoriasis vulgaris is usually absent. Lesions start as discrete areas of erythema that become raised and oedematous. Pustules begin peripherally on the crest of an advancing edge, become desiccated and leave a trailing fringe of scale as the lesion advances. Considering the clinical manifestation and course of the condition, our case is closer to APP than other types of pustular psoriasis. Although usually generalized, APP rarely occurs as a localized form. Zala & Hunziker (2) reported 2 cases of localized psoriasis of the erythema annulare centrifugum-type with pustulation; one on the scalp and forehead and the other on both thighs. However, to date, there has been no report of APP localized to the dorsa of the feet.

In the localized form of pustular psoriasis, the possible triggering factor of an irritating topical treatment may be of Koebnerization (7). Although in our case no triggering factors were identified, there might be a relationship to minor trauma or local irritants. The contribution of concomitant dermatophyte infection is unlikely, since organisms were not demonstrated on repeated KOH examination, fungal cultures, or PAS staining. Also the presence of coagulase-negative staphylococci grown in bacterial culture was not considered aetiological and it might be secondary to pustular formation and of little significance in our patient.

Localized pustular psoriasis is usually refractory to treat-

ment. Treatments include the use of topical steroids, tar preparation and systemic therapy with etretinate and PUVA (8). However, aggressive topical and phototherapeutic treatment modalities can lead to worsening of the condition. There have been some anecdotal reports of positive experiences with dapson (9). As in our patient, the benefits of such treatment are usually temporary and the lesions tend to recur with diminishing doses.

## REFERENCES

1. Baker H, Ryan TJ. Generalized pustular psoriasis: A clinical and epidemiological study of 104 cases. *Br J Dermatol* 1968; 80: 771–793.
2. Zala L, Hunziker T. Lokalisierte forms der Psoriasis vom typ des erythema annulare centrifugum mit pustulation. *Hautarzt* 1984; 35: 53–55.
3. Zelickson BD, Muller SA. Generalized pustular psoriasis: A review of 63 cases. *Arch Dermatol* 1991; 127: 1339–1345.
4. Basex A, Dupré A, Christol B, Jalby J. Psoriasis à type d'erythema circiné récidivant de Bloch. *Bull Soc Fr Dermatol Syphiligr* 1967; 74: 689–695.
5. Clavert HT. Pustular psoriasis (Type Lapière) – (Annular centrifugal psoriasis). *Br J Dermatol* 1967; 79: 719–721.
6. Rajka G, Thune PO. On erythema annulare centrifugum-type psoriasis. *Acta Derm Venereol (Stockh)* 1979; 59 Suppl 85: 143–145.
7. Quan MB, Ruben BS. Pustular psoriasis limited to the penis. *Int J Dermatol* 1996; 35: 202–204.
8. Farber EM, Nall L. Pustular psoriasis. *Cutis* 1993; 51: 29–32.
9. Piamphongsant T, Nimsuwan P, Gritiyarangsarn P. Treatment of generalized pustular psoriasis – clinical trials using different therapeutic modalities. *Clin Exp Dermatol* 1985; 10: 552–561.

*Accepted September 7, 1998.*

Young Min Park, Hoon Kang and Baik Kee Cho  
Department of Dermatology, Our Lady of Mercy Hospital, The Catholic University of Korea, 665 Bupyeong-dong, Bupyeong-gu, Incheon 403-016, Korea. Email: mrhoo@nuri.net.

## Cellular Neurothekeoma

*Sir,*

Cellular neurothekeoma (CNT) is a rare benign tumour of peripheral nerve sheath origin, first described in 1986 by Rosati et al. (1). The lesion usually occurs in young patients (20–30 years old) as a solitary nodule on the head. Its clinical aspect is aspecific resembling dermatofibroma, leiomyoma, annexal tumour or sebaceous cyst (2). The lesion arises as an asymptomatic red firm papule enlarging rapidly in the first 2–3 months and then more slowly until it reaches a diameter of about 3 cm. The treatment of choice is surgery; recurrences occur after incomplete excision. We report a case of a CNT which arose in a 55-year-old woman and we underline the rare occurrence of the tumour over the age of 30.

*Acta Derm Venereol (Stockh)* 79

## CASE REPORT

A 55-year-old woman was examined for an enlarging pink-red nodule on her left cheek (Fig. 1). The mass was scarcely movable on the underlying tissues and firm in consistency; its diameter was about 1 cm. The lesion was completely removed by surgery. Histological examination showed a symmetrical non-encapsulated proliferation of epithelioid or plump spindled cells in the dermis with a predominantly nested pattern. The nests dissected collagen bundles and epidermal appendages in the dermis and extended into the subcutis. The cells showed neither cytological atypia nor mitotic figures (Fig. 2). The epidermis was intact but a true grenz zone could not be detected because the nests were closely related to the dermo-epidermic junction. Periodic acid–Schiff staining failed to demonstrate the presence of mucin within the lobules. The following immunohistochemical stainings were performed