

## Cutaneous Sarcoidosis: Complete Remission after Oral Isotretinoin Therapy

S. GEORGIU, A. MONASTIRLI, E. PASMATZI and D. TSAMBAOS

Department of Dermatology, University of Patras, Rio-Patras, Greece

**We report a 31-year-old female patient with cutaneous sarcoidosis, who showed a complete remission of her single system skin disease after an 8-month therapy with oral isotretinoin (1 mg/kg/day). At 15-month follow-up, the patient still remained free of recurrence and visceral involvement. Key words: retinoids; skin; granuloma.**

(Accepted April 22, 1998.)

Acta Derm Venereol (Stockh) 1998; 78: 457–459.

S. Georgiou, Department of Dermatology, School of Medicine, University of Patras, P.O. Box 1413, GR-265 00, Rio-Patras, Greece.

Sarcoidosis is a multisystem disorder of unknown aetiology, most commonly affecting young adults and characterized by the occurrence of non-caseating epithelioid granulomas in all affected organs and distortion of normal tissue architecture (1, 2). The pathogenetic mechanisms of this disorder are far from being clearly understood; however, it is widely accepted that sarcoidosis may represent a macrophage-initiated and T-cell-mediated response to infectious antigens or autoantigens in genetically predisposed individuals (3–5). Skin involvement occurs in about 25% of the affected patients and may be the only manifestation of sarcoidosis (6). Diverse therapeutic approaches, including topical, intralesional and systemic steroids, antimalarials, methotrexate and thalidomide have been used in the management of cutaneous sarcoidosis, but no form of therapy has yielded consistently effective results (7–9).

We report herein a patient in whom treatment with oral isotretinoin resulted in a complete remission of cutaneous sarcoidosis.

### CASE REPORT

A 31-year-old HIV-negative Caucasian woman presented to our Department with a 3-year history of violaceous nodules and plaques on the trunk and extremities. The clinical diagnosis of sarcoidosis had been histologically confirmed. The response of her skin lesions to previously administered unknown dosages of intralesional (6 months) and oral steroids (10 months) was disappointing. A subsequent 3-month course of hydroxychloroquine (200 mg/day) had been ineffective. In the 10 months prior to her admission to our Department, she had received no therapy.

Physical examination of the patient was remarkable only for multiple violaceous nodules and plaques on the trunk, the arms, the thighs and the knees; over the joints, the skin lesions revealed a waxy appearance at their central part and a purplish rim at the periphery (Fig. 1a). Histological examination of formalin-fixed, paraffin-embedded biopsy specimens obtained from the lesional skin revealed multiple, sharply demarcated sarcoid granulomas in the papillary and middle dermis mainly consisting of epithelioid cells and several multinucleated giant cells, with no evidence of central necrosis. Examination of PAS- and Fite-stained sections failed to detect fungi or mycobacteria, respectively.

All results of routine laboratory investigations were within normal limits. Additionally, the serum levels of angiotensin converting enzyme (ACE), calcium,  $\beta_2$  microglobulin, gammaglobulins, immunoglobulins and the urine levels of calcium showed no abnormalities. A tuberculin skin test was negative. Chest and hand X-ray examination, pulmonary function tests, computed tomographic scan, ultrasound and ophthalmological examinations revealed no pathological findings.

Since both steroids and antimalarials had been ineffective in our patient, we decided to start a therapeutic trial with oral isotretinoin (Roaccutan, Roche Hellas S.A., Athens, Greece), considering the immunomodulatory effects of oral isotretinoin and the reported encouraging therapeutic results of this compound in cutaneous sarcoidosis (10, 11). Written consent was obtained from the patient subsequent to a thorough explanation of the possible therapeutic efficacy and toxicity of this retinoid.

Treatment was initiated with an oral isotretinoin dose of 1 mg/kg/day. About 3 weeks after the onset of treatment, no new lesions had developed, but the existing ones revealed no evidence of regression. Over the next 3 weeks the nodules and plaques started to flatten and fade. Further administration of the same isotretinoin dosage led to a gradual resolution of the skin lesions, which completely disappeared

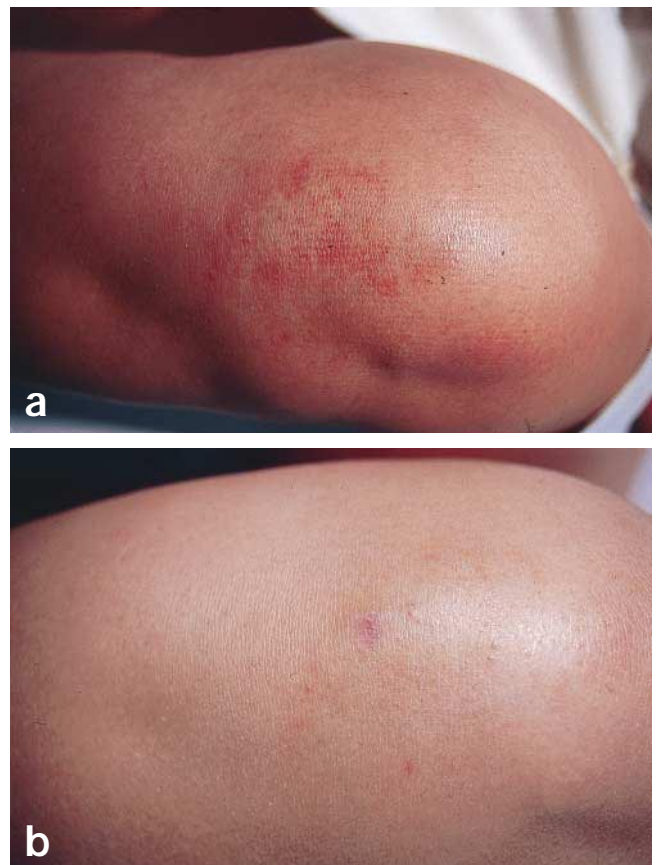


Fig. 1. Clinical aspect of skin lesions at the left knee before (a) and 15 months after (b) the start of therapy, showing only a residual hyperpigmentation.

8 months after the onset of the treatment (Fig. 1b). Post-treatment histological examination of biopsy specimens obtained from the lesional skin failed to reveal epithelioid granulomas or any evidence of sarcoidosis. Only a few lymphohistiocytic cells around the vessels of the papillary dermis could still be seen in the apparently normal skin. Apart from a moderate cheilitis, dryness of the nasal mucosa and xerosis, the drug was well tolerated; moreover, the results of the laboratory investigations remained within normal limits throughout the treatment period, and the tuberculin skin test remained negative. At 15-month follow-up our patient was and presently continues to remain free of recurrence and of visceral involvement.

## DISCUSSION

Oral isotretinoin represents an effective therapy for severe recalcitrant forms of acne, which is associated with predictable and mostly reversible adverse reactions (12, 13). Recent evidence suggests that, apart from the profound influence of isotretinoin on epithelial differentiation and proliferation, its immunomodulatory effects may also be involved in the mechanisms of its therapeutic action in acne and other cutaneous disorders (14–17).

The first clinical evidence that oral isotretinoin benefits patients with cutaneous sarcoidosis was reported in 1983 by Waldinger et al. (10). These authors treated a female patient suffering from chronic cutaneous and pulmonary sarcoidosis (unresponsive to oral corticosteroids) with 0.67–1.34 mg/kg/day oral isotretinoin over a period of 30 weeks. Interestingly, the skin lesions and the peripheral lymphadenopathy revealed a consistent improvement, whereas the pulmonary function tests remained unchanged. Moreover, the low WBC count and the increased serum ACE levels failed to become normal during the course of therapy.

Three years later (1986), Vaillant et al. (11) reported a female patient with cutaneous sarcoidosis unresponsive to oral corticosteroids, antimalarials and allopurinol. The response of the two skin lesions to a 6-month therapy with oral isotretinoin (0.4–1.0 mg/kg day) was favourable: one completely resolved and the other reduced considerably in size. However, isotretinoin therapy exerted no effect on the lymphopenia and the impaired proliferative response of T-lymphocytes to various mitogens, observed in their patient prior to the onset of the treatment.

To our knowledge, the patient described in the present paper is the first to reveal a complete remission of cutaneous sarcoidosis after oral isotretinoin therapy. The possibility that this impressive therapeutic response may represent a spontaneous remission of cutaneous sarcoidosis rather than a result of isotretinoin administration cannot be definitely ruled out. Nevertheless, in view of the 3-year duration of the therapy-resistant and progressive disease that responded to this retinoid within the first 6 weeks of treatment, this possibility seems very unlikely. Our findings confirm the observations of Waldinger et al. (10) and Vaillant et al. (11), and indicate that oral isotretinoin may be regarded as an effective and safe alternative therapeutic approach to the management of cutaneous sarcoidosis.

The mechanisms underlying the therapeutic action of isotretinoin in cutaneous sarcoidosis remain presently unknown; however, prostaglandin E<sub>2</sub> (PGE<sub>2</sub>) is known to inhibit granuloma formation in the animal models of sarcoidosis (18–20). Moreover, the release of this prostaglandin by macrophages in this disorder is markedly decreased (21). On the other hand, the tumour necrosis factor (TNF) is thought to be involved in the pathogenesis of sarcoidosis (22), since it plays a significant role

in experimental granuloma formation (23). Both its production by macrophages (24) and the plasma levels of their receptors (22) are markedly increased in this disease. It seems reasonable, therefore, to suggest that the ability of isotretinoin to stimulate the production of PGE<sub>2</sub> by macrophages (25) and/or to inhibit the production of TNF by these cells (26) and to down-regulate the cell surface expression of TNF receptors (27) might be of importance for the therapeutic action of this retinoid in cutaneous sarcoidosis.

## REFERENCES

- Lever WF, Schaumburg-Lever G. Non-infectious granulomas. In: Lever WF, Schaumburg-Lever G, eds. *Histopathology of the skin*. 7th ed. Philadelphia: Lippincott, 1990: 252–268.
- Crystal RG. Sarcoidosis. In: Wilson JD, Braunwald E, Isselbacher KJ, Petersdorf RG, et al., eds. *Principles of internal medicine*. 12th ed. 1991: 1463–1469.
- Galanaud P. The in vivo expression of cytokine genes in humans. *J Lipid Mediat Cell Signal* 1994; 9: 37–41.
- Garlepp MJ, Rose AH, Dench JE, Robinson BW. Clonal analysis of lung and blood T-cells in patients with sarcoidosis. *Thorax* 1994; 49: 577–585.
- Müller-Quernheim J. Immunologische Zellaktivierungen bei Sarkoidose: Immunpathogenetische und klinische Implikationen. *Immun Infect* 1995; 23: 80–85.
- Lessana-Leibowitch M, Monsuez JJ, Noble JP, Sedel D, Cadot M, Hewitt J. Manifestations cutanées de la sarcoidose. *Ann Med Interne* 1984; 135: 97–101.
- Siltzbach LE, Teirstein AS. Chloroquine therapy in 43 patients with intrathoracic and cutaneous sarcoidosis. *Acta Med Scand Suppl* 1964; 425: 302–306.
- Veien NK, Brodthagen H. Cutaneous sarcoidosis treated with methotrexate. *Br J Dermatol* 1977; 97: 213–216.
- Muthiah MM, Macfarlane JT. Current concepts in the management of sarcoidosis. *Drugs* 1990; 40: 231–237.
- Waldinger THP, Ellis CHN, Quint K, Voorhees JJ. Treatment of cutaneous sarcoidosis with isotretinoin. *Arch Dermatol* 1983; 119: 1003–1005.
- Vaillant L, Le Marchand D, Bertrand S, Grangeponde MC, Lorette G. Sarkoidose cutanée annulaire du front: traitement par isotretinoïne. *Ann Dermatol Venereol* 1986; 113: 1089–1092.
- Peck GL, Olsen TG, Yoder FW, Strauss JS, Downing DT, Pandya M, et al. Prolonged remissions of cystic and conglobate acne with 13-cis retinoic acid. *N Engl J Med* 1979; 300: 329–333.
- Tsambaos D, Orfanos CE. Chemotherapy of psoriasis and other skin disorders with oral retinoids. In: Baden HP, ed. *The chemotherapy of psoriasis*. International encyclopedia of pharmacology and therapeutics. New York: Pergamon Press, 1984: 287–308.
- Sidell N, Connor MJ, Chang B, Lowe NJ, Borok M. Effects of 13-cis retinoic acid therapy on human antibody responses to defined protein antigens. *J Invest Dermatol* 1990; 95: 597–602.
- Prabhala RH, Garewal HS, Hicks MJ, Sampliner RE, Watson RP. The effects of 13-cis retinoic acid and beta-carotene on cellular immunity in humans. *Cancer* 1991; 67: 1556–1560.
- Tsambaos D, Zimmermann B. Effects of synthetic retinoids on cellular systems. In: Roenigk H, Maibach H, eds. *Psoriasis*. 2nd ed. New York: Marcel Dekker, 1991: 659–707.
- Chaidaroglou A, Degiannis D, Koniavitou K, Georgiou S, Tsambaos D. In vitro effects of retinoids on peripheral blood leukocyte response to mitogens. *Arch Dermatol Res* 1998; 290: 205–210.
- Bonta IL, Parnham MJ. Macrophages as targets of inhibitory effects of E-type prostaglandins in immune-related inflammation. *Agents Actions* 1981; 11: 594–597.
- Kunkel SL, Fantone JC, Ward PA, Zurier RB. Modulation of

- inflammatory reactions by prostaglandins. *Prog Lipid Res* 1982; 20: 633–640.
20. Chensue SW, Kunkel SL, Ward PA, Higashi GI. Exogenous administered prostaglandins modulate pulmonary granulomas induced by *Schistosoma mansoni* eggs. *Am J Pathol* 1983; 111: 78–87.
  21. Wolter NJ, Kunkel WL, Lynch JP, Ward PA. Production of cyclooxygenase products by alveolar macrophages in pulmonary sarcoidosis. *Chest* 1983; 83 (Suppl): 79–81.
  22. Nakayama T, Hashimoto S, Amemiya E, Horie T. Elevation of plasma-soluble tumour necrosis factor receptors (TNF-R) in sarcoidosis. *Clin Exp Immunol* 1996; 104: 318–324.
  23. Shikama Y, Kobayashi K, Yamagata N. Augmentation of pulmonary foreign body granulomatous inflammation in mice by lipopolysaccharide: involvement of macrophage activation and tumor necrosis factor- $\alpha$ . *Am J Pathol* 1989; 134: 1189–1199.
  24. Terao I, Hashimoto S, Horie T. Effect of GM-CSF on TNF-alpha and IL-1 beta production by alveolar macrophages and peripheral blood monocytes from patients with sarcoidosis. *Int Arch Allergy Immunol* 1993; 102: 242–248.
  25. Levine L, Ohuchi K. Retinoids as well as tumor promoters enhance deacylation of cellular lipids and prostaglandin production in MDCK cells. *Nature* 1978; 276: 274–275.
  26. Mehta K, McQueen T, Tucker S, Pandita R, Aggarwal BB. Inhibition by all-trans-retinoic acid of tumor necrosis factor and nitric oxide production by peritoneal macrophages. *J Leukoc Biol* 1994; 55: 336–342.
  27. Totpal K, Chaturvedi MM, La Pushin R, Aggarwal BB. Retinoids downregulate both p60 and p80 forms of tumor necrosis factor receptors in human histiocytic lymphoma U-937 cells. *Blood* 1995; 85: 3547–3555.