

## Subclinical Joint Involvement in Psoriasis: Magnetic Resonance Imaging and X-ray Findings

ANNAMARIA OFFIDANI<sup>1</sup>, ANDREINA CELLINI<sup>1</sup>, GIANLUCA VALERI<sup>2</sup> and ANDREA GIOVAGNONI<sup>2</sup>

Departments of <sup>1</sup>Dermatology and <sup>2</sup>Radiology, University of Ancona, School of Medicine, Ancona, Italy

Previous studies have shown that magnetic resonance imaging is more sensitive in assessing soft tissue and bone involvement in inflammatory arthritis than conventional radiography. Therefore the main objects of this study were to evaluate the frequency of hand involvement in psoriatic patients free from arthritic symptoms, and to compare the results with those of a healthy control population (age- and sex-matched). Twenty-five patients suffering from active nummular and/or plaque psoriasis with no arthritic signs or symptoms were studied together with 12 healthy control subjects. The articular structures of both hands in all patients were screened using both traditional radiological techniques and magnetic resonance imaging. Specifically, we examined: soft tissue swelling, periarticular effusion, joint effusion-synovial pannus, tendon sheath effusion, bone erosion, luxation, sub-luxation, bone cysts and subchondral signal intensity abnormalities.

Sixty-eight percent of our psoriatic patients were found to be positive with at least one arthritic sign using magnetic resonance imaging, while with the standard X-ray procedure, only 32% of the same group of patients were found to be positive. Specifically, abnormal signal intensity in the subchondral focal areas were seen in 9 patients using the magnetic resonance imaging technique, while in the control group, no significant abnormalities were detected.

A high percentage of psoriatic patients without apparent arthritic signs and symptoms were shown to have hand articular involvement, in particular in the distension of the capsular and periarticular oedema when examined with magnetic resonance imaging. In our experience, the use of magnetic resonance imaging allows a clear and adequate evaluation of the cartilage, bone and soft tissue material, and is diagnostically superior to X-ray in demonstrating clinically silent and radiologically invisible articular lesions. Moreover, the subchondral changes detected by magnetic resonance imaging were unexpected findings which could imply an ischaemic origin. *Key words: magnetic resonance imaging; psoriatic arthritis; X-ray exam; psoriasis; joint.*

(Accepted April 20, 1998.)

Acta Derm Venereol (Stockh) 1998; 78: 463–465.

A. Offidani, Department of Dermatology, Umberto I Hospital, piazza Cappelli 1, I-60100 Ancona, Italy.

Psoriasis vulgaris is not infrequently accompanied by an inflammatory sero-negative arthritis or psoriatic arthritis (PA). There is no firm agreement on the incidence of arthritis; it is often reported to be around 5–7%, but there are some authors who report the much higher figure of 30–40% (1–3). Skin and/or nail psoriatic involvement cannot be regarded as an indicator or a predictable diagnostic marker of PA, since PA is sometimes seen without skin involvement. PA is, in fact, considered to precede skin psoriasis in about 15% of cases (4).

However, there is no correlation between the severity of the skin manifestation and the degree or frequency of joint involvement.

Conventional radiology is only able to demonstrate changes in the joints where the disease is already manifest. Bone scintigraphy can reveal multiple joint arthritic changes in the psoriatic patient who has never had any arthritic symptoms. Magnetic resonance image (MRI) has already been proven to be useful in detecting soft tissue changes and bone involvement in PA, and therefore to be of superior diagnostic ability than the conventional X-ray (5, 6).

The main objects of this study were to evaluate the frequency of joint involvement of the hand assessed by MRI in psoriatic patients free from arthritic symptoms, and to compare the MRI findings with these of the roentgenograms.

### MATERIAL AND METHODS

Twenty-five consecutive patients without symptomatic joint involvement and 12 healthy control subjects were studied. The 25 psoriatic patients (18 men, 7 women, mean age  $39.6 \pm 16.2$  years, range 15–69) were all affected by active nummular and/or plaque psoriasis to different extents, ranging from 20–50% body surface area involvement. The onset of psoriasis varied from 1 month to 10 years. All patients met the following requirements:

1. None had received systemic chemotherapy or photochemotherapy for psoriasis.
2. They were all sero-negative for rheumatoid factor.
3. All were examined by an experienced rheumatologist to rule out the existence of clinical arthropathy.

The control group of 12 healthy subjects of comparable mean age and sex also met the above requirements.

All patients and controls underwent both a conventional radiological assessment and an MRI hand examination on the same day. Plain radiographs of the hands were taken from the postero-anterior and oblique views. MRI examinations were carried out using a superconductive magnet 1.0 T (Magnetom and Impact, Siemens, Erlang, Germany) with a round surface coil, 16 cm in diameter: Spin-echo (SE) T1-weighted (T1W, TR 480 ms, TE 15 ms) and gradient echo ((FLASH) T2\*-weighted (T2W), TR 400 ms; TE 18ms; flip angle 20°) sequences on the coronal and sagittal planes were acquired. The slice thickness was 3–4 mm, matrix 220–256 and the field of view (FOV) 12–15 cm (two acquisitions). Intravenous contrast agents were not used in our study.

Evaluation of all radiological findings was performed by two experienced skeletal radiologists who were blinded from all clinical information.

A semi-quantitative evaluation of the following soft tissues and joint abnormalities was performed as previously reported (7): periarticular oedema, peritendon sheath effusion, intra-articular effusion-synovial pannus, bone erosion, bone cysts, subchondral changes and joint subluxation and luxation.

The radiological and MRI score for joint or soft tissue abnormalities was based on a visual analysis and included 5 grades (0: normal, 1: questionable, 2: mild, 3: moderate and 4: severe). Intra-articular effusion and synovial pannus abnormalities were considered a single alteration when seen on MRI. In the absence of an IV contrast agent, differentiation between these two lesions is virtually impossible.

Table I. Results of soft tissue and bone changes seen by MRI and X-ray examinations in psoriatic patients. Periarticular and intra-articular effusions were not distinct on X-ray; therefore they were considered together as "soft tissue" swelling. Similarly in unenhanced MRI, it was not possible to distinguish intra-articular effusion from synovial pannus proliferation. Thus they were subsequently considered together as "joint effusion-pannus".

Diagnosis	MRI		X-ray	
	Number of points	%	Number of points	%
Soft tissue swelling			4	16
Periarticular effusion	9	36	nd	–
Joint effusion-synovial pannus	11	44	nd	–
Tendon sheath effusion	2	8	0	0
Bone erosion	7	28	5	20
Luxation/subluxation	4	16	3	12
Bone cysts	7	28	5	20
Subchondral SI abnormalities	9	36	0	0

## RESULTS

The MRI results as compared to conventional X-ray results in the evaluation of psoriatic patients and the control population are as follows. In the psoriatic patients, 68% were found to be positive with one or more arthritic signs using MRI, but using the standard X-ray procedure, the figure for the same group of patients was only 32%. Only one control subject was found to have a joint cyst.

The imaging details were analysed separately. The MRI and X-ray results are reported in Table I. Capsular distension, considered to have been caused by a synovial pannus and/or articular effusion (Fig. 1), was the most common soft tissue abnormality observed with MRI in 11/25 (44%) of the patients. Using the same diagnostic procedure, 9 patients (36%) (Fig. 2) were seen to have diffuse periarticular oedema (in one case it was moderate, but in the others, mild). Furthermore, MRI showed 2 (8%) psoriatic patients to be suffering from a mild tendon sheath effusion.

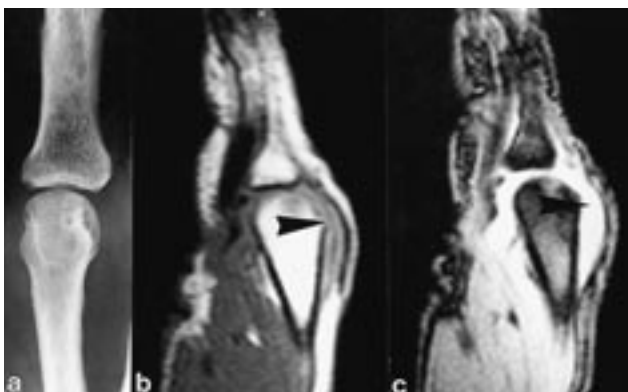


Fig. 1. (a) The radiography of the III metacarpo-phalangeal shows a joint effusion; however, it is not clear if there is also periarticular involvement. (b), (c) The MR images show mild distension (arrows) of the III metacarpo-phalangeal joint without subcutaneous and tendon involvement.

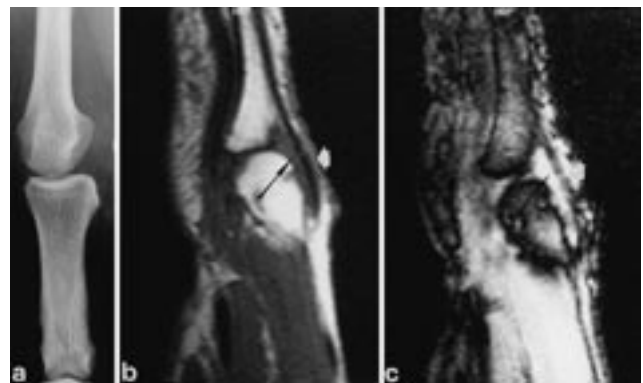


Fig. 2. (a) The radiography of the IV metacarpo-phalangeal shows a joint effusion; however, it is not clear if there is also periarticular involvement. (b), (c) The MR images show a periarticular effusion (black arrows) with subcutaneous fat involvement (white arrows), hypointense in the T1W sagittal section (b) and hyperintense in the T2W (c).

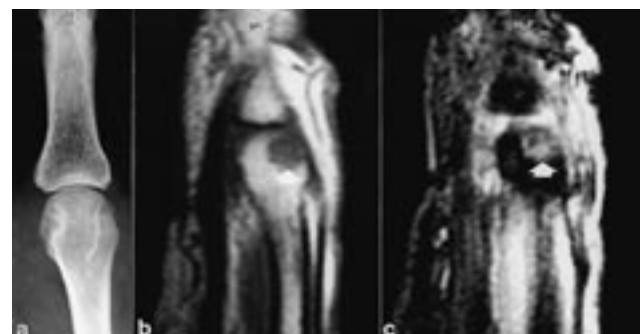


Fig. 3. (a) The radiography of the III metacarpo-phalangeal joint does not show any abnormality. (b), (c) The MR images show a subchondral focal area of signal change (arrows) in the metacarpal epiphysis, hypointense in the T1W sagittal section (b) and hyperintense in the T2W (c).

In the same patients, conventional radiology was only able to demonstrate a soft tissue swelling in 4/25 (16%).

The periarticular and intrarticular effusions were not clearly seen on the X-rays (and therefore were considered part of the soft tissue swelling in 4/25 cases). In 28% of psoriatic patients, MRI recorded metacarpophalangeal and interphalangeal joint erosion, whilst with standard X-ray, the figure was only 20%. Using MRI, cystic lesions and subluxation were more frequently seen (Table I). MRI of the metacarpal heads, phalangeal epiphysis and carpal bone showed altered signal intensity of the subchondral focal areas in 9 (36%) psoriatic patients (Fig. 3), which was not seen with the conventional X-ray. No correlation was found between MRI detected abnormalities, severity of skin involvement and age of onset of the disease.

## DISCUSSION

Previous studies have shown that MRI is more sensitive than conventional radiography in assessing soft tissue and bone involvement in inflammatory arthritis (7, 8). In our study, we used MRI to evaluate whether this technique was capable of disclosing the subclinical PA that could be missed by conventional radiogram – the results were unexpected.

MRI of the hands allowed us to perform an adequate evaluation of cartilage, bone and soft tissue involvement. This technique proved to us that in psoriatic patients without clinically evident arthritis, there was frequent involvement of joints. These findings confirmed that MRI is more sensitive in detecting soft tissue changes when compared to conventional radiograms.

In psoriatic patients, a periarticular high signal intensity was found, which suggests the presence of inflammatory oedema. This finding, in our experience, is unique in this disease, and could be related to the so-called "sausage digits" seen in PA.

The two radiological techniques employed did not show important differences in detecting bone erosions and cysts. This is probably attributable to the fact that the enrolled population had no joint symptoms.

We would like to underline the importance of the findings related to the subchondral abnormalities detected by MRI in psoriatic patients. The cause of this MRI feature was not clarified. Histological evaluation might have been valuable but, of course, it was not performed in our asymptomatic patients.

Structural bone changes within the subcortical and subperiosteal bone, such as high turnover remodelling osteopathy, have already been shown to be present in PA (9, 10, 11). However, signal intensity abnormalities in subchondral bone MRI detected as a hypointense area on T1W and hyperintense on T2\*, may suggest an ischaemic origin. This sign, although non-specific, to our knowledge has never been described in any other arthropathy (5).

In conclusion, MRI showed joint and periarticular soft tissue abnormalities in a higher percentage of psoriatic patients without clinically evident arthritis than conventional radiography. MRI, according to our findings, can be a useful tool in detecting soft tissue and bone changes in these kinds of patients.

## ACKNOWLEDGEMENTS

The authors thank Professor Armando Gabrielli for the rheumatologic evaluation of our patients.

## REFERENCES

1. Leczinsky CG. The incidence of arthropathy in ten-year series of psoriasis cases. *Acta Derm Venereol (Stockh)* 1948; 28: 483–487.
2. Hellgren L. Association between rheumatoid arthritis and psoriasis in total populations. *Acta Rheum Scand* 1969; 15: 316–326.
3. Block SR. Psoriatic arthritis. *J Maine Med Assoc* 1979; 70: 326–329.
4. Wright V. Skin and arthritis. *Clin Exp Rheumatol* 1987; 5 (Suppl 1): 75–79.
5. Giovagnoni A, Grassi W, Terilli F, Blasetti P, Paci E, Ercolani P, et al. MRI of the hand in psoriatic and rheumatoid arthritis. *Eur Radiol* 1995; 5: 590–595.
6. Coari G, Iagnocco A, Mastrantuono M, De Cata A, Persia S, Passariello R, et al. Sonographic and NMR imaging study of sausage digit. *Acta Derm Venereol (Stockh)* 1994; Suppl 186: 33–34.
7. Corvetta A, Giovagnoni A, Baldelli S, Ercolani P, Pomponio G, Luchetti MM, et al. MR imaging of rheumatoid hand lesions: comparison with conventional radiology in 31 patients. *Clin Exp Rheumatol* 1992; 10: 217–222.
8. Senac MO Jr, Deutsch D, Berstein BH, Stanley P, Crues JV III, Stoller DW, et al. MR imaging in juvenile rheumatoid arthritis. *AJR* 1988; 150: 873–878.
9. Holzmann H, Hoede N, Eißner D, Hahn K, Hülse R. Joint involvement in psoriasis. *Arch Dermatol Forsch* 1974; 250: 95–107.
10. Loebl DH, Kirbi S, Stephenson R, Cook E, Mealing HG, Bailey JP. Psoriatic arthritis. *JAMA* 1979; 242: 2447–2459.
11. Hein G, Abendroth K, Muller A, Wessel G. Studies on psoriatic osteopathy. *Clin Rheumatol* 1991; 10: 13–17.