

Langerhans' Cells and Lymphocytic Infiltrate in AIDS-associated Kaposi's Sarcoma

An Immunohistochemical Study

F. VALCUENDE-CAVERO¹, M. I. FEBRER-BOSCH² and A. CASTELLS-RODELLAS³

¹ Dermatology Unit, Service of Internal Medicine, Hospital Gran Vía, Castellón, ² Department of Dermatology, Hospital General, Valencia and ³ Service of Dermatology, Hospital General Vall d'Hebron, Barcelona, Spain

The epidermal Langerhans' cells are dendritic cells of the skin capable of triggering cutaneous immune responses. They possess the membrane antigens required to this effect: class II histocompatibility antigen, CD1a and CD4; the latter acts as receptor for the human immunodeficiency virus. The skin is the organ primarily affected by Kaposi's sarcoma (KS). In epidemic KS, the local immunologic conditions of the skin are little known. We therefore studied 12 patients with AIDS-associated KS, evaluating the density and phenotypic expression in KS-affected and unaffected skin of the following antigens: CD1a, HLA-DR, CD4 in dendritic epidermal cells and dermis, and CD3, CD4 and CD8 in cells of the inflammatory infiltrate, using monoclonal antibodies applied to frozen sections with the avidine-biotin-peroxidase technique. Langerhans' cells in the AIDS-KS skin lesions were found to be decreased in number. This decrease was even more pronounced in the case of cells expressing HLA-DR antigen. A number of them were also revealed with CD4. The tumour lymphocytic infiltrate was almost exclusively composed of CD3+ CD8+ phenotype lymphocytes. The dermis also revealed CD4+ dendritic cells. The basal keratinocytes focally expressed HLA-DR. These phenotypical alterations of the Langerhans' cells and the local immunological imbalance observed may contribute to the growth and continuity of the KS lesions. *Key words: skin neoplasms; human immunodeficiency virus; monoclonal antibodies; dendritic cells.*

(Accepted October 18, 1993.)

Acta Derm Venereol (Stockh) 1994; 74: 183–187.

F. Valcuende-Cavero, Unidad de Dermatología, S. de Medicina Interna, Hospital Gran Vía, 12006 Castellón, Spain.

Kaposi's sarcoma (KS) is a multifocal neoplasm of endothelial origin that frequently develops in the course of AIDS. The predominance of KS lesions in the skin suggests the existence of local factors that favour their growth. The local immunological conditions in KS have not previously been investigated. The skin contains dendritic cells with antigen-presenting capacity, which are Langerhans' cells (LC). Moreover, a small number of lymphocytes continuously enter and leave the skin. Antigenic challenge triggers a chain reaction that on the one hand recruits inflammatory cells and on the other leads to cytokine secretion (1). An immunological impairment causing an imbalance in the cell population involved in this type of response may alter cytokine production and thus facilitate KS proliferating tumour cell overgrowth.

The LC are antigen-presenting cells of the skin that initiate the antigen-specific effector defense mechanism, in close coordination with other immune cells. In the course of AIDS, the LC are decreased in number, and it has been shown that they

may constitute HIV targets of infection (2). Thus, the investigation of LC density and phenotype appears to be of interest in KS-AIDS affected skin, along with the analysis of corresponding lymphocyte distribution and subpopulations.

MATERIAL AND METHODS

Patients and specimens

In 12 patients (11 males and 1 female) with KS-AIDS 12 biopsies of affected skin and 8 samples of apparently healthy perilesional skin were taken. In all cases the diagnosis of AIDS was based upon CDC criteria: antibodies to HIV-1, low total CD4 cell count – mean $0.242 \times 10^9/l$ – and CD4/CD8 ratio decreased to 0.35. Patient evolution has been followed for 18 months (3). None of the patients had received treatment prior to biopsy. Each biopsy specimen was cut into two portions, one of which was snap-frozen in liquid nitrogen and stored at -80°C . The other was fixed in 10% buffered formalin and routinely processed for hematoxylin-eosin staining.

Controls

Ten specimens were obtained, from normal skin of Caucasian non-AIDS healthy patients, at routine biopsy performed on intradermal naevi and small cyst, removed from the face or trunk, for cosmetic reasons. They were also snap-frozen and were employed as positive controls.

Table I. Results obtained with monoclonal antibody labelling

RC = rounded cells; DC = dendritic cells. Semiquantitative value is expressed on a "+" scale: +/- = 0–5 labelled cells per linear mm of epidermis or 0–25% positive cells in dermis; + = 5–10 labelled cells per linear mm of epidermis or 25–50% positive cells in dermis; ++ = 10–20 labelled cells per linear mm of epidermis or 50–75 positive cells in dermis; +++ = 20–30 labelled cells per linear mm of epidermis or >75% positive cells in dermis; ++++ = >30 labelled cells per linear mm of epidermis.

	CD1	HLA-DR	CD3	CD4	CD8
<i>Controls</i>					
Epidermis	++++	++++	–	–	–
Dermis	–	+/-	+/-	+/-	+/-
<i>Perilesional skin</i>					
Epidermis	++	+	–	+/-	–
Dermis	+/-	+/-	+	RC– DC+/-	+
<i>Kaposi's sarcoma</i>					
Epidermis	+/-	-/+	–	DC-/+	–
Dermis	-/+	+++	++	RC– DC+ RC+/-	RC++

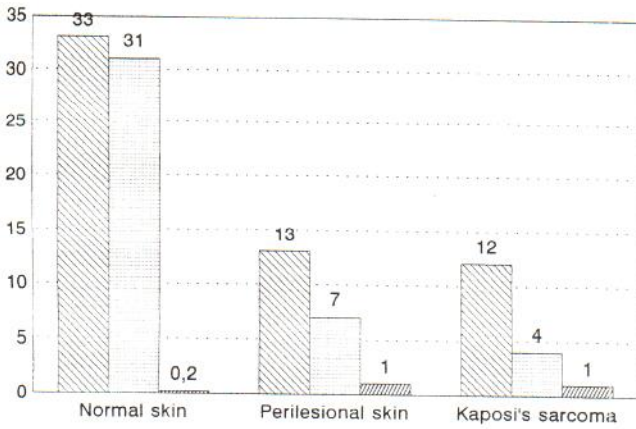


Fig. 1. Dendritic cell labelling within the epidermis. ● CD1a, ▨ HLA-DR, ■ CD4.

Monoclonal antibodies and other reagents

Monoclonal antibodies used in the study were: OKT3 (CD3), OKT4 (CD4), OKT6 (CD1a), OKT8 (CD8) (Ortho Diagnostics, New Jersey, USA) and anti-HLA-DR (Becton Dickinson, USA).

Other reagents used were phosphate buffered saline (PBS) (Bio-Merieux, France), avidin-biotin peroxidase system (Vectastain ABC kit, Vector, Burlingame, USA), 3 amino-9-ethylcarbazole (Sigma, St. Louis, USA).

Immunohistochemical staining

Cryostat sections (4 µm thick) were cut from each frozen specimen and processed according to routine protocol in our laboratory (4). Briefly, after blocking non-specific staining the sections were incubated with the monoclonal antibody (45 min), a biotinylated anti-mouse IgG (45 min) and an avidin-biotin peroxidase complex (60 min). Between steps, all sections were rinsed with PBS solution. Peroxidase reactions were

demonstrated by 3 amino-9-ethylcarbazole. The sections were counterstained with Mayer's hematoxylin and mounted in gelatin/glycerin medium. Control slides were included in each reaction. Negative control slides were obtained by omitting the monoclonal antibody and were consistently negative.

Counts were performed with micrometer fitted optics of the number of labelled cells per linear mm of epidermis, and of the positive dermal cells per mm². Cell location was indicated, distributing the cells into predominance percentages corresponding to one subtype or another. Predominance of one cell type over another by more than 25% was taken into account.

RESULTS

The results obtained are presented in Table I and Fig. 1.

Controls

At epidermal level the mean CD1a+ LC density per linear mm was 33/mm (range, 25–37). The mean number of HLA-DR positive cells was very similar: 31/mm. The number of CD3, CD4 or CD8 lymphocytes within the epidermis was very low; CD3+ and CD4+ cells were only occasionally seen (under 5/mm), while CD3+ CD8+ cells were exceptional.

The dermis was CD1a negative. As to anti-HLA-DR, labelled cell groups corresponding to vessels were seen. In the present study note was only taken of isolated positive cell counts. A number of rounded cells were isolatedly CD3+, in the dermis in proximity to blood vessels. Most of the CD3+ cells were also CD4+. CD8 positivity was only occasionally seen.

Healthy perilesional skin

At epidermal level CD1a positive dendritic cells were fewer than in the controls (mean 13/mm; range 10–19). The HLA-DR

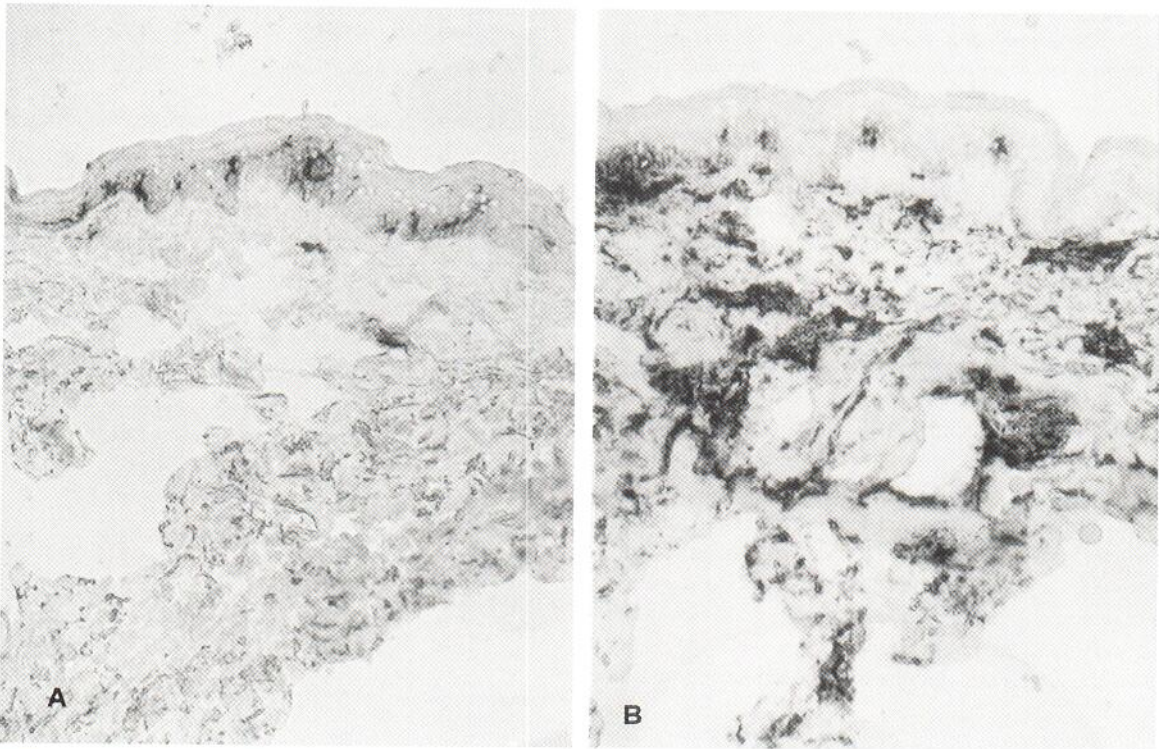


Fig. 2. Healthy perilesional skin of Kaposi's sarcoma. Original magnification 100×. (A) CD1a positive dendritic cells in epidermis and dermis. (B) HLA-DR positive dendritic cells in epidermis are fewer than CD1a+ cells. At dermal level, vessels, rounded cells around vessels and dendritic cells are HLA-DR positive.

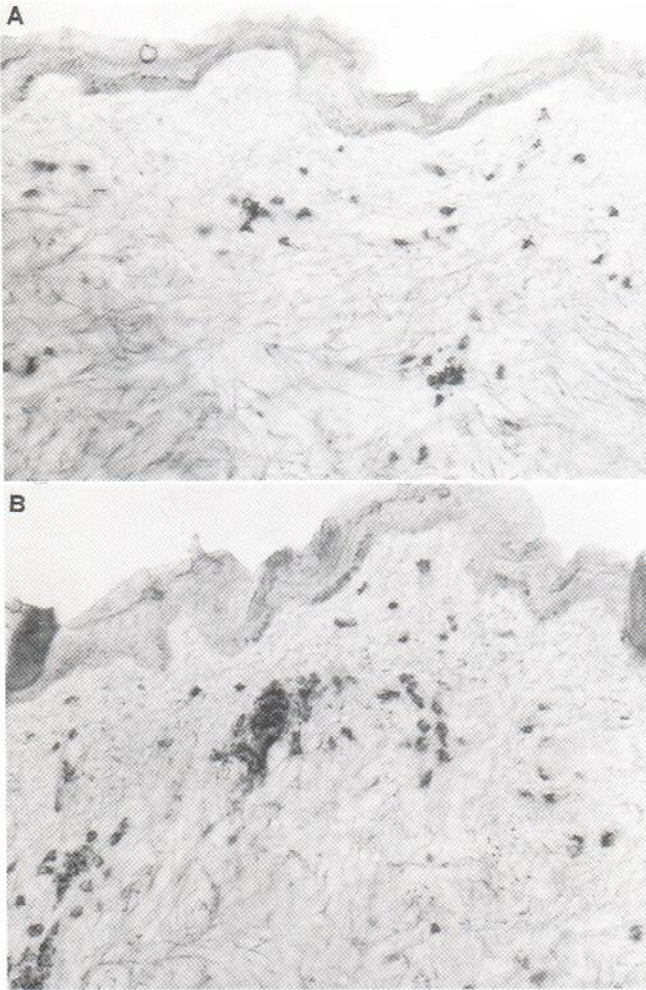


Fig. 3. Healthy perilesional skin of Kaposi's sarcoma. Original magnification 100 \times . (A) CD4 positive cells are seen within the interstice. They are fewer than those positive to CD8 (B).

positive dendritic cells were even fewer (mean 7/mm; range 5–10). CD4⁺ dendritic cells were fewer than those positive to CD1a and anti HLA-DR (mean 1/mm; range 0–4). HLA-DR positive basal keratinocyte foci were noted (Fig. 2).

The dermis presented occasional CD1a positive dendritic cells (0–3/mm²). As to anti-HLA-DR, endothelial labelling predominated. The dermal interstice exhibited elongated dendritic-like cells. Labelled rounded cells were also seen, particularly in the vicinity of vessels and appendages. Small groups of rounded CD3⁺ cells were observed around vessels and deep appendages. Only occasional rounded cells were CD4⁺. Most CD3⁺ cells were also CD8⁺. (Fig. 3). A number of dendritic and fusiform CD4⁺ cells were seen in the vicinity and distributed within the interstice.

KS lesions

At epidermal level CD1a positive dendritic cells were fewer than in normal skin (mean 12/mm; range 5–20). Only a minority of these cells were HLA-DR positive (mean 4; range 2–7); some were in turn also CD4⁺ (mean 1; range 0–4). Rounded CD3⁺ and CD8⁺ cells were seen in small clusters within the basal

layer. Groups of keratinocytes within the basal and suprabasal layers were found to be HLA-DR positive.

The dermis presented CD1a positive dendritic cells in the superficial dermis, while practically the entire tumour mass was positive for HLA-DR (Fig. 4). Rounded CD3⁺ cells were seen dispersed and in clusters within the superficial dermis and around sweat glands and hair follicles. As to CD4 labelling, practically none of the rounded cells proved positive. On the contrary, a great many dendritic and fusiform cells were CD4⁺ (Fig. 5). Finally, abundant CD8⁺ cells were seen within the interstice both isolatedly and in clusters surrounding deep appendages and in the superficial dermis. (Fig. 6).

DISCUSSION

Kaposi's sarcoma is a multifocal neoplasm with angioproliferative characteristics, which often arises in the course of AIDS. The mechanism by which KS develops in patients with AIDS is not clear, however. The human immunodeficiency virus itself is not detected within the proliferating cells (5). Studies of experimentally induced KS in mice transgenic for the HIV "tat" gene (6) have revealed that the products of this gene are located in the epidermis overlying the KS lesion, and not in the lesion itself. Within the epidermis, the only HIV receptor-presenting immunocompetent cells are the Langerhans' cells; these are dendritic cells which play a major role in the immune responses taking place in the skin. Under normal conditions, the LC express class II histocompatibility antigen (HLA-DR), CD1a and CD4. The latter is the molecule acting as HIV receptor. It has been shown that HIV is able to infect and replicate within these cells (7). As a result of infection, the LC decrease in number, and some exhibit cytopathological modifications (2). The controversial results reported in the literature (8–10) regarding observed LC density may be due to differences in HIV infection intensity or duration. In our patients we encountered a clearly diminished LC population, and an important immunodeficiency was already apparent in almost all cases. Six of the 12 patients suffered opportunistic infections, and 5 died during the 18-month follow-up period (3). In addition to the decrease in LC within the epidermis, we observed a change in the immunophenotype of these cells. Thus, HLA-DR expression was diminished with respect to the number of CD1a positive cells. In functional terms, this alteration implies a decrease in antigen-presenting capacity and leads to differentiation inversion (11).

Under normal conditions, the LC also express CD4, but in such minute amounts that detection is only possible with gold-immune electron microscopic techniques (12). The application of immunohistochemical methods in our laboratory did not enable us to detect CD4 in intraepidermic dendritic cells under the light microscope (13). On the other hand, perilesional epidermis and that overlying KS lesions exhibited CD4 positive dendritic cells that possibly corresponded to increased CD4 expression on the part of the LC. Although immunohistochemistry cannot provide actual numerical values as regards the number of receptors, this positivity seems to reflect a true increase in CD4 on the part of the LC of these lesions. Gielen et al. (14) carried out gold-immune electron microscopic studies of the density of this antigen in HIV-infected patients. They found

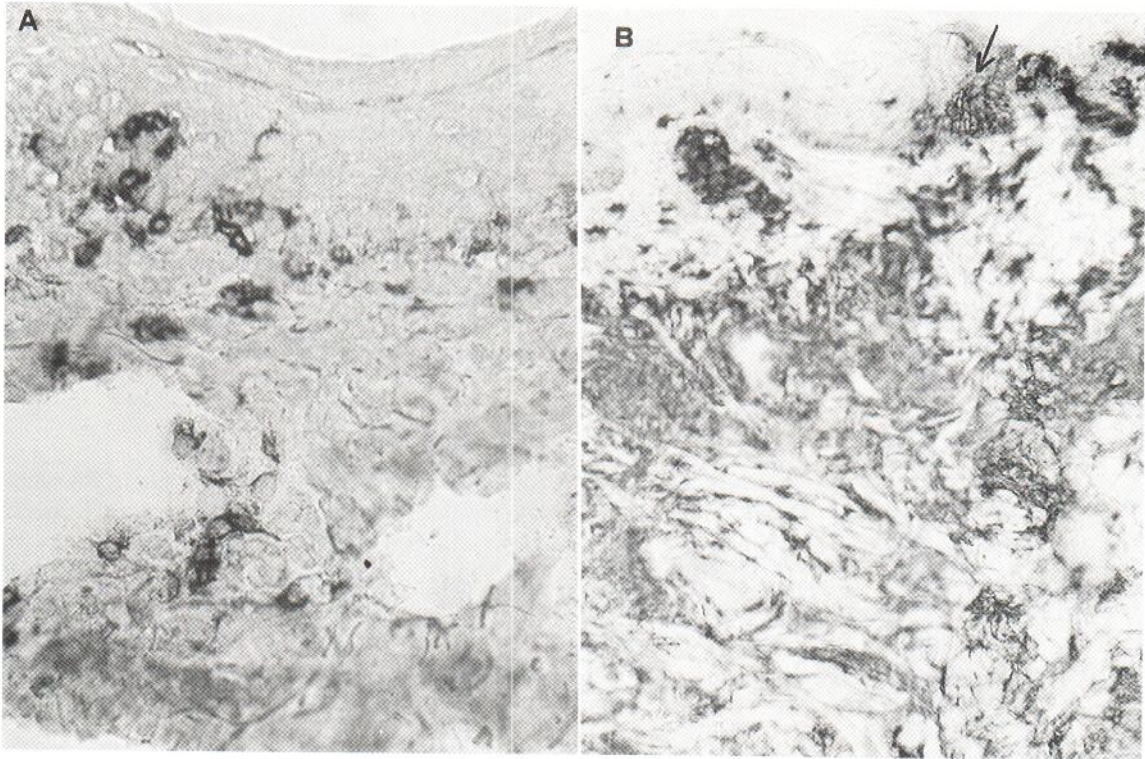


Fig. 4. Kaposi's sarcoma lesions. (A) CD1a+ dendritic cells are seen in epidermis and within the tumour. Original magnification 400x. (B) The tumour is positive to HLA-DR. At epidermal level HLA-DR + dendritic cells are only occasionally seen. Groups of keratinocytes are HLA-DR positive (arrows). Original magnification 250x.

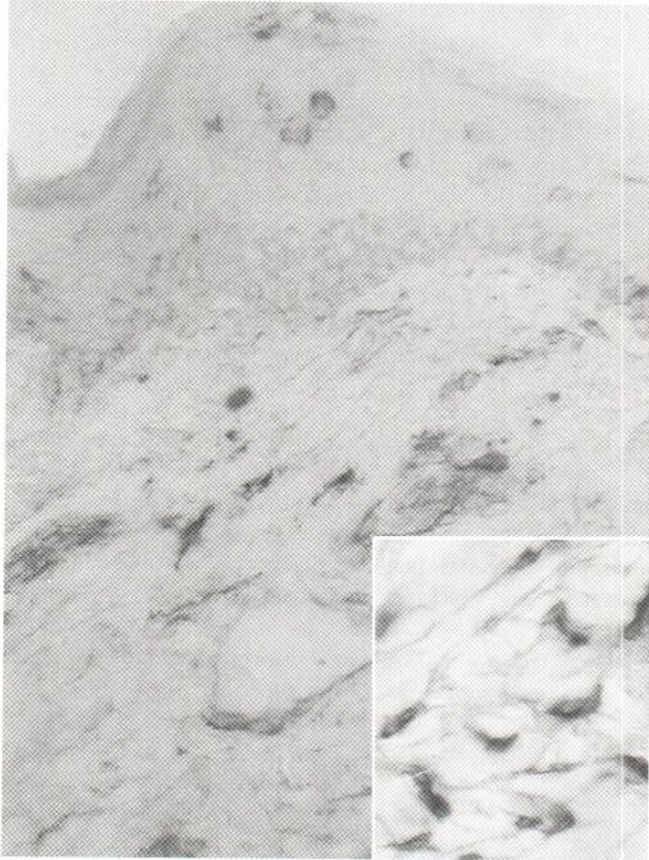


Fig. 5. Kaposi's sarcoma lesions. At epidermal level CD4 positive dendritic cells are seen. Original magnification 400x. Dendritic and fusiform cells are CD4 positive within the tumour (bottom).

that although in most cases HIV infection involves a decrease in LC CD4 expression, a subgroup of pre-AIDS HIV-positive patients exhibit increased receptor levels. It would thus be interesting to determine whether HIV-infected individuals in whom LC CD4 positivity increases correspond to those patients who develop KS.

This modification of LC phenotype may reflect latent HIV infection in these cells. It can explain that the HIV is very frequently present within the skin during the course of HIV infection (15). LC might behave as a local reservoir for the expression of HIV genoma-derived products that in turn stimulate and sustain growth of the proliferating cells in KS. Possibly, the

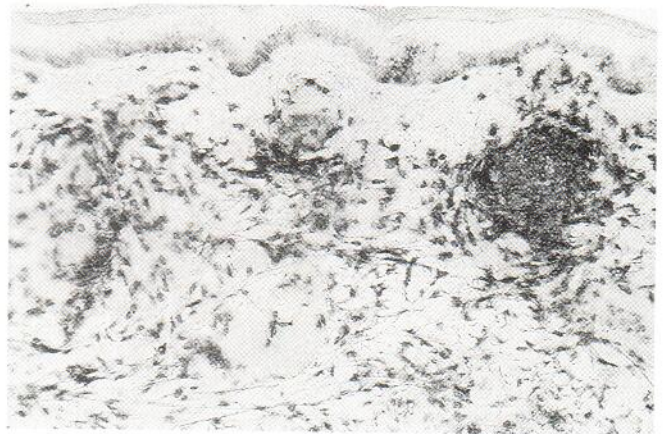


Fig. 6. Kaposi's sarcoma lesions. Abundant CD8 positive rounded cells are seen within the tumour isolatedly and in clusters. Original magnification 250x.

LC present within the tumour, and inversion of the predominant lymphocytic type in the dermis, could also contribute to the production and maintenance of angioproliferative lesions (16) by creating an imbalance in the local cytokine network.

The lymphocytes that infiltrate perilesional skin, the lesion itself, and the epidermis in small numbers are of the cytotoxic/suppressor phenotype (CD8+). In normal skin and in many pathologies, the lymphocyte subtype distribution pattern involves a predominance of CD4 positivity (17). In skin affected by KS these cells are practically non-existent – almost all being CD8+ lymphocytes. This is again a clear indication of the situation of the lymphocyte populations in peripheral blood (18). The suprapilesional epidermis also exhibits cytotoxic/suppressor lymphocyte infiltration, and these cells may be responsible for the damage to the LC or else be recruited by the secretion of cytokines secreted by the epithelium. This is corroborated by the appearance of HLA-DR antigen expression in clusters of basal keratinocytes. Aberrant HLA-DR expression occurs in a number of inflammatory conditions (19) in which gamma-interferon is secreted (20).

The proliferating cells in KS are HLA-DR positive, as expected in endothelial cells which are positive for this marker (21). A small proportion of fusiform cells are also CD4 positive. These cells are diffusely distributed and are not encountered where CD1a positive cells are found within the tumour. Such cells might correspond to dermal dendritic cells that positized this marker in KS.

In summary, in KS-affected skin, LC modify their phenotype and increase CD4 expression while diminishing that of HLA-DR antigen. Moreover, local cytokine-releasing phenomena result in HLA-DR expression by keratinocytes. The tumour lymphocyte infiltrate is predominantly of the cytotoxic/suppressor phenotype, and among the KS proliferating cells a number of dendritic or fusiform cells are seen to express CD4 receptor.

REFERENCES

- Shimada S, Katz SI. The skin as an immunologic organ. *Arch Pathol Lab Med* 1988; 112: 231–234.
- Stingl G, Rappersberger K, Tschachler E, Gartner S, Groh V, Man DL, et al. Langerhans cells in HIV-1 infection. *J Am Acad Dermatol* 1990; 22: 1210–1217.
- Febrer-Bosch MI, Navarro-Ibañez V, Camps-Herrero C, Tuset-Ruiz C, Valcuende Cavero F. Sarcoma de Kaposi asociado a infección por el virus de la inmunodeficiencia humana: revisión clínica, histológica, inmunohistoquímica, serológica y evolutiva. *Med Clin (Barc)* 1991; 96: 601–606.
- Castells-Rodellas A, Castell JV, Ramirez-Boscá A, Nicolas JF, Valcuende-Cavero F, Thivolet J. Interleukin-6 in normal skin and psoriasis. *Acta Derm Venereol (Stockh)* 1992; 72: 165–168.
- Friedman-Kien AE, Saltzman BR. Clinical manifestations of classical, endemic African, and epidemic AIDS-associated Kaposi's sarcoma. *J Am Acad Dermatol* 1990; 22: 1237–1250.
- Vogel J, Hinrichs SH, Reynolds RK, Luciw PA, Jay G. The HIV tat gene induces dermal lesions resembling Kaposi's sarcoma in transgenic mice. *Nature* 1988; 335: 606–611.
- Dusserre N, Dezutter-Dambuyant C, Mallet F, Delorne P, Philit F, Ebersold A, et al. In vitro HIV-1 entry and replication in Langerhans cells may clarify the HIV-1 genome detection by PCR in epidermis of seropositive patients. *J Invest Dermatol* 1992; 99: 99s–102s.
- Kalter DC, Greenhouse JJ, Orenstein JM. Epidermal Langerhans cells are not principal reservoirs of virus in HIV disease. *J Immunol* 1991; 146: 3396–3404.
- Belsito DV, Sanchez MR, Baer RL, Valentine F, Thorbecke GJ. Reduced Langerhans cell Ia antigen and ATPase activity in patients with the acquired immunodeficiency syndrome. *N Engl J Med* 1984; 310: 1279–1282.
- Dreno B, Milpied B, Bignon J, Stalder JF, Litoux P. Prognostic value of Langerhans cells in the epidermis of HIV patients. *Br J Dermatol* 1988; 118: 481–486.
- Aiba S, Katz SI. The ability of cultured Langerhans cells to process and present protein antigens is MHC-dependent. *J Immunol* 1991; 146: 2479–2487.
- De Panfilis G, Manara GC, Ferrari C, Torresani C. Simultaneous colloidal gold immunoelectronmicroscopy labelling of CD1a, HLA-DR and CD4 surface antigens of human epidermal Langerhans cells. *J Invest Dermatol* 1988; 91: 547–552.
- Ramirez-Boscá A, Martinez-Ojeda L, Valcuende-Cavero F, Castells-Rodellas A. A study of local immunity in psoriasis. *Br J Dermatol* 1988; 119: 587–595.
- Gielen V, Schmitt D, Dezutter-Dambuyant C, Thivolet J. AIDS and Langerhans cells: CD4 antigenic site density modification evidenced by single-cell immunogold labelling. *Reg Immunol* 1989; 2: 7–13.
- Kanitakis J, Escaich S, Trepo C, Thivolet J. Detection of human immunodeficiency virus-DNA and RNA in the skin of HIV-infected patients using the polymerase chain reaction. *J Invest Dermatol* 1991; 97: 91–96.
- Corbeil J, Evans LA, Vasak E, Cooper DA, Penny R. Culture and properties of cells derived from Kaposi sarcoma. *J Immunol* 1991; 146: 2972–2976.
- Markey AC, Allen MH, Pitzalis C, MacDonald DM. T-cell inducer populations in cutaneous inflammation: a predominance of T helper-inducer lymphocytes (THi) in the infiltrate of inflammatory dermatoses. *Br J Dermatol* 1990; 122: 325–332.
- Becker J, Ulrich P, Kunze R, Cederblom H, Langford A, Reichart P. Immunohistochemical detection of HIV structural proteins and distribution of T-lymphocytes and Langerhans cells in the oral mucosa of HIV infected patients. *Vichows Arch (A)* 1988; 412: 413–419.
- Auböck J, Romani N, Grubauer G, Fritsch P. HLA-DR expression on keratinocytes is a common feature of diseased skin. *Br J Dermatol* 1986; 114: 465–472.
- Smith B, Berman B. Characterization of a glucocorticosteroid-induced inhibitor of interferon-gamma induction of HLA-DR expression. *J Invest Dermatol* 1992; 99: 35–39.
- Rutgers J L, Wiczorek R, Boneti F, et al. The expression of endothelial cell surface antigens by AIDS-associated Kaposi's sarcoma. *Am J Pathol* 1986; 122: 493–499.