

## Adverse Immune Reactions to Gold in Rheumatoid Arthritis: Lack of Skin Reactivity

RUTH GOLDBERGMANN<sup>1</sup>, HANS-CHRISTIAN SCHUPPE<sup>1</sup>, ERNST GLEICHMANN<sup>2</sup>, PETER KIND<sup>1</sup>, HANS MERK<sup>3</sup>, ROLF RAU<sup>4</sup> and GÜNTER GOERZ<sup>1</sup>

<sup>1</sup>Department of Dermatology, Heinrich-Heine-University, W-Duesseldorf, <sup>2</sup>Medical Institute of Environmental Medicine, Heinrich-Heine-University, W-Duesseldorf, <sup>3</sup>Department of Dermatology, University of Cologne, W-Cologne and <sup>4</sup>Evangelisches Fachkrankenhaus, W-Duesseldorf, Germany

**Adverse immune reactions develop in up to 30% of patients treated with gold compounds. However, sensitization to gold(I) drugs is rarely demonstrated by in vivo or in vitro testing. Recent data from a mouse model provides evidence that gold(I) is oxidized to gold(III) before T cells are sensitized. To study the diagnostic value of skin tests, patch testing with various gold compounds – including gold(I) and gold(III) – was performed in 50 patients with rheumatoid arthritis treated with gold(I) drugs. Positive patch test reactions to either gold(I) or gold(III) compounds were not detected. In contrast, the lymphocyte transformation test (LTT) revealed a gold(III)-induced response in one of the 7 patients being tested. We conclude that patch testing fails to indicate T cell sensitization to gold(I) drugs in rheumatoid arthritis patients. The in vitro response to gold(III) obtained by LTT supports the hypothesis that biooxidation of gold(I) compounds may play a crucial role for sensitization. Key words: Gold sensitization; Patch test; Lymphocyte proliferation.**

(Accepted February 8, 1993.)

Acta Derm Venereol (Stockh) 1993; 73: 220–222.

R. Goldermann, Department of Dermatology, Heinrich-Heine-University, Moorenstr. 5, W-4000 Duesseldorf, Germany.

Since 1929, gold compounds such as gold sodium thiomalate (GST), containing monovalent gold, gold(I), are widely used in the treatment of rheumatoid arthritis (RA) (1). Frequently observed side effects are dermatitis and stomatitis. Glomerulonephritis, neutropenia, formation of antinuclear auto-antibodies and hypergammaglobulinaemia with increased serum IgE levels are less common (2). The clinical spectrum of immunological side effects suggests a T cell-mediated pathomechanism. This hypothesis is further supported by the association between gold-induced nephropathy and MHC class II genes (3).

In a recently established mouse model comparable adverse immune reactions – such as hyper-IgE production and formation of antinuclear auto-antibodies – developed after repeated intramuscular injections of GST (4). Splenic T cells from mice treated with GST showed strong anamnestic responses to gold (III) but not to gold(I). Therefore, it has been suggested that biooxidation of gold(I) to gold(III) in macrophages or granulocytes precedes T cell sensitization (5, 6).

In contrast to the high frequency of adverse immune reactions to gold(I) drugs in RA patients, sensitization to gold(I) was rarely detected in vivo or in vitro.

To elucidate the diagnostic value of a single skin test procedure for detecting gold-specific T cell reactivity, patch testing was performed in 50 RA patients during or after gold therapy, 33/50 with a history of adverse immune reactions. Further-

more, peripheral blood lymphocytes of 7 selected patients were tested in vitro by means of the lymphocyte transformation test (LTT).

### PATIENTS AND METHODS

#### *Patients and controls*

Fifty patients suffering from RA for 2–10 years treated with different gold compounds were studied. Out of these, 35 patients received GST, and the remaining 15 patients aurothiopolypeptide, aurothioglucose or auranofin. They had been treated with gold compounds for 1–30 months, receiving cumulative doses of 80–4,060 mg gold salt. 33 of these patients had developed gold induced adverse reactions. Side effects such as dermatitis, stomatitis and proteinuria caused cessation of therapy after approximately 7 months of treatment. At that time the average dose of GST had been 1,180 mg (80–4,060 mg). Additionally, 17 patients without clinically overt side effects were tested by means of patch tests.

Seven patients were selected for LTT. They had received GST for 10 days to 7 months with cumulative doses of 80 to 960 mg. All 7 had suffered from exanthema, one additionally from transient proteinuria.

#### *Skin tests and determination of total IgE*

Patch-testing was performed using Finn chambers (50 µl size) on the back. The test sites were examined after 24, 48, 72 and 168 h. Positive test reactions were defined as infiltration and erythema (+), papulovesicles (++) and bullous reaction (+++). The patch test protocol included both gold(I) and gold(III) compounds: gold sodium thiomalate (2.0% aeq., 0.5% petrol.), gold sodium thiosulphate (0.5% petrol.) and gold trichloride (1.0% petrol.) (Hermal, W-Reinbek/Hamburg, Germany). Fifty age- and sex-matched healthy volunteers served as controls. Total serum IgE concentrations were determined using a commercially available testkit (Synelisa, Pharmacia, W-Freiburg, Germany).

#### *Isolation of cells and cell cultures*

To demonstrate gold-specific T cell sensitization in vitro LTT was performed in 7 patients who had developed dermatitis during treatment with GST. Proteinuria was additionally observed in one patient.

For LTT, mononuclear cells were isolated from 50 ml heparinized peripheral blood using Ficoll gradients (Ficoll-Paque, Pharmacia, W-Freiburg, Germany). Cells were resuspended in antibiotic-free culture medium TC 199 (GIBCO/BRL, W-Eggenstein, Germany) supplemented with 15% heat-inactivated autologous serum.  $1 \times 10^6$  mononuclear cells/1 ml were cultured for 5 days, incubated with either GST (0.3 to 5.0 µg/ml; Byk Gulden Lomberg, W-Singen, Germany) or gold trichloride (1.5 to 100 µg/ml; Fluka, Switzerland) and pulsed with (<sup>3</sup>H)-thymidine (81.9 Ci/mmol; NEN, Du Pont de Nemours, W-Bad Homburg, Germany) 24 h before harvesting. For control purposes pokeweed mitogen-induced proliferation of mononuclear cells was assessed (100 µg/ml; GIBCO/BRL, W-Eggenstein, Germany). Incorporated radioactivity was counted in a liquid scintillation counter (LKB Wallac 1217 Rackbeta). Results from duplicate cultures are



Table I. Skin reactivity of 50 RA patients and 50 healthy controls: patch test results

GST = gold sodium thiomalate; GSS = gold sodium thiosulphate; aequ. = aqueous; petrol. = petrolatum.

Gold compound	Conc./Vehicle		Patients	Controls
GST - gold(I)	2.0% Aequ.		0	0
GST - gold(I)	0.5% Petrol.		0	1 <sup>‡</sup>
GSS - gold(I)	0.5% Petrol.		0	2*
Gold trichloride	1.0% Petrol.		0	0

<sup>‡</sup> 24 h ++, 48 h ++, 72 h ++

\* Control 1: 24 h +, 48 h ++, 72 h +++

Control 2: 24 h +, 48 h ++, 72 h ++

expressed as stimulation index (SI) comparing counts per minute (cpm) values of gold-treated wells with controls.

## RESULTS

Patch-testing revealed neither irritative nor allergic skin reactions to gold(I) or to gold(III) preparations in any of the 50 patients suffering from RA. In contrast, 3 out of 50 controls showed a typical delayed type hypersensitivity to gold(I) despite clinical evidence for gold-induced contact dermatitis. Once more there were no positive reactions to gold(III) or any irritative response (Table I).

Three of the 7 patients with exanthema selected for LTT showed blood eosinophilia up to 8%. There was no concomitant elevation of serum IgE concentrations, neither in these 7 nor in the vast majority (92%) of the other patients studied.

In response to gold(I), peripheral mononuclear cells of patients and controls did not exhibit any reactivity (Fig. 1). However, in one patient after addition of 1.5–12.5 µg/ml gold trichloride a dose-dependent and specific lymphocyte proliferation was induced (Fig. 2). This patient had suffered from gold dermatitis after 10 days of treatment with a cumulative dose of 80 mg GST. Concomitantly blood eosinophilia of 6% was detectable. Serum IgE concentration was within normal range. The other patients and all controls showed negative LTT results with gold(III).

## DISCUSSION

The graft-versus-host-like spectrum of gold-induced adverse reactions, such as mucocutaneous eruptions and nephropathy, and their association with the MHC suggest that T cells play a central role in the pathogenesis in humans as well as in mice (3). In RA patients, however, T cell sensitization to gold(I) drugs was rarely demonstrated *in vitro* using the LTT (7–12). *In vivo* diagnostic procedures, e.g. epicutaneous patch-testing with gold(I) salts, were performed in single patients and remained without positive reactions (9, 11–12). Until now the recently developed concept that biooxidation of gold(I) to gold(III) precedes specific T cell activation in mice has not been considered in humans. In the present study *in vivo* and *in vitro* diagnostic procedures were performed including a variety of gold(I) and gold(III) compounds as test substances.

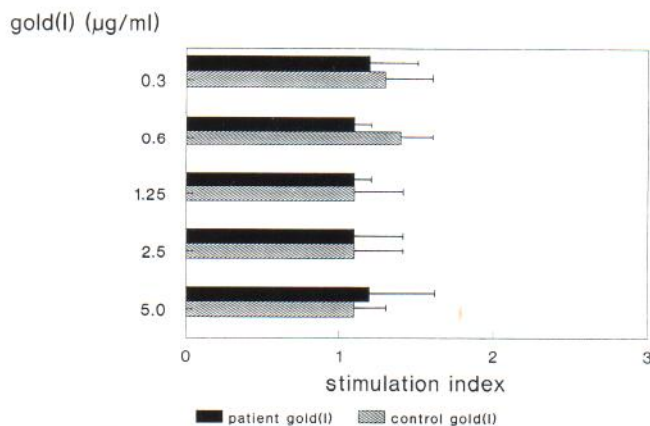


Fig. 1. Results of LTT obtained with gold(I) (gold sodium thiomalate) in 7 patients with RA ■ and 7 healthy controls ▨. Cells were incubated with 0.3 to 5.0 µg/ml gold compound. Horizontal bars indicate 1 SD. Stimulation indices of duplicate cultures of patients are comparable to those of controls. A specific response to gold(I) is not detectable.

Among other mechanisms delayed-type hypersensitivity is discussed concerning the pathogenesis of skin eruptions under gold therapy. Therefore, patch-testing was chosen as a noninvasive, easily performed method to detect specific T cell sensitization *in vivo*. However, difficulties known from gold-induced contact allergy had to be considered. In a number of patients who developed contact dermatitis upon exposure to gold salts, patch-testing with gold-containing compounds revealed false negative results (13, 14). Furthermore, positive patch test reactions in gold contact allergy showed clinical abnormalities, i.e. persistent dermatitis-like plaques or granulomatous contact dermatitis (15, 16). Especially for gold trichloride prolonged dermal reactions are described (17, 18).

The majority of RA patients included in this study had suffered from typical side effects such as dermatitis, stomatitis or proteinuria. Irrespective of any adverse immune reaction to gold, the epicutaneous testing failed to unravel T cell sensitization. Our results confirm the casuistic reports concerning lack

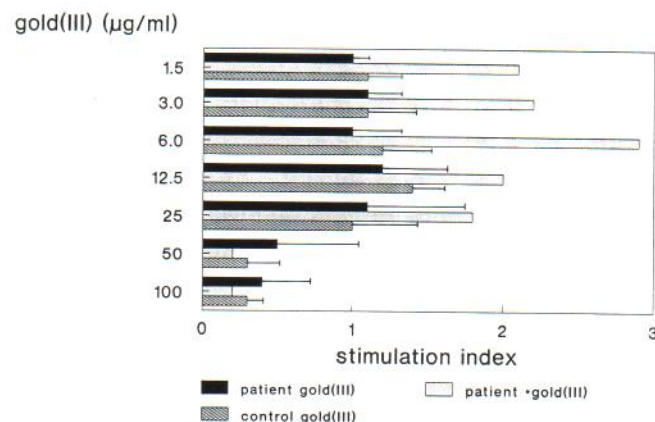


Fig. 2. Results of LTT obtained with gold(III) (gold trichloride) in 7 patients with RA ■ and 7 healthy controls ▨. Cells were incubated with 1.5 to 100 µg/ml gold compound. Horizontal bars indicate 1 SD. Stimulation indices of duplicate cultures of 6 patients with RA are comparable to those of controls. In one patient after incubation with 1.5 to 12.5 µg/ml gold trichloride a dose-dependent specific T cell proliferation is detectable □.



of skin hypersensitivity to gold(I) drugs (8–10). Furthermore, the patch test cannot detect gold(III) specific T cells possibly generated during antirheumatic therapy with gold(I) salts. These negative results might be due to the route of administration, i.e. epicutaneous application of the test compounds could be inappropriate to detect sensitization induced by systemic treatment with gold salts.

In vitro tests using peripheral blood lymphocytes might represent a more reliable approach to detect gold-specific T cell sensitization. In addition, LTT reduces possible hazards from in vivo administration of the test compounds. In some patients suffering from gold-induced contact dermatitis, LTT with gold salts revealed specific dose-dependent reactions to gold(I) (19, 20). Concerning the immunotoxicity of gold(I) drugs, lymphocyte proliferation results varied within a wide range of stimulation indices. Until now, LTT performed in RA patients included only gold(I) compounds and remained inconclusive. Possible immune reactions to gold(III) had not been considered (7–12).

Our results indicate that neither gold(I) nor gold(III) compounds can elicit any mitogenic effect in cultures of controls. In RA patients, gold(I) compounds did not induce any lymphocyte proliferation. However, in one out of 7 patients a gold(III)-specific sensitization was detectable. This finding was recently confirmed by a similar reactivity of peripheral blood lymphocytes to gold(III) in a number of RA patients with comparable gold-induced adverse immune reactions (21).

In conclusion, RA patients suffering from gold-induced side effects lack skin hypersensitivity. Patch-testing fails to indicate whether gold-specific sensitization has taken place or not. In contrast, the lymphocyte proliferation test seems to be a better approach for detecting T cell sensitization during gold therapy. However, the low number of positive reactions in this study indicates that further evaluation and standardization of lymphocyte proliferation assays are necessary. Additional assays measuring the activation of specific lymphocyte functions, such as the pattern of secreted lymphokines, might improve the diagnostic approach towards gold-induced adverse immune reactions. Any test procedure should include both gold (I) and gold(III) compounds.

#### ACKNOWLEDGEMENTS

This study was generously supported by Tosse GmbH, W-Hamburg, Germany, and in part by a grant from the Deutsche Forschungsgemeinschaft Me 939/1-1. The authors thank Mrs. Ute Werth for excellent technical help.

#### REFERENCES

1. Kean WF, Forestier F, Kassam Y, Buchanan WW, Rooney PJ. The history of gold therapy in rheumatoid disease. *Semin Arthritis Rheum* 1985; 14: 180–186.
2. Sambrook PN, Browne LD, Champion D, Day RO, Vallance JB, Warwick N. Terminations of treatment with gold sodium thiomalate in rheumatoid arthritis. *J Rheumatol* 1982; 9: 932–934.
3. Scherak O, Smolen JS, Mayr WR, Mayhofer F, Kolarz G, Thumb NJ. HLA-Antigens and toxicity to gold and penicillamine in rheumatoid arthritis. *J Rheumatol* 1984; 11: 610–618.
4. Schuhmann D, Kubicka-Muranyi M, Mirschewa J, Kind P, Gleichmann E. Adverse immune reactions to gold. Chronic treatment with an Au(I) drug sensitizes mouse spleen cells not to Au(I), but to Au(III) and induces autoantibody formation. *J Immunol* 1990; 145: 2132–2139.
5. Möller-Madsen B, Mørgensen SC, Donscher G. Ultrastructural localization of gold in macrophages and mast cells exposed to aurothioglucose. *Exp Mol Path* 1984; 40: 148–154.
6. Persellin RH, Ziff M. The effect of gold salt on lysosomal enzymes of the peritoneal macrophage. *Arthritis Rheum* 1966; 9: 57–65.
7. Denman EJ, Denman AM. The lymphocyte transformation test and gold hypersensitivity. *Ann Rheum Dis* 1968; 27: 582–588.
8. Davis P, Ezeoke A, Munro J, Hobbs JR, Hughes GRV. Immunological studies on the mechanism of gold hypersensitivity reactions. *Br Med J* 1973; 3: 676–678.
9. Schapira D, Nahir M, Scharf Y, Pollack S. Cholestatic jaundice induced by gold salts treatment. *J Rheumatol* 1984; 11: 843–845.
10. Schubert H, Rytter M, Birke G. Lymphozytentransformationstest in der Diagnostik der Goldallergie. *Allerg Immunol (Leipzig)* 1973; 17: 49–55.
11. Walzer RA, Feinstein R, Shapiro L, Einbinder J. Severe hypersensitivity reaction to gold. *Arch Dermatol* 1972; 106: 231–234.
12. Stone RL, Claflin A, Penneys NS. Erythema nodosum following gold sodium thiomalate therapy. *Arch Dermatol* 1973; 107: 602–604.
13. Goh CL. Occupational dermatitis from gold plating. *Contact Dermatitis* 1988; 19: 122–123.
14. Cronin E. Contact dermatitis. Edinburgh: Churchill Livingstone, 1980: 328–336.
15. Iwatsuki K, Tagami H, Moriguchi T, Yamada M. Lymphadenoid structure induced by gold hypersensitivity. *Arch Dermatol* 1982; 118: 608–611.
16. Aoshima T, Oguchi M. Intracytoplasmic crystalline inclusions in dermal infiltrating cells of granulomatous contact dermatitis due to gold earrings. *Acta Derm Venereol (Stockh)* 1988; 68: 261–264.
17. Bowyer A. Epidermal reactions and prolonged dermal reactions to patch testing with gold salts. *Acta Derm Venereol (Stockh)* 1967; 47: 9–14.
18. Shelley WB, Epstein E. Contact-sensitivity to gold as a chronic papular eruption. *Arch Dermatol* 1963; 87: 388–391.
19. Silvennoinen-Kassinen S, Ninimäki A. Gold sensitivity blast transformation. *Contact Dermatitis* 1984; 11: 156–158.
20. Schöpf E, Wex o, Schulz KH. Allergische Kontaktstomatitis mit spezifischer Lymphozytenstimulation durch Gold. *Hautarzt* 1970; 9: 422–424.
21. Verwilghen J, Romagnoli P, Lanchbury J, Kingsley G, Panayi GS. Gold toxicity in rheumatoid arthritis: gold(III) but not gold(I) induces lymphocyte proliferation in patients with gold allergy. *Clin Rheumatol* 1990; 9: 561–562.