

## Keratinocyte and Epidermal Leukocyte Expression of CD36 (OKM5) in Benign and Malignant Skin Diseases

STEEN LISBY,<sup>1</sup> ELISABETH RALFKIÆR,<sup>2</sup> ERIK R. HANSEN<sup>1</sup> and GUNHILD L. VEJLSGAARD<sup>1</sup>

<sup>1</sup>Laboratory of Immunology, Department of Dermatology, Bispebjerg Hospital and <sup>2</sup>Department of Pathology, Rigshospitalet, Copenhagen, Denmark

CD36 recognizes a 88 Kd glycoprotein, found on different cell populations involved in immunoregulation and are induced on keratinocytes by *in vitro* treatment with gamma-interferon. Therefore, we obtained skin biopsies from 48 patients with various dermatological diseases and from 5 healthy volunteers and stained these with monoclonal antibodies OKM5 (CD36), anti-HLA-DR and OKT6 (CD1a) using a three stage immunoperoxidase method. In normal skin, CD36 expression was not observed. In contrast, keratinocytes in diseased skin were CD36<sup>+</sup>. In most cases, the staining was restricted to the stratum granulosum and the stratum spinosum, but in psoriasis, squamous cell carcinoma and lymphomatoid papulosis, more extensive staining of keratinocytes was seen. In addition, CD36<sup>+</sup> epidermal leukocytes were found in allergic patch-test infiltrates and in mycosis fungoides. The findings of CD36 expression by epidermal cells within a broad spectrum of dermatological diseases indicate a role for these cells in the regulation of immune reactions in the skin. **Key words:** CD36<sup>+</sup> leukocytes; CD36<sup>+</sup> keratinocytes; Skin disorders; Immunohistology.

(Accepted August 3, 1988.)

Acta Derm Venereol (Stockh) 1990; 70: 18–22.

S. Lisby, Laboratory of Immunology, Department of Dermatology, Bispebjerg hospital, Bispebjerg Bakke 23, DK-2400 Copenhagen, Denmark.

Many skin disorders are characterized by infiltrates of T lymphocytes in the involved skin areas. These T lymphocytes exhibit an activated state and represent different mature T lymphocyte subsets (1, 2). Activated T cells release a variety of lymphokines, including gamma-interferon (IFN), Interleukin (IL)-2, IL-3, IL-4, IL-6 and tumour necrosis factor- $\beta$ . T cell lymphokines, in particular  $\gamma$ -IFN, have been demonstrated to up-regulate different receptors (e.g. HLA-Dr, CD36) on the keratinocyte cell surface membrane *in vitro* (3, 4).

CD36 (OKM5) identify an 88 kD membrane protein that functions as the thrombospondin receptor, a molecule that is involved in cell adhesion (5, 6) and is

expressed by different cell populations, e.g. blood monocytes, platelets, and endothelial cells (7, 8). In skin, previous studies have demonstrated the presence of antigen presenting CD36<sup>+</sup> leukocytes within the epidermis following *in vivo* UV-irradiation (9, 10). More recently, CD36<sup>+</sup> leukocytes and CD36<sup>+</sup> keratinocytes have been demonstrated within epidermal cell suspensions from involved skin from mycosis fungoides and these CD36<sup>+</sup> cells are involved in the immune function of the skin (11, 12, 13). In contrast, no keratinocyte CD36 expression is seen in normal skin, however, controversy exists on this point (9, 14, 15, 16).

In this study, skin punch biopsies from various benign and malignant skin diseases have been examined for reaction with OKM5 (CD36); and these data have been compared with the labeling seen with OKT6 (CD1a) and anti-HLA-DR.

### MATERIALS AND METHODS

#### *Biopsy specimens*

Skin punch biopsies were obtained from healthy adult volunteers ( $n=5$ ) and from patients with different dermatological diseases ( $n=48$ ). The diagnosis are listed in Table I. The fresh skin specimens were frozen and stored in liquid nitrogen. Six  $\mu$ m cryostat sections were air-dried overnight at room temperature, fixed in acetone for 10 min and stored at  $-80^{\circ}\text{C}$  until staining.

#### *Antibodies and histochemical reagents*

The monoclonal antibodies used in this study included OKT6 (CD1a), OKM5 (CD36) (Ortho Immuno-diagnostics) and anti-HLA-DR (Becton-Dickinson). Peroxidase-conjugated rabbit anti-mouse-Immunoglobulin (Ig) and peroxidase-conjugated swine anti-rabbit-Ig were purchased from Dakopatts. Diaminobenzidine-tetrahydrochloride were obtained from Sigma (St. Louis, Mo., USA).

#### *Immunoenzymatic staining procedures*

Sections were incubated with monoclonal antibody and stained with the use of a three-stage immunoperoxidase method (1). Lymph nodes were stained as positive controls. Negative controls were performed by omitting the primary antibody and by substituting this reagent with antibody of irrelevant specificity but identical isotype.

Table I. CD36 staining in normal and diseased skin

+ = staining of the stratum granulosum and the stratum spinosum. ++ = strong staining of the stratum granulosum and the stratum spinosum or staining of virtually all layers of the epidermis. - = no OKM5 staining on the keratinocytes. CTCL = cutaneous T cell lymphoma

Diagnosis	No. of cases	CD36 <sup>+</sup> keratinocytes		
		+	++	-
Normal skin	5	0	0	5
Contact dermatitis:				
4 h patch tests	4	0	0	4
48 h patch tests	2	1	1	0
72 h patch tests	1	0	1	0
Psoriasis	6	1	6	0
Lichen planus	2	0	2	0
Actinic reticuloid	1	1	0	0
Lymphomatoid papulosis	2	0	2	0
Mycosis fungoides	16	15	1	0
Sézary syndrome	4	2	0	2
CTCL, pleomorphic	1	0	0	1
CTCL, anaplastic	1	0	1	0
Histiocytosis X	1	1	0	0
Actinic keratosis	3	1	2	0
Basal cell carcinoma	3	1	2	0
Squamous cell carcinoma	1	0	1	0

## RESULTS

Results from the staining of normal skin and various skin disorders are listed in Table I and illustrated in Figs. 1–5. In normal skin no CD36 staining was observed (Fig. 1). In contrast, keratinocytes in benign, inflammatory conditions were CD36 positive (Table I). In biopsies from lichen planus and allergic patch tests, obtained at 48 h and 72 h, the staining of keratinocytes was confined to the stratum granulosum and to a lesser extent the stratum spinosum (Fig. 2). In contrast, biopsies from allergic patch-tests obtained 4 h after application of the allergen did not contain CD36<sup>+</sup> keratinocytes (Table I).

In biopsies from psoriasis, more abundant staining of keratinocytes was observed (Figs. 3–4). Staining of the stratum granulosum and stratum spinosum were also seen in biopsies from malignant cutaneous lymphomas, such as mycosis fungoides (Fig. 5) and Sézary syndrome. In lymphomatoid papulosis, we found extensive CD36 staining by keratinocytes (Table I). Similarly we found that in epidermal tumours such as basal cell carcinoma and squamous cell carcinoma, CD36 was expressed by virtually all the neoplastic cells in 3 ut of 4 cases.

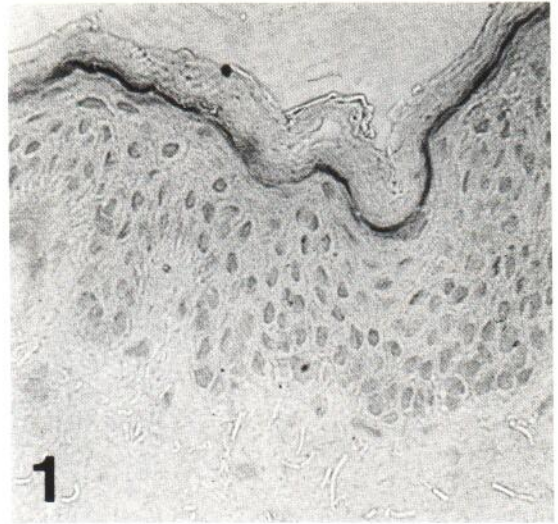


Fig. 1. Normal skin immunostained for OKM5 (CD36) ( $\times 400$ ).

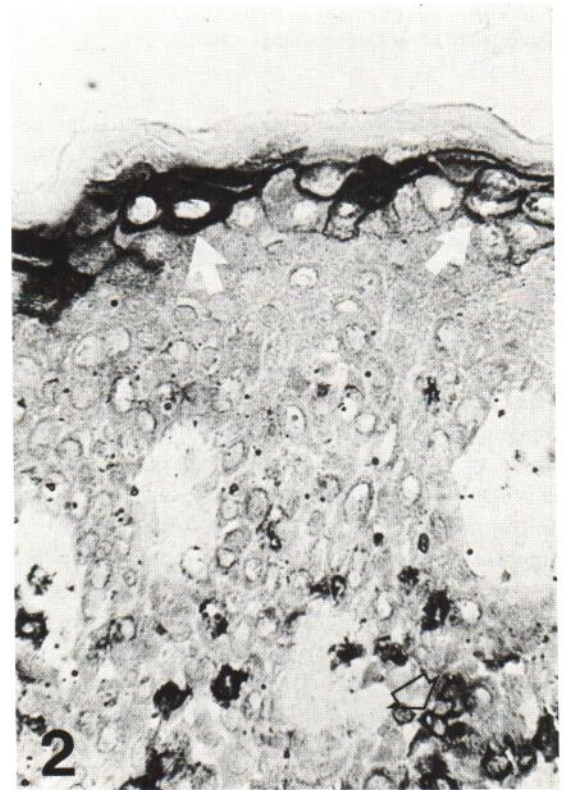


Fig. 2. 96 h allergic patch test immunostained for OKM5 (CD36). Closed arrow: CD36<sup>+</sup> keratinocytes. Open arrow: Dendritic cell stained positively for OKM5 (CD36) ( $\times 400$ ).

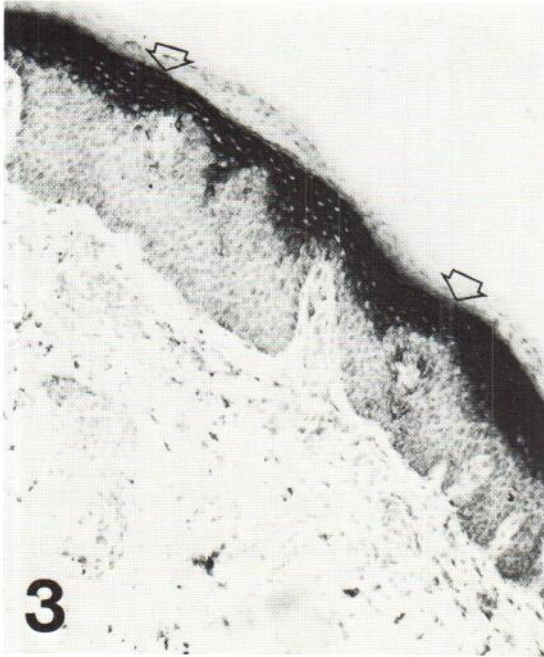

Fig. 3. Psoriasis immunostained for OKM5 (CD36). Arrows indicate OKM5 (CD36) staining ( $\times 100$ ).

Skin biopsies from allergic patch-test reactions, obtained at 4 hr, 48 hr and 72 hr also contained CD36<sup>+</sup> dendritic cells. These cells were present in the basal/suprabasal layers of the epidermis (Fig. 2). Similar, CD36<sup>+</sup> cells were also seen in mycosis fungoides (Fig. 5).

Finally, we found strong CD36 staining on both sebaceous glands and endothelial cells.

In both normal and diseased skin, CD1a expression was confined to dendritic cell populations (Langerhans' cells and indeterminate cells) and was never found on keratinocytes. In normal skin, HLA-DR expression was confined to dendritic cell populations. In contrast, in diseased skin, HLA-DR positive keratinocytes were found in 19 of 48 biopsies, including biopsies from 72 h allergic patch tests, lichen planus, mycosis fungoides, Sézary syndrome and basal cell carcinoma. The staining pattern was different from that seen with CD36 as HLA-DR stained mainly keratinocytes in the basal/suprabasal layers of the epidermis (data not shown).

#### DISCUSSION

In this study, we do not find *in vivo* keratinocyte CD36 expression in clinically normal skin. This is in

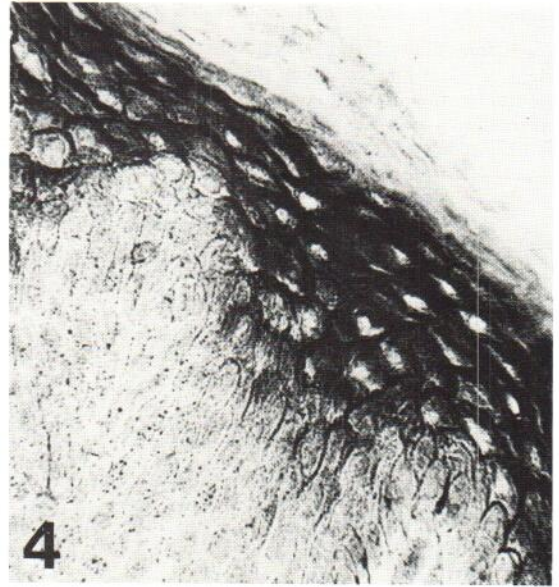

Fig. 4. Psoriasis, immunostained for OKM5 (CD36) ( $\times 400$ ).

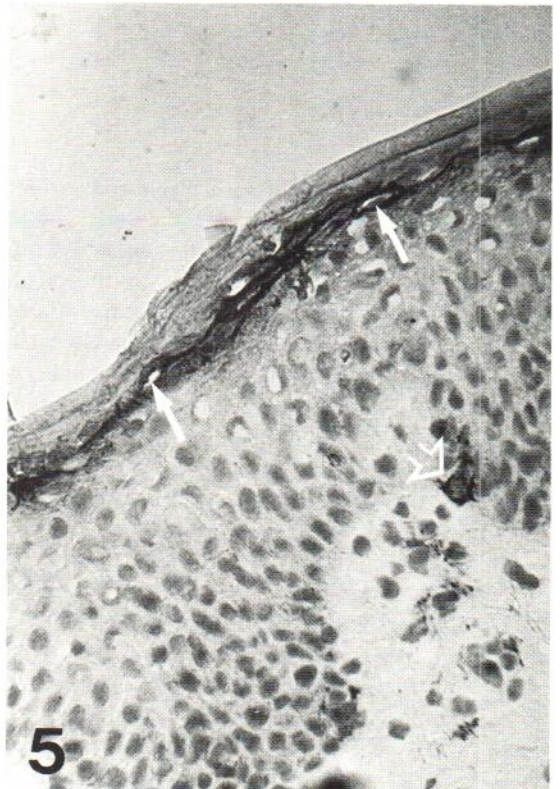

Fig. 5. Mycosis fungoides. Closed arrow: CD36<sup>+</sup> keratinocytes. Open arrow: Dendritic cell stained positively for OKM5 (CD36) ( $\times 400$ ).

contrast to findings by Soyer et al. (14), but in agreement to findings by Simon and Hunyadi (15, 16) and Cooper et al. (9). In contrast, we find that keratinocytes in diseased skin express CD36. These data confirm and extend previous observations (12, 14–17), and indicate that CD36 expression by keratinocytes is a common phenomenon in many skin disorders and is not merely restricted to a few specific diseases.

In most instances, the CD36 staining is restricted to the stratum granulosum and the stratum spinosum, but in some diseases (like psoriasis and lymphomatoid papulosis) virtually all layers are positive. The CD36 expression does not exhibit the same staining pattern as HLA-DR and it does not correlate with expression of other cell adhesion molecules, such as intercellular adhesion molecule-1 (CD54), which normally is restricted to the basal/suprabasal layers of the epidermis (18).

Interestingly, we find that certain epidermal leukocytes in allergic patch-tests and in mycosis fungoides express CD36. It has been established that the type of T lymphocyte response, (delayed type hypersensitivity or suppression/tolerance), resulting from an antigen/mitogen stimulation is dependent upon the type of antigen presenting cell (19, 20). Furthermore, it has recently been demonstrated that CD36<sup>+</sup> leukocytes found following UV-irradiation contained the capacity to stimulate both allogeneic T lymphocytes and autologous CD4<sup>+</sup>2H4<sup>+</sup> T suppressor-inducer and CD8<sup>+</sup> T suppressor-cytotoxic lymphocytes (9, 21). Thus, the findings that certain epidermal leukocytes in allergic patch-tests and in mycosis fungoides express CD36 could possibly indicate an alternative immune-regulation, and if these leukocytes exhibit similar functional capacity as the UV-induced CD36<sup>+</sup>OKM1<sup>-</sup> epidermal leukocytes, they could provide down-regulating signals on the ongoing inflammatory reaction (21).

In conclusion, the presence of both CD36<sup>+</sup> keratinocytes and CD36<sup>+</sup> epidermal leukocytes in a variety of dermatological disorders, indicates an important role for CD36 in cutaneous immune reactions.

#### ACKNOWLEDGEMENT

This work was supported by a grant from Aage Bangs foundation, Copenhagen, Denmark.

#### REFERENCES

1. Ralfkiaer E, Wantzin GL, Mason DY, Hou-Jensen K, Stein H, Thomsen K. Phenotypic characterization of

lymphocyte subsets in mycosis fungoides. *Am J Clin Pathol* 1985; 84: 610–619.

2. Ralfkiaer E, Wantzin GL, Stein H, Thomsen K, Mason DY. T-cell growth factor receptor (Tac-antigen) expression in cutaneous lymphoid infiltrates. *J Am Acad Dermatol* 1986; 15: 628–637.
3. Hunyadi J, Simon M JR. Expression of OKM5 antigen on human keratinocytes in vitro upon stimulation with  $\gamma$ -interferon. *Acta Derm Venereol (Stockh)* 1986; 66: 527–530.
4. Basham TY, Nickoloff BJ, Merigan TC, Morhenn VB. Recombinant gamma Interferon induces HLA-DR expression on cultured human keratinocytes. *J Invest Dermatol* 1984; 83: 88–90.
5. Asch AS, Barnwell J, Silverstein RL, Nachman RL. Isolation of the Thrombospondin membrane receptor. *J Clin Invest* 1987; 79: 1054–1061.
6. Barnwell JW, Ockenhouse CF, Knowles DM. Monoclonal antibody OKM5 inhibits the in vitro binding of Plasmodium falciparum-infected erythrocytes to monocytes, endothelial, and C32 melanoma cells. *J Immunol* 1985; 135: 3494–3497.
7. Knowles DM, Tolidjian B, Marboe C, D'Agati V, Grimes M, Chess L. Monoclonal anti-human monocyte antibodies OKM1 and OKM5 possess distinctive tissue distributions including different reactivity with vascular endothelium. *J Immunol* 1984; 132: 2170–2173.
8. Talle MA, Rao PE, Westberg E, Allegar N, Makowski M, Mittler RS, Goldstein G. Patterns of antigenic expression on human monocytes as defined by monoclonal antibodies. *Cell Immunol* 1983; 78: 83–99.
9. Cooper KD, Neises GR, Katz SI. Antigen-presenting OKM5<sup>+</sup> melanophages appear in human epidermis after ultraviolet radiation. *J Invest Dermatol* 1986; 86: 363–370.
10. Cooper KD, Fox P, Neises G, Katz SI. Effects of ultraviolet radiation on human epidermal cell alloantigen presentation: Initial depression of Langerhans cell-dependent function is followed by the appearance of T6<sup>-</sup>DR<sup>+</sup> cells that enhance epidermal alloantigen presentation. *J Immunol* 1985; 134: 129–137.
11. Hansen ER, Baadsgaard O, Lisby S, Cooper KD, Thomsen K, Vejlsgaard GL. Both OKM5<sup>+</sup> and OKM5<sup>-</sup>CD1<sup>+</sup> cells, positively selected from mycosis fungoides epidermis, potently stimulate CD4<sup>+</sup> autologous T-lymphocytes. *J Invest Dermatol* 1989; 92: 440.
12. Lisby S, Baadsgaard O, Cooper KD, Thomsen K, Wantzin GL. Expression of OKM5 antigen on epidermal cells in mycosis fungoides plaque stage. *J Invest Dermatol* 1988; 90: 716–719.
13. Lisby S, Baadsgaard O, Cooper KD, Hansen ER, Mehregan D, Thomsen K, Vejlsgaard GL. Phenotype, ultrastructure and function of CD1<sup>+</sup>DR<sup>+</sup> epidermal cells that express CD36 (OKM5) in cutaneous T cell lymphoma. *Eur J Immunol*, Submitted.
14. Soyer HP, Smolle J, Kerl H. Distribution patterns of the OKM5 antigen in normal and diseased human epidermis. *J Cutan Pathol* 1989; 16: 60–65.
15. Simon M Jr, Hunyadi J. Expression of OKM5 antigen on human keratinocytes in positive intracutaneous tests for delayed-type hypersensitivity. *Dermatologica* 1987; 175: 121–125.

16. Simon M. Lesional keratinocytes express OKM5, Leu8 and Leu11b antigens in lichen planus. *Dermatologica* 1988; 177: 152–158.
17. Lisby S, Baadsgaard O, Avnstorp C, Clemmensen O, Cooper KD, Wantzin GL. Irritant skin reactions demonstrate in contrast to allergic reactions decreased number and function of epidermal T6<sup>+</sup>DR<sup>+</sup> Langerhans cells. *J Invest Dermatol* 1988; 91: 405.
18. Vejlsgaard GL, Ralfkiaer E, Avnstorp C, Czajkowski M, Marlin SD, Rothlein R. Kinetics and characterization of intercellular adhesion molecule-1 (ICAM-1) expression on keratinocytes in various inflammatory skin lesions and malignant cutaneous lymphomas. *J Am Acad Dermatol* 1989; 20: 782–790.
19. Shen HH, Talle MA, Goldstein G, Chess L. Functional subsets of human monocytes defined by monoclonal antibodies: A distinct subset of monocytes contains the cells capable of inducing the autologous mixed lymphocyte culture. *J Immunol* 1983; 130: 698–705.
20. Ramila G, Erb P. Accessory cell dependent selection of specific T cell functions. *Nature* 1983; 304: 442–445.
21. Baadsgaard O, Fox DA, Cooper KD. Human epidermal cells from ultraviolet light-exposed skin preferentially activate auto-reactive CD4<sup>+</sup>2H4<sup>+</sup> suppressor-inducer lymphocytes and CD8<sup>+</sup> suppressor/cytotoxic lymphocytes. *J Immunol* 1988; 140: 1738–1744.