

Dermabrasion in Darier's Disease

Hugh Zachariae

*Department of Dermatology, Marselisborg Hospital,
University of Aarhus, Aarhus, Denmark*

Received July 11, 1978

Abstract. Dermabrasion was carried out in 5 patients with severe Darier's disease. All patients improved significantly within the treated areas. In general, over 75% of the dermabraded skin remained free of disease for more than 2½ years after surgery. It is suggested that skinplanning should include the entire papillary dermis in order to obtain the beneficial effect.

Key words: Darier's disease; Dermabrasion

Therapy for Darier's disease (keratosis follicularis) has until very recently been highly unsatisfactory. In general, treatment has had to be limited to eradication of bacterial infections, avoidance of maceration, protection from sunlight, and to a certain extent to a superficial removal of hyperkeratotic scales. Although recent studies on systemic treatment with vitamin A acid seem promising (3), much still remains to be done before a drug therapy for this disease can be declared adequate. Within the last 20 years a small number of reports have appeared regarding surgical therapy with dermabrasion (1, 2, 5, 7). However, these articles only cover

a very small number of patients. The present report describes the beneficial effect of dermabrasion on 5 patients with Darier's disease, observed over several years.

MATERIAL AND METHODS

Five patients, 3 men and 2 women, aged 22 to 56 years and suffering from severe Darier's disease, treated unsuccessfully with keratolytic agents, topical vitamin A acid, systemic vitamin A (3 patients), Vitamin E (1 patient) and systemic steroids (2 patients) underwent dermabrasion covering areas from 100 to 500 cm² per treatment.

Dermabrasion was performed either under general anesthesia or under local anesthesia with ethyl chloride spray together with 0.5 to 1% lidocaine. After completion of the procedure which was performed by the use of an electrically driven dermabrasion apparatus, the skin was covered with collagen film® (7) or Skin-tec® (4), the latter being found better suited for covered areas of the body while collagen film seemed better fitted for the face where no other covering was found necessary. In all cases dermabrasion was intended to reach and destroy the papillary dermis.

Two patients, in whom the severe lesions were limited to the trunk and particularly to the sternal area, received only one surgical treatment. The remaining 3 patients had dermabrasion done in respectively three, five and eight stages.

RESULTS

Re-epithelialization was rapid and the wounds healed completely within 2 weeks. Even in patients with severe disease, over 75% of the dermabraded

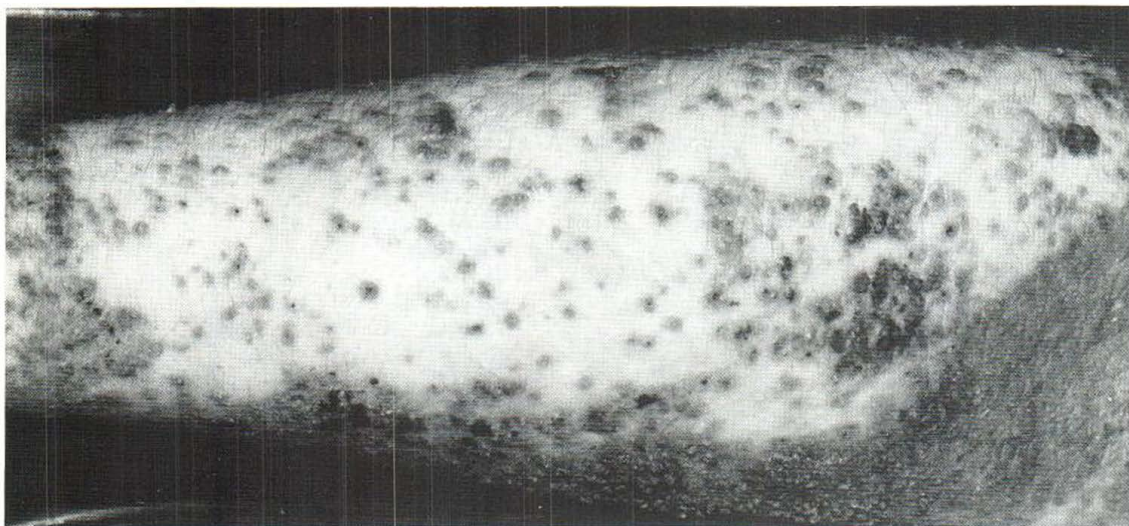


Fig. 1. Arm of 26-year-old female patient with severe Darier's disease 2½ years after dermabrasion. Note new

lesions at junction of dermabraded and non-dermabraded skin as well as within dermabraded areas.

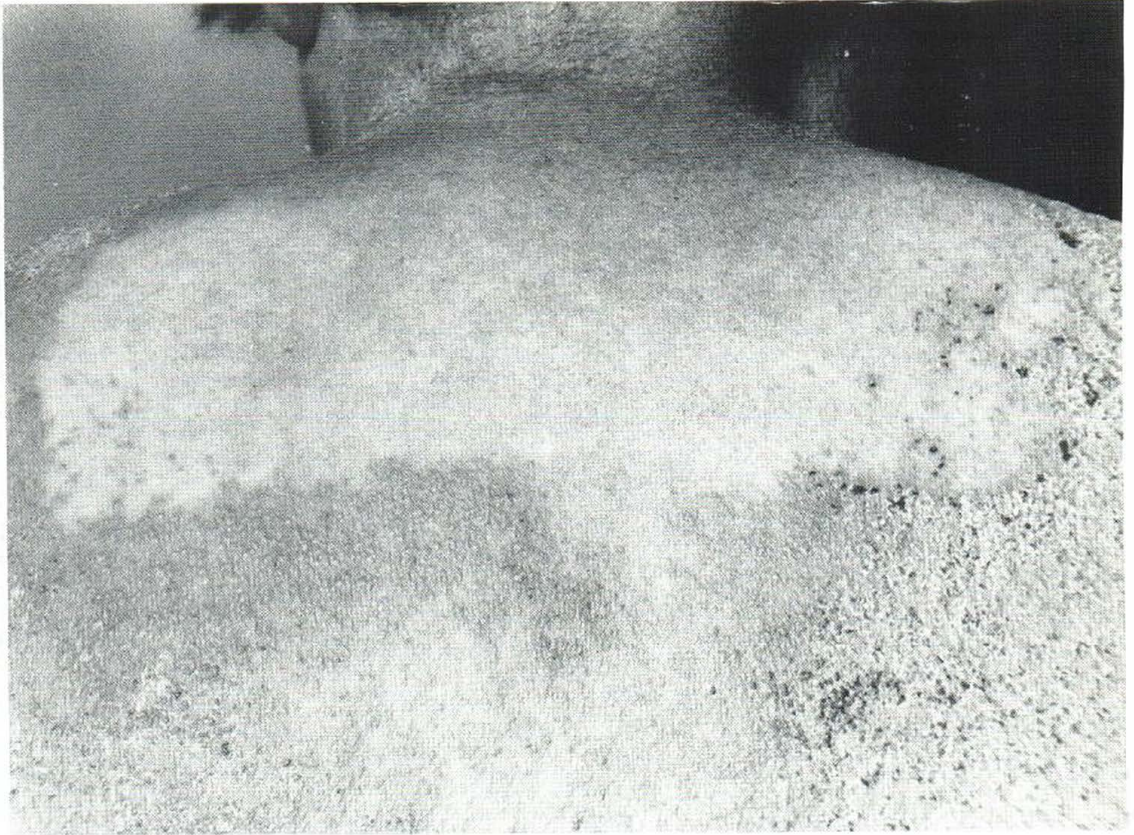


Fig. 2. Back of 56-year-old female patient with severe Darier's disease 3 years after dermabrasion. Note complete lack of scarring within treated area, which appears

almost free of lesions. Adjoining areas have subsequently been treated, with a similar beneficial result.

skin generally remained free of disease more than 2½ years after surgery (figure 1). The dermabraded skin was found almost normal in 1 patient 3 years after treatment (figure 2). In 1 patient where dermabrasion was done on the extremely heavily involved facial skin, the results were less satisfactory. However, even this patient obtained some benefit from the treatment and has asked for further surgery in spite of improvement following systemic vitamin A acid.

As can be seen in figure 1, occasional new lesions formed both at the junction of the treated and non-treated skin and within the dermabraded area. These recurrences have been re-dermabraded subsequently.

COMMENTS

The first documented report on the beneficial effect of skinplaning in Darier's disease was a case report

by Larnder in 1959 (5). He had an observation period of only 3 months. The present experience, together with other more recent data (1, 2, 6), indicates that dermabrasion of diseased skin in patients with Darier's disease provides the patients with prolonged periods of remission. This seems especially true whenever it is possible to perform the dermabrasion to an adequate depth.

The mechanism by which deep dermabrasion of diseased skin provides remissions is unclear. Cohen and co-workers (1) suggest that the papillary dermis is a prerequisite for the presence of the disease state. This may be true. Our findings indicate that the remissions may last even where no scarring can be seen (figure 2). The data presented here should encourage more active surgery whenever modern drug therapy does not lead to a satisfactory result in extensive Darier's disease.

REFERENCES

1. Cohen, K., Kraemer, K. & Peck, G.: Cornifying Darier disease—a unique variant. *Arch Dermatol* 112: 504, 1976.
2. De Dulanto, F., Sanchez-Muros, J. & Martin-Gomez, A.: Abrasion rotatoria en el tratamiento de la enfermedad de Darier. *Actas Dermosifiliogr* 59: 101, 1968.
3. Günther, S.: Vitamin A acid in Darier's disease. *Acta Dermatovener (Stockholm)* 55: Suppl. 74: 146, 1975.
4. Hansson, B. & Mannheimer, C.: Treatment of ischemic ulcers of geriatric patients with sterile frozen pig skin dressings. *Läkartidn* 72: 4736, 1975.
5. Larnder, D.: Darier's disease treated by dermabrasion. *Br J Dermatol* 71: 73, 1959.
6. Roenigk, H.: Dermabrasion for miscellaneous cutaneous lesions. *J Dermatol Surg Oncol* 3: 322, 1977.
7. Zachariae, H.: Wound dressing with collagen film in skinplaning. *Acta Dermatovener (Stockholm)* 56: 312, 1976.