

When liver enzymes had returned to normal, PUVA was started again because of a relapse of her skin disease. After only one treatment the patient had renewed symptoms of common cold, with fever and an elevation of ALAT and ASAT. After treatment was stopped, ALAT and ASAT returned to normal within 3 weeks (Fig. 1).

The patient was then challenged with a single dose of 40 mg 8-MOP without UVA and reacted only 2 hours later with chills, fever in excess of 39°C, a sensation of heat in her head and hands and a temporary elevation of ALAT and ASAT (Fig. 1).

DISCUSSION

Many reports on PUVA treatment have appeared during recent years. Some of them have described slight and transient elevations of liver enzymes which, however, have been attributed in most cases to pre-existing liver injury such as caused by abuse of alcohol or intake of other drugs (1, 4, 5). Transient elevations of liver enzymes have also been noted in two of our own PUVA patients (unpublished observation). We have been unable to find any reports in the literature documenting psoralens as being the cause of liver injury during PUVA treatment.

In the present case there is a clear correlation between liver injury and intake of 8-MOP as demonstrated by the reappearance of symptoms and laboratory abnormalities after repeated provocations. There was no history of preceding liver disease.

The liver damage seems to be of the hepatocellular and nonpredictable type. However, a liver biopsy was not available. The short delay between intake of the drug and symptoms suggests an allergic mechanism as a possible explanation. There are some similarities between this case and liver injury after halothane anaesthesia. Halothane has been reported to cause liver injury in a small number of patients receiving it. There was a significant relation between the number of exposures to this anaesthetic and the rapidity with which liver injury developed after exposure (2). Evidence has been provided that halothane may be immunogenic (6).

It may be of additional interest that imperatorin, a phototoxic furocoumarin isolated from various plants, such as *Ammi majus*, has been shown to induce cirrhotic changes in the liver of rats and to inhibit respiration and phosphorylation in isolated liver mitochondria (3). The chemical structures of imperatorin and 8-MOP are closely related.

Whether this may have any bearing upon the case reported here is not known, however.

REFERENCES

1. Dahl, K. B. & Brodthagen, H.: Treatment of psoriasis vulgaris with carbon-arc light baths and 8-methoxypsoralen. *Ugeskr Laeger* 138: 2221, 1976.
2. Inman, W. H. W. & Mushin, W. W.: Jaundice after repeated exposure to halothane: An analysis of reports to the Committee on Safety of Medicines. *Br Med J* i: 5, 1975.
3. Kramar, R. & Kaiser, E.: Effect of imperatorin, a toxic principle from *Ammi majus*, on energy-transfer in mitochondria. *Toxicol* 6: 145, 1968.
4. Swanbeck, G., Thyresson-Hök, M., Bredberg, A. & Lambert, B.: Treatment of psoriasis with oral psoralens and long wave ultraviolet light. Therapeutic results and cytogenetic hazards. *Acta Dermatovener (Stockholm)* 55: 367, 1975.
5. Weismann, K., Howitz, J. & Bro-Jørgensen, A.: Treatment of psoriasis with 8-methoxypsoralen and long-wave ultraviolet light. *Ugeskr Laeger* 138: 2225, 1976.
6. Williams, B. D., White, N., Amlot, P. L., Slaney, J. & Toseland, P. A.: Circulating immune complexes after repeated halothane anaesthesia. *Br Med J* ii: 159, 1977.
7. Wolff, K., Fitzpatrick, T. B., Parrish, J. A., Gschnait, F., Gilchrist, B., Hönigsmann, H., Pathak, M. A. & Tanenbaum, L.: Photochemotherapy for psoriasis with orally administered methoxsalen. *Arch Dermatol* 112: 943, 1976.

Comparison of Clobetasol Propionate and Betamethasone-17,21-Dipropionate with Reference to Adrenal Suppression

Knud Eriksen

*Department of Dermatology, Hvidovre Hospital,
University of Copenhagen, Denmark*

Received November 6, 1978

Abstract. 32 adult hospitalized patients with common skin disorders were controlled in a double-blind comparison study with clobetasol propionate (Dermovat®) and betamethasone-17,21-dipropionate (Diproderm®) with regard to adrenal suppression. The latter, when assessed by plasma cortisol, was significantly greater in the Dermovat-treated group after the 1st and 2nd week with daily treatment with both 25 g and 15 g ointment. Daily treatment of skin areas >25% with 25 g Diproderm® also showed clear adrenal suppression, whereas no such effect was obtained with daily treatment with 10 g Diproderm®

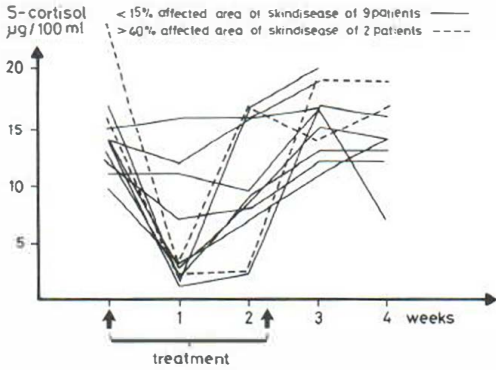


Fig. 1. Plasma cortisol levels in 11 patients treated with Dermovat®.

of skin areas <15%. In all cases, plasma cortisol levels were normal 1–2 weeks after the end of topical treatment.

Key words: Clobetazol propionate; Betamethasone-17,21-dipropionate; Comparative study; Adrenal suppression

Since hydrocortisone was first introduced for topical use in 1952 still more potent steroids have been developed, as judged by their clinical effect, vasoconstriction, and unwanted side effects (1, 5, 8, 9, 13). In recent years many authors have reported on local skin atrophy and suppression of the adrenal function (6, 7, 11, 12). This paper deals with one of the latest developed corticosteroids clobetasol propionate (Dermovat®) which is compared with betamethasone-17,21-dipropionate (Diproderm®) with regard to adrenal suppression.

Pharmacology

Clobetasol propionate is a double-halogenated corticosteroid. 0.05% of the steroid is dissolved in varying quantities of propylene glycol, formulating cream and ointment which is free from lanolin and aminobenzoic acids.

MATERIAL AND METHODS

32 adult hospitalized patients with common skin disorders were enrolled in a double-blind comparative study with Dermovat® and Diproderm® ointment. The skin disorders were represented by 20 cases of psoriasis vulgaris, 4 cases of dermatitis seborrhoica, 3 cases of dermatitis contactus, 3 cases of atopic dermatitis, and 2 cases of lichen planus. 11 patients were treated with Dermovat® and 21 patients with Diproderm®. For at least one week before the trial they had not been treated with topical corticosteroids, neither had any ever been systemically treated with steroids.

The lesions were treated twice daily until cure or until

200 g of the ointment had been applied. Occlusive treatment was not practised. The area of skin disorder, the quantity of ointment applied, and possible side effects were noted.

The percutaneous absorbed steroid effect was assessed by estimation of plasma cortisol levels 9 a.m. once a week and by estimation of oxogenic steroids (17 KGS) in 25 h urine samples before, during, and after the treatment.

The statistical examination was carried out in the form of a Mann-Whitney test.

RESULTS

The adrenal suppression judged by plasma cortisol was significantly greater in the dermivat-treated group after 1–2 weeks, compared with the diproderm-treated group ($p < 0.05$, Mean and S.E.M. after 1st and 2nd week were in the dermivat group 14.6 ± 1.1 and 5.7 ± 1.5 . In the diproderm group the values were 15.1 ± 1.3 and 10.8 ± 1.2 after the 1st and 2nd week), and that was seen with daily treatment with both 25 g and 15 g (Fig. 1). However, the plasma cortisol level became normal within 1–2 weeks.

15 patients from the diproderm group treated with 10 g ointment daily showed no adrenal suppression (Fig. 2), but in patients with larger lesions treated with Diproderm® a marked adrenal suppression was seen (Fig. 3). In this group, too, the adrenal suppression was transient.

The results of the steroid estimation of the 24 h urine samples reflected the plasma cortisol levels. With both preparations a moderate rebound-effect of the skin disorder was seen at the end of the investigation. In 3 cases of psoriasis, local pustulation was noted in patients from the dermivat-treated group.

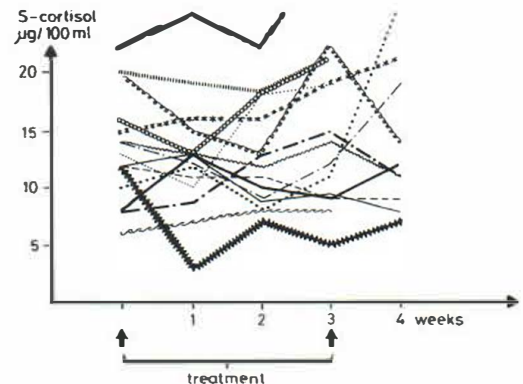


Fig. 2. Plasma cortisol levels in 15 patients treated with Diproderm®. Affected area of skin disease <15%.

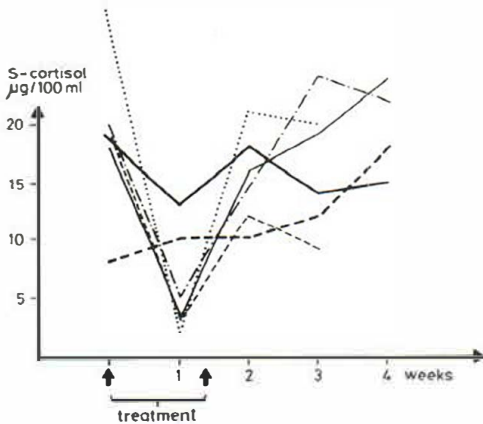


Fig. 3. Plasma cortisol levels in 6 patients treated with Diproderm®. Affected area of skin disease >25%.

DISCUSSION

Both Dermovat® and Diproderm® showed a systemic steroid effect which confirms previous investigations (2, 4, 10), but in the case of Diproderm® this was only seen in treatment of larger areas of skin (>25%) with daily quantities of ointment ≥ 25 g. After a rather brief period of treatment (max. 3 weeks) complete restoration of the adrenal function was noted. A similar restoration during continued daily treatment with 30–60 g Diproderm® has been reported (3) and suggests an adaptation to the percutaneously absorbed steroid, although the more precise details are not known.

The local side effects were few and moderate. In particular, no atrophy or cutaneous vessel disorders were seen.

Rebound-effect was seen in both groups which were dominated by patients with psoriasis, in whom rebound-effect is not unusual after termination of topical corticosteroid therapy.

Table 1. 32 patients treated with Dermovat®/Diproderm®

	Der- movat®	Dipro- derm®
Psoriasis vulgaris	6	14
Dermatitis contactus allergica	0	1
Dermatitis contactus toxica	1	1
Dermatitis seborrhoica	2	2
Lichen ruber	1	1
Prurigo besnier	1	2
Total	11	21

The potent steroids for topical use are valuable in the treatment of many skin disorders. A careful watch for possible systemic and local side effects must always be kept, however. Frequent checking of the patients is therefore necessary.

REFERENCES

1. Agrup, G., Lassus, A., Lidén, S., Osmundsen, P. E., Rajka, G. & Søndergaard, J.: Hvor stærke er steroidsalverne? *Ugeskr Læger* 26: 1565, 1978.
2. Björnberg, A. & Høllgren, L.: Treatment of psoriasis with clobetasol propionate: a double-blind comparison with betamethasone valerate. *Curr Med Res Opin* 3: 36, 1975.
3. Dowie, D. W., Cains, G. & Peek, R.: (personal communication).
4. Floden, C. H., Woodbridge, P., Samman, P. & Kurwa, A. R.: Comparison of the response of psoriasis over a 6-month period, to clobetasol propionate and fluocinolone acetonide ointments. *Curr Med Res Opin* 3: 375, 1975.
5. Friis, B. & Weismann, K.: Bivirkninger ved lokal kortikosteroidbehandling. *Ugeskr Læger* 134: 1608, 1972.
6. Gomez, E. C., Kaminester, L. & Frost, P.: Topical halcinonide and betamethasone valerate effects on plasma cortisol. *Arch Dermatol* 113: 1196, 1977.
7. Gruenberg, J. C. & Mikhail, G. R.: Percutaneous adrenal suppression with topically applied corticosteroids. *Arch Surg* 111: 1165, 1976.
8. Hjorth, N., Osmundsen, P. E., Rook, A. J., Wilkinson, O. S. & Marks, R.: Perioral dermatitis. *Br J Dermatol* 80: 307, 1968.
9. Knudsen, E. A.: Fluocinolone—Plastic treatment and traditional treatment in severe psoriasis. A comparative study. *Acta Dermatovener (Stockholm)* 45: 50, 1965.
10. Lassus, A.: Local treatment of psoriasis with desoxymethasone and betamethasone 17,21-dipropionate: a double-blind comparison. *Curr Med Res Opin* 4: 650, 1977.
11. Munro, D. D.: The effect of percutaneously absorbed steroids on hypothalamic-pituitary-adrenal function after invasive use in in-patients. *Br J Dermatol* 94: Suppl. 12: 67, 1976.
12. Sneddon, J.: Adverse effect of topical fluorinated corticosteroids in Rosacea. *Br Med J* i: 671, 1969.
13. Zachariae, H.: Comparison of desoximethasone and hydrocortisone butyrate in psoriasis. *Acta Dermatovener (Stockholm)* 56: 309, 1976.