

HISTIOCYTIC MEDULLARY RETICULOSIS PRESENTING AS MUCHA-HABERMANN DISEASE

Michael J. Freeman,¹ James S. Taylor,¹ Howard S. Levin,²
Paul G. Dymont,³ and Wilma F. Bergfeld¹

*Departments of ¹Dermatology, ²Pathology, and ³Pediatrics and Adolescent Medicine,
The Cleveland Clinic Foundation, Cleveland, Ohio, USA*

Abstract. Histiocytic medullary reticulosis (HMR) is a rare, progressive, fatal reticuloendothelial proliferative disorder. It was diagnosed in a 10-year-old boy who had pityriasis lichenoides et varioliformis acuta of Mucha-Habermann which was controlled by dapsone for 2 years. One month after cessation of dapsone therapy, cutaneous tumors associated with fever, lymphadenopathy, and hepatosplenomegaly developed. Tissue biopsy specimens of skin, liver, spleen, lymph nodes, and a bone marrow aspirate demonstrated histiocytic erythrophagocytosis and atypical histiocytosis compatible with HMR. A rapidly progressing, fatal course followed despite intensive chemotherapy.

Key words: Medullary reticulosis; histiocytic; Mucha-Habermann disease

Scott & Robb-Smith (20) defined an entity now known as histiocytic medullary reticulosis (HMR), a rapidly fatal reticuloendothelial proliferative disorder. The etiology is unknown, but there is a rapidly progressing and distinctive clinicopathologic course. The major clinical features are fever, emaciation, general lymphadenopathy, and marked hepatosplenomegaly. The major pathologic feature is proliferation of erythrophagocytic histiocytes, especially within the reticuloendothelial system.

Approximately 100 cases of HMR have been reported, and they were reviewed with special attention to the presence of any skin lesions (Table I). About 10% of HMR cases have associated skin lesions (1), and late in the clinical course purpura and jaundice occur. None of the previously reported cases were preceded by skin lesions of pityriasis lichenoides et varioliformis acuta of Mucha-Habermann disease (MHD).

Abele & Griffin (1) reviewed 83 reported cases of HMR and added two of their own. Since then skin lesions have been present in some of the cases reported by Engstrom et al. (10), Olsen (17), Byrne & Rappaport (5), and Warnke et al. (22).

This paper reports what we believe to be the first case of MHD eventuating in HMR; the diagnosis was established ante mortem. The clinical course, chemotherapy, and relation of this disorder to malignant histiocytosis are discussed.

CASE REPORT

History. A 7-year-old white boy was in good health until skin lesions appeared in June 1971. The lesions were described as small erythematous papules on his legs and buttocks, which resolved, leaving flat scars. A skin biopsy specimen showed lymphohistiocytic vasculitis and perivasculitis with associated epidermal spongiosis and prominent transmigration of mononuclear inflammatory cells with focal purpura compatible with MHD (Figs. 1 and 2). The lesions did not respond to corticosteroids given orally, but cleared dramatically with dapsone (Avlosulfon), 300 mg per day. The patient was maintained on 50 to 100 mg of dapsone per day from September 1971 through September 1973, and the eruption flared when the dose was reduced below this level. Frequent blood counts revealed only an initial hemoglobin drop which responded to iron administered orally. In October 1973 an ulceration developed over his left lateral knee, which progressed despite topical and systemic antibiotics and reinitiation of dapsone therapy. The patient was also noted to have hepatosplenomegaly, and daily fever spikes of 40°C (104°F). He was referred to the Cleveland Clinic in March 1974.

Physical examination. Abnormal findings were the patient's hepatosplenomegaly and two large ulcers 1 to 2 cm deep into muscle on his left lateral knee. Atrophic pigmented scars and small nodules were scattered on the

Table I. Early cutaneous lesions associated with histiocytic medullary reticulosis^a

| Author(s) | Description | Distribution | Age | Histopathology |
|----------------------------------|--|---|-----|--|
| Anderson (2) (1944) | Pimples and purplish nodules and plaques | Face, trunk, and extremities | 52 | None |
| Israels (13) (1953) | Small raised reddish papules | Abdomen | 30 | Diffuse infiltrate of abnormal histiocytes |
| Civin et al. (6) (1954) | Morbilloform discoloration, erythematous patches | Trunk, neck and extremities | 39 | Dermal infiltrates of atypical histiocytes |
| Friedman & Steigebeg (12) (1965) | Purple nodules | Forehead, scalp, extremities and back | 66 | Atypical histiocytes in dermis and fat |
| Natelson et al. (16) (1968) | Subcutaneous nodules | Trunk | 28 | Diffuse dermal infiltrate of histiocytes |
| DeVillier (9) (1968) | Skin nodules | Abdomen | 1 | Abnormal histiocytes in dermis |
| Abele & Griffin (1) (1972) | Erythematous papules | Face and trunk and proximal extremities | 17 | Abnormal histiocytes in dermis and fat |
| | Subcutaneous nodules | Trunk | 18 | Abnormal histiocytes in dermis and fat |
| Engstrom et al. (10) (1972) | Brown to purple nodules, tumors and plaques | Trunk and proximal extremities | 52 | Large atypical mononuclear cells and erythrophagocytosis |
| Olsen (17) (1973) | Vesicular rash, ulcerations, petechiae, tinea corporis and basal cell and squamous cell carcinomas | Generalized | 25 | Not reported |
| Warnke et al. (22) (1975) | Nodule | Thigh | 31 | Prominent erythrophagocytosis |
| | Nodules | Not reported | 33 | Atypical histiocytes |
| | Two other cases had skin lesions but no other details are presented | | | |
| Byrne & Rappaport (5) (1973) | Two cases with skin lesions, no clinical details presented | | | Atypical dermal histiocytes |
| Freeman et al. (present study) | Mucha-Habermann lesions nodules and ulcerations | Trunk and extremities | 10 | Abnormal histiocytes with erythrophagocytosis |

^a Table modified and additions made from original table by Abele & Griffin (2).

buttocks and extremities (Fig. 3). Two abscesses were present on the left leg.

Laboratory findings. The hemoglobin was 10.0 g/dl and white blood cell count 2300 with a normal differential count. A bone marrow aspirate was normal except for

scattered mature reticuloendothelial cells exhibiting striking erythrophagocytosis (Fig. 4). The urinalysis showed a trace of protein. The following tests were normal or negative: SMA-12, antinuclear factor, serum immunoglobulins, VDRL, and Coombs' test (direct and indirect). T

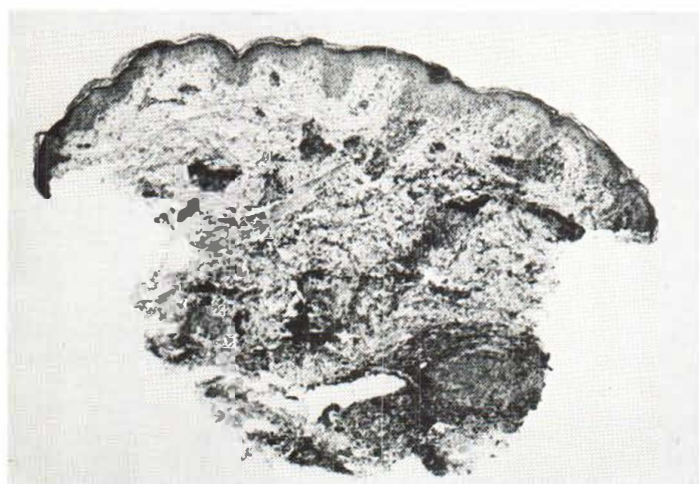

Fig. 1. Skin biopsy (1971) compatible with Mucha-Habermann disease. A dense perifollicular and perivascular mononuclear infiltrate (hematoxylin-eosin, $\times 9$).

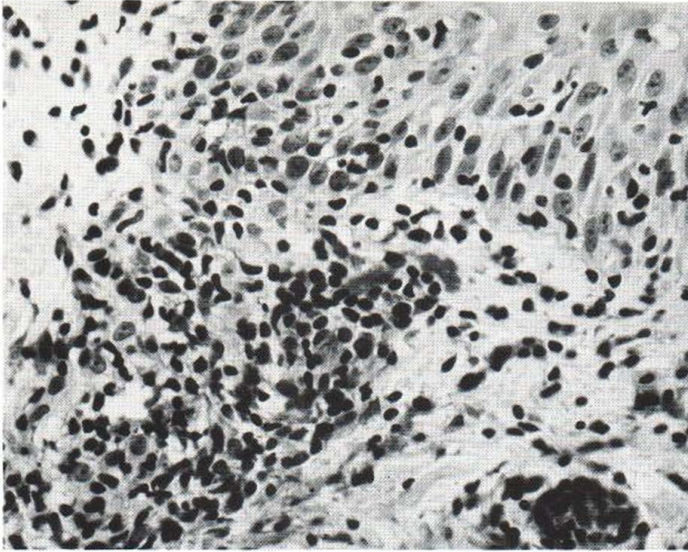


Fig. 2. Skin. Higher power picture of the case of Mucha-Habermann disease shown in Fig. 1. Reveals spongiosis, exocytosis of lymphocytes, perivasculitis, non-specific vasculitis and focal purpura (hematoxylin-eosin, $\times 90$).

cells were within normal limits, and there was a slight decrease in B cells. Intact delayed hypersensitivity was demonstrated.

Bacterial culture of various cutaneous ulcers grew *Staphylococcus aureus*. Fungal and acid-fast cultures showed no growth.

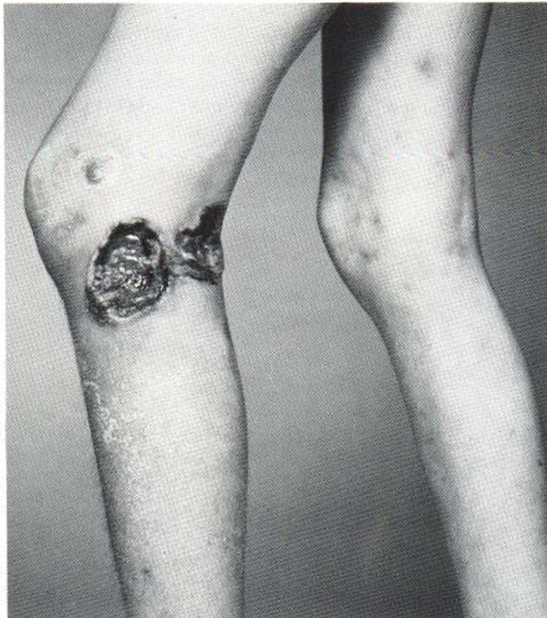

Fig. 3. The patient in March 1974. Two large irregular ulcerated areas on left leg with small nodule superior to the ulcers. Several atrophic pigmented scars and small nodules are scattered on the right leg and lower left leg.

Roentgenograms of the chest and skull and a bone survey were normal.

Hospital course and treatment. When the patient was admitted to the Cleveland Clinic Hospital in March 1974 he was anemic, neutropenic, and had borderline thrombocytopenia. Based upon the results of the skin biopsy (Figs. 5 and 6), which suggested a histiocytic lymphoma, a diagnostic and staging laparotomy with splenectomy was performed. The patient received a combination of vincristine, cyclophosphamide, and prednisone along with local

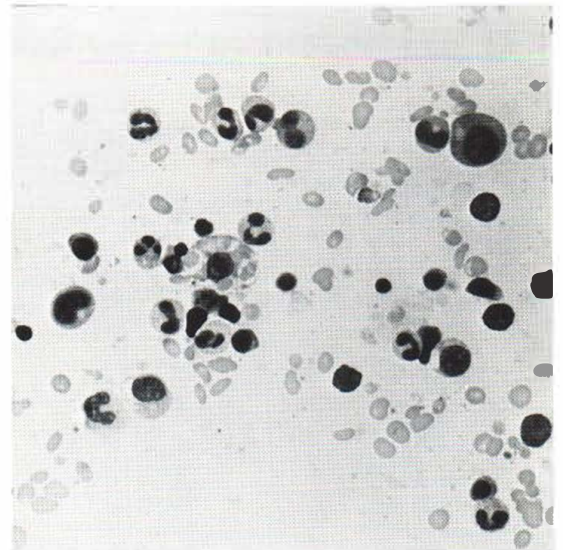


Fig. 4. Bone marrow aspirate. Scattered mature histiocytes with striking erythrophagocytosis in center of photo (hematoxylin-eosin, $\times 320$).

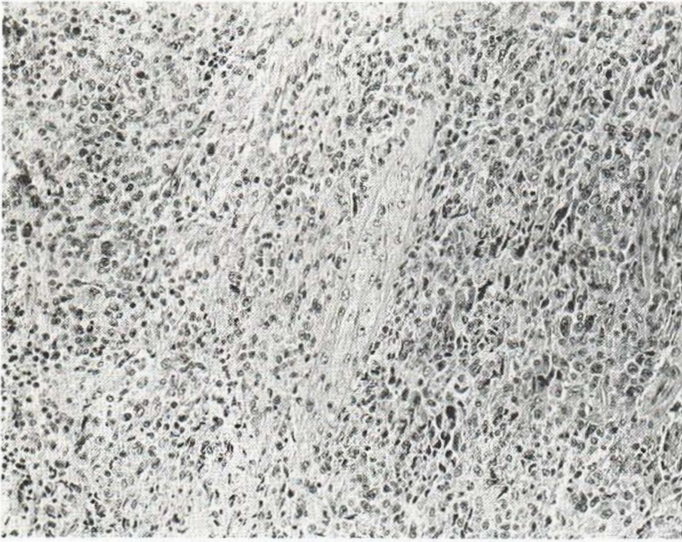


Fig. 5. Skin biopsy (1974) with massive dermal and subcutaneous infiltrate by neoplastic histiocytic cells in ulcerated lesion (hematoxylin-eosin, $\times 125$).

irradiation to his leg ulcers. The course of irradiation to the ulcers given on alternate days included 2 500 rads (250 KV, HVL 0.5 mmCu). A second pulse of chemotherapy was administered in May 1974.

His condition rapidly deteriorated and he died at home in July 1974; no post-mortem examination was performed. At the time of his death the disease was in full relapse.

Histopathologic findings. The first skin biopsy in August 1971, as described and shown in Fig. 1, was compatible with MHD. Skin biopsy specimens of the ulcerated cutaneous nodules in March 1974 revealed a massive dermal and subcutaneous infiltration by neoplastic cells (Fig. 5). These cells had enlarged, irregular, often indented vesicular nuclei with prominent nucleoli (Fig. 6). Multinucleate and multilobate cells were present along

with numerous mitotic cells, some of which were atypical. A few erythrophagocytic histiocytes were present.

Overlying the skin infiltrate was an area of ulceration. Adjacent squamous epithelium showed marked pseudoepitheliomatous hyperplasia with elongation of rete ridges, edema, and chronic inflammation of dermal papillae.

Biopsies were performed at laparotomy in March 1974. Sections of several lymph nodes showed striking sinus histiocytosis (Fig. 7). Myriads of benign appearing histiocytic type cells with abundant eosinophilic cytoplasm were present in the sinusoids and perinodal fat. Many of the cells showed erythrophagocytosis and a few contained phagocytized lymphocytes and cellular debris (Fig. 7).

However, the overall architecture of one lymph node

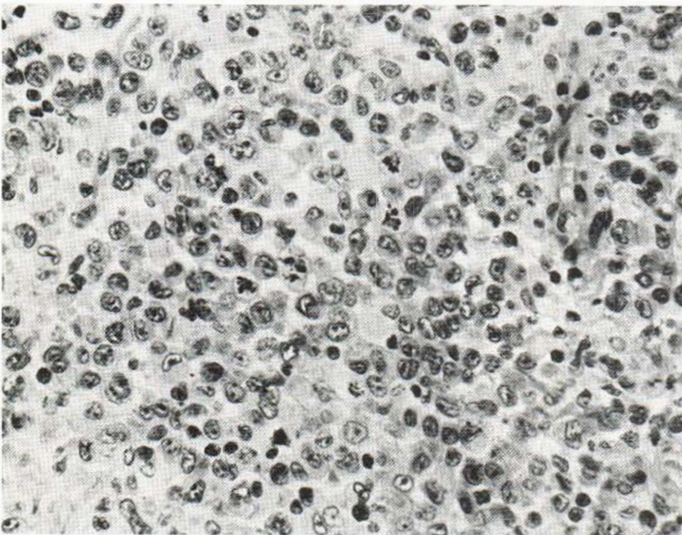


Fig. 6. Skin. Reveals enlarged irregular and indented nuclei of neoplastic cells. A higher power picture of Fig. 5. Four mitotic figures are seen in the center of the field (hematoxylin-eosin, $\times 310$).

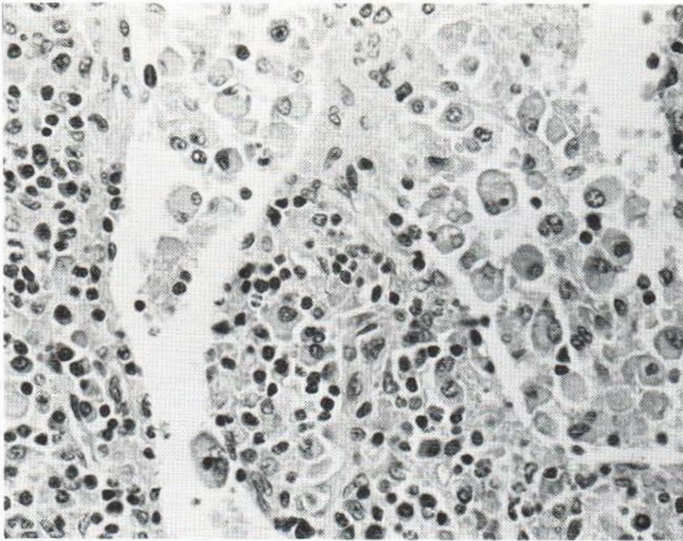


Fig. 7. Lymph node. Reveals striking sinus histiocytosis with erythrophagocytosis and a phagocytized lymphocyte (hematoxylin-eosin, $\times 310$).

showed it to be preserved with recognizable sinusoids, but there was an infiltration of sinusoids by histologically malignant cells which appeared to be similar to the cells infiltrating the skin of the thigh (Fig. 8). The neoplastic histiocytes in this lymph node did not show phagocytic activity.

A liver biopsy specimen showed that its architecture was maintained without massive cellular infiltration. The hepatic sinusoids contained numerous histiocytic type cells which did not show nuclear hyperchromasia. They had abundant eosinophilic cytoplasm and some phagocytosis of erythrocytes and lymphocytes.

Sections of the spleen revealed an intact architecture. The splenic sinusoids contained non-malignant appearing histiocytic cells with engulfed erythrocytes (Fig. 9).

DISCUSSION

Rappaport (18) defined histiocytosis as a systemic, progressive, irreversible proliferation of primitive reticular cells and their histiocytic derivatives. The systemic histiocytoses have been subdivided into malignant and benign categories. The histologically benign histiocytoses are generally recognized to be part of a disease spectrum (Histiocytosis X). Malignant histiocytosis is a much rarer condition. Byrne & Rappaport (5) tried to enlarge the criteria of Scott & Robb-Smith (20) to encompass the various subdivisions of malignant histiocytoses, one of

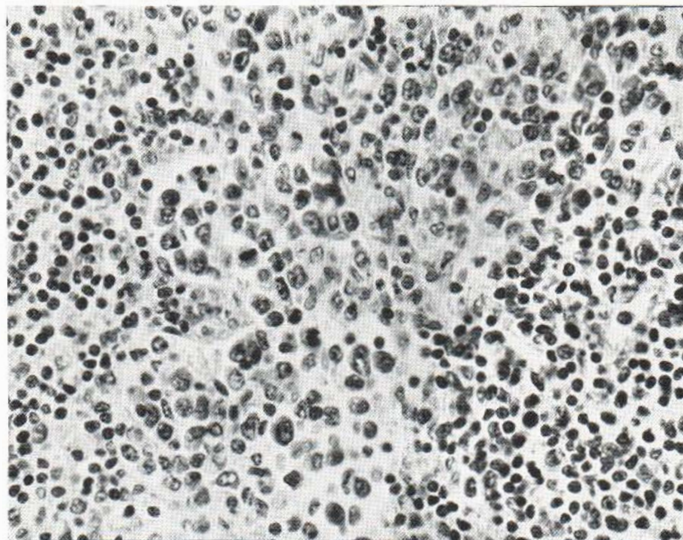


Fig. 8. Lymph node. Section of lymph node with sinusoids containing non-phagocytic histiocytes with enlarged irregular nuclei, prominent nucleoli, dense chromatin, and mitotic activity (hematoxylin-eosin, $\times 310$).

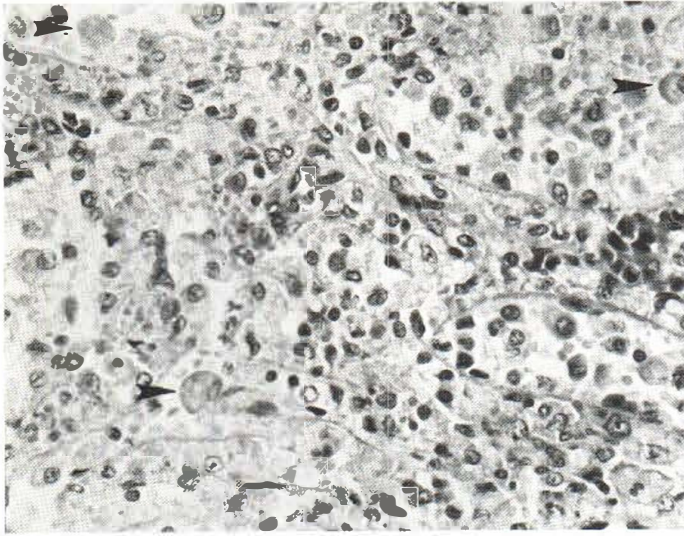


Fig. 9. Spleen. Splenic section with preservation of architecture, tremendous sinusoidal congestion, and histiocytic cells with abundant eosinophilic cytoplasm which are engulfing erythrocytes (arrow) (hematoxylin-eosin, $\times 310$).

which is HMR. In this condition the cells are morphologically abnormal histiocytes, which are found in the organs of the reticuloendothelial system. The degree of cellular differentiation varies considerably and as in this case, there may be extreme difficulty in recognizing the malignant nature of proliferating histiocytes in a given organ. In the present case, although the histiocytic proliferation was remarkable and the degree of erythrophagocytosis extensive, the histiocytes themselves had a morphologically benign appearance in some organs. Despite the presence of histologically benign histiocytes in the liver, spleen, and some lymph nodes, the histiocytes in one group of lymph nodes and in the massive infiltrate of the skin showed malignant histologic characteristics.

In the present case, malignant lymphoma was strongly considered in the differential diagnosis. However, careful study of the skin tumor revealed a diffuse infiltration by cells having the morphologic characteristics of histiocytes. In addition, no Reed-Sternberg cells were recognized; only rare cells showed erythrophagocytosis. Further study at the time of staging laparotomy revealed remarkable erythrophagocytosis in the organs. In the more recent classifications of malignant lymphoma, certain cases have been interpreted as being of histiocytic type (19). These tumors may be derived from lymphocytic precursors and histologically may differ distinctly in most organs from those in the present case. Although the distinction between

malignant lymphoma and malignant histiocytosis in the skin in this case is extremely difficult to ascertain, the changes in the other reticuloendothelial organs flatly contradict a diagnosis of malignant lymphoma. Malignant lymphoma is not characterized by erythrophagocytosis. Rather, in lymphomas the neoplastic cells are found in a nodular or diffuse distribution in the various organs. Histologic, electron microscopic, and cell surface studies of this patient's cells by Robinowitz (unpublished data) indicate a histiocytic origin for this tumor. The fact that some histiocytic elements in this neoplasm are histologically benign and non-invasive raises the question of a multifocal origin, in which the histologically benign cells show the phagocytic qualities of histiocytes, and the more atypical cells show the infiltrating quality of malignancy.

Lymphomatoid papulosis (LP), described by Verallo & Haserick (21) and so named by Macaulay (15) has clinical lesions similar to MHD and biopsy findings suggestive of lymphoma cutis with a usually benign clinical course. In 2 cases reported recently, LP transformed into malignant lymphomas and in a third it became mycosis fungoides (3, 11, 14).

Our case is not considered LP because of the benign appearance of the initial skin biopsy in 1971 and the patient's subsequent clinical course. He had been taking dapsone, which is known to cause several rather distinctive clinical manifestations such as leukopenia, anemia, methemoglobinemia,

hemolysis, and the "fifth week diphenyl sulfone dermatitis" syndrome (8). Some features of the latter, especially hepatomegaly and lymphadenitis, were present in our patient.

However, he had been taking dapsone for 2 years without any adverse effect, and the lesions of HMR developed after withdrawal of the drug. The usual course of MHD is 3 weeks to 3 months, with some cases persisting for several years. However, cases of MHD lasting several years are notoriously resistant to all forms of treatment, and rare sequelae are reported.

Febrile ulceronecrotic MHD has been reported by Degos et al. (7), and by Burke et al. (4). These cases were characterized by a fulminating course with fever, weakness, cutaneous ulceration and a leukocytoclastic angitis. No abnormal histiocytes were present and all 4 patients recovered.

One of the unusual facets of this case is that in June 1971 the patient had clinical and histopathologic evidence of MHD which lasted 2 years. There was no evidence of any systemic disorder during this time. In the previously reported cases of HMR associated with skin lesions, the systemic disease and malignant skin involvement always occurred simultaneously. In October 1973, tumors and ulcers developed in our patient and were later confirmed to be HMR, which followed the usual rapid and invariably fatal course. The average duration of HMR from onset of symptoms to death is 4 to 6 months (1, 5).

Thus, we do not consider our patient to have had an unusually long course (2 years plus) of HMR. Rather, we feel he most probably had MHD which progressed to HMR, or the two diseases occurred independently and sequentially.

Since the relationship between MHD and HMR is unknown, this case should alert one to the rare possibility of a malignancy developing in a patient after MHD has been diagnosed. Since cases of MHD simulating lymphoma cutis (LP) have eventuated in lymphoma (3, 11, 14) close follow-up of MHD is encouraged.

ACKNOWLEDGEMENT

We thank Charles Wingert, Jr, M.D., State College, Pennsylvania, for referring this pleasant, puzzling, and challenging patient.

REFERENCES

1. Abele, D. C. & Griffin, T. B.: Histiocytic medullary reticulosis. *Arch Dermatol* 106: 319, 1972.
2. Anderson, R. G.: Histiocytic medullary reticulosis with transient skin lesions. *Br Med J*: 220, 1944.
3. Black, M. M. & Wilson Jones, E.: "Lymphomatoid" pityriasis lichenoides; a variant with histological features simulating a lymphoma; a clinical and histopathological study of 15 cases with details of long term follow-up. *Br J Dermatol* 86: 329, 1972.
4. Burke, D. P., Adams, R. M. & Arundell, F. D.: Febrile ulceronecrotic Mucha-Habermann's Disease. *Arch Dermatol* 100: 200, 1969.
5. Byrne, G. E., Jr, & Rappaport, H.: Malignant histiocytosis. *Gann Monograph on Cancer Research* 15, 1973.
6. Civin, H., Gotschalk, H. C. & Okazaki, K.: Histiocytic medullary reticulosis; report of two cases. *Arch Intern Med* 94: 375, 1954.
7. Degos, R., Duperrat, B. & Daniel, F.: Le parapsoriasis ulcéronécrotique hyperthermique. *Annal Dermatol Syphiligr* 93: 481, 1966.
8. DeGowin, R. L.: A review of therapeutic and hemolytic effects of dapsone. *Arch Intern Med* 120: 242, 1967.
9. DeVillier, D. M.: Histiocytic medullary reticulosis. *South African Med J* 43: 756, 1968.
10. Engstrom, P. F., Aeling, J. L. & Suringa, D. W. R.: Histiocytic medullary reticulosis with cutaneous lesions. *Arch Dermatol* 106: 369, 1972.
11. Fine, R. M., Meltzer, H. D. & Rudner, E. J.: Lymphomatoid papulosis eventuating in mycosis fungoides. *South Med J* 67: 1492, 1974.
12. Friedman, R. M. & Steigbeil, N. H.: Histiocytic medullary reticulosis. *Am J Med* 38: 130, 1965.
13. Israels, M. C. G.: The reticulosis; a clinicopathological study. *Lancet* 265: 525, 1953.
14. Kawada, A., Anekoji, K., Miyamoto, M., et al.: Unusual manifestation of malignant reticulosis of the skin; cutaneous lesion simulating parapsoriasis guttata. *Dermatologica* 138: 369, 1969.
15. Macaulay, W. L.: Lymphomatoid papulosis; a continuing self-healing eruption clinically benign-histologically significant. *Arch Dermatol* 97: 23, 1968.
16. Natelson, E. A., Lynch, E. C., Hettig, R. A., et al.: Histiocytic medullary reticulosis; the role of phagocytosis in pancytopenia. *Arch Intern Med* 122: 223, 1968.
17. Olsen, T.: Histiocytic medullary reticulosis; a post-mortem finding in a patient with erythroleukemia and skin carcinomata. *Med J Aust* 1: 242, 1973.
18. Rappaport, H.: Tumors of the hematopoietic system. *In Atlas of Tumor Pathology*, pp. 49-63. Armed Forces Institute of Pathology, Washington, D.C., 1966.
19. Rebeck, J. W., Berard, C. W. & Abell, M. R.: The Reticuloendothelial System, p. 263. (International Academy of Pathology) Williams and Wilkins, Baltimore, 1975.
20. Scott, R. D. & Robb-Smith, A. H. T.: Histiocytic medullary reticulosis. *Lancet* ii: 194, 1939.

21. Verallo, V. M. & Haserick, J. R.: Mucha-Habermann's disease simulating lymphoma cutis. *Arch Dermatol* 94: 295, 1966.
22. Warnke, R. A., Kim, H. & Dorfman, R. F.: Malignant histiocytosis (histiocytic medullary reticulosis). I. Clinicopathologic study of 29 cases. *Cancer* 35: 215, 1975.

Received November 8, 1976

J. S. Taylor, M.D.

Department of Dermatology
The Cleveland Clinic Foundation
The Clinic Center, 9500 Euclid Avenue
Cleveland, Ohio 44106, USA