

PARAKERATOSIS IN SOME EPIDERMAL TUMORS:
FINE STRUCTURAL AND IMMUNOHISTOCHEMICAL SIMILARITY BETWEEN
PARAKERATOSIS AND "HORNMARK"-LIKE STRUCTURE

Shunji Kimura

Department of Dermatology, Keio University School of Medicine, Shinjuku, Tokyo, Japan

Abstract. Both parakeratosis and "Hornmark"-like structure are basic histopathologic changes found in a variety of skin lesions. In order to investigate more closely the architecture and components of these two structures, three cases of epidermal tumor which showed both parakeratosis and "Hornmark"-like structure were studied by using routine histology and histochemistry, immunofluorescence technique, and electron microscopy. In the intercellular space of the stratum corneum in these two structures, diastase-resistant PAS-positive substance was found. This substance also showed positive immunofluorescence for immunoglobulins, complement, and fibrinogen. Electron microscopically, this substance was moderately electron-dense and fine granular, and was located in the intercellular space and in part in the cytoplasm of the horny cells. On the basis of these findings, this substance was judged more likely to be derived from the components of plasma protein than a result of the degeneration of epidermal cells. Only quantitative difference was observed between these two structures. This substance was considered to play an important role on the increased cohesiveness of the horny cells. However, whether this is a product of antigen-antibody reactions, or the result of the process similar to blood coagulation, remains to be elucidated.

Key words: Parakeratosis; "Hornmark"-like structure; Immunofluorescence technique; Electron microscopy; Plasma protein

"Hornmark"-like structure, first described as "Hornmark" by Simon (11), has a columnar and

reticular architecture, and is usually found in the epidermis over the elongated and edematous dermal papillae of cutaneous horns and allied disorders, such as warts and papillomas (1, 13). We have applied immunofluorescence technique and electron microscopy to the study of cutaneous horns, and have found that a homogeneous substance in "Hornmark"-like structure consisted mainly of the components derived from plasma protein, such as fibrinogen, immunoglobulins, and complement (8, 9).

Parakeratosis is an imperfect form of keratinization with remnants of nuclei in the horny layer and is encountered in a variety of inflammatory dermatoses and skin tumors. Since there seemed to be a histological similarity between parakeratosis and "Hornmark"-like structure, we have applied immunofluorescence technique and electron microscopy to these two structures seen in some epidermal tumors in order to gain more precise information about the components and mechanism of parakeratosis, and to compare these two structures.

MATERIALS AND METHODS

Three cases of epidermal tumor, of which one was seborrheic keratosis, one senile keratosis, and one arsenical keratosis, were examined. Clinical data are shown in

Table I. *Present cases of epidermal tumors*

Case	Age	Sex	Site	Onset	Surface hue	Pathological diagnosis
1	73	♂	Thigh	50 years	Brown	Seborrheic Keratosis
2	66	♀	Nose	9 months	Brown	Senile Keratosis
3	65	♂	Wrist	3 months	Yellow	Arsenical Keratosis

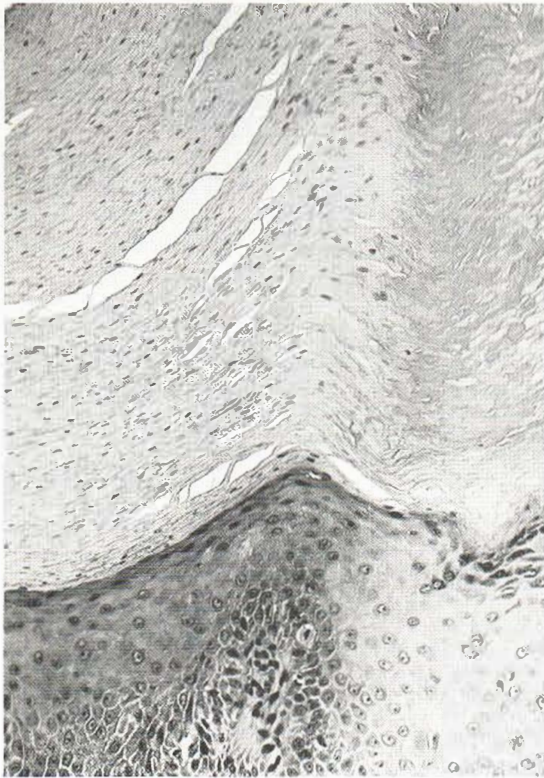


Fig. 1. Parakeratosis in case 3. H & E. $\times 170$.

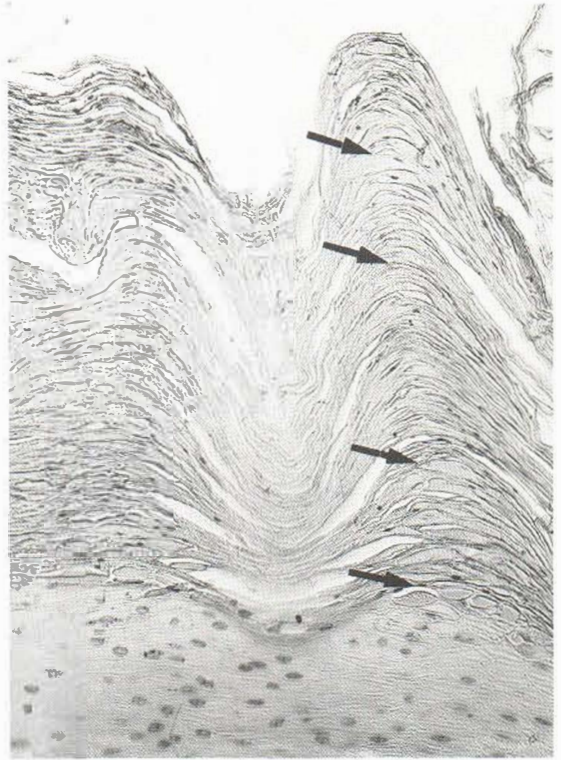


Fig. 2. "Hornmark"-like structure (arrows) in case 1. H & E. $\times 170$.

Table I. Each case showed both parakeratosis (Fig. 1) and "Hornmark"-like structure (Fig. 2) at routine histology, and was examined by histochemistry, immunofluorescence technique, and electron microscopy.

Histologic studies. Formalin-fixed and paraffin-embedded sections were stained with Hematoxylin and Eosin, Periodic acid-Schiff (PAS) with or without diastase digestion, and colloidal iron (Rinehart method) with or without bovine testicular hyaluronidase digestion.

Studies by direct immunofluorescence technique. One-half of each specimen was quick-frozen at -20°C and sectioned in a cryostat at $6\ \mu\text{m}$ thickness. Unfixed frozen sections were stained with FITC-labelled anti-human IgG (Dako, Lot 036, F/P under 4.0), IgA (Hyland, Lot 2212R001A1, F/P 2.5), IgM (Dako, Lot 016, F/P under 4.0), C3 (Hyland, Lot 2210T004A1, F/P 2.5), and fibrinogen (Dako, Lot 104, F/P under 4.0) according to the method described by Coons et al. (5). Each anti-serum was used at 1:20 dilution with phosphate-buffered saline (PBS, pH 7.4). As a control, blocking tests were performed with non-labelled anti-sera without dilution. FITC-labelled anti-*Sporothrix schenckii* anti-serum (supplied from the Center for Disease Control, Ga., USA; $8\times$) was also applied to each section. Stained sections were observed under a Tiyoda fluorescence microscope (FM 200B) equipped with Osram HBO 200 and darkfield con-

densor. Photomicrographs were taken on Kodak Ektachrom EH 135.

Electron microscopic studies. Specimens were fixed for 2 hr in 2% glutaraldehyde in Millonig's phosphate buffer at pH 7.3, and for 2 hr in 1% osmium tetroxide in the same buffer. They were dehydrated in graded ethanols, substituted by QY-1, and embedded in epoxy resin. After polymerization of the resin for 72 hr at 53°C , the blocks were ultrathin sectioned and stained with uranyl acetate and lead citrate. Photomicrographs were taken on a Hitachi HU-12AS electron microscope at 80 kV.

RESULTS

Each case showed features typical of both parakeratosis and "Hornmark"-like structure in their epidermis. Histochemically, strongly or moderately PAS-positive and in part diastase-digestible substance was observed in the intercellular space of the horny layer in these two structures. Only quantitatively, a greater amount of PAS-positive substance was observed in "Hornmark"-like

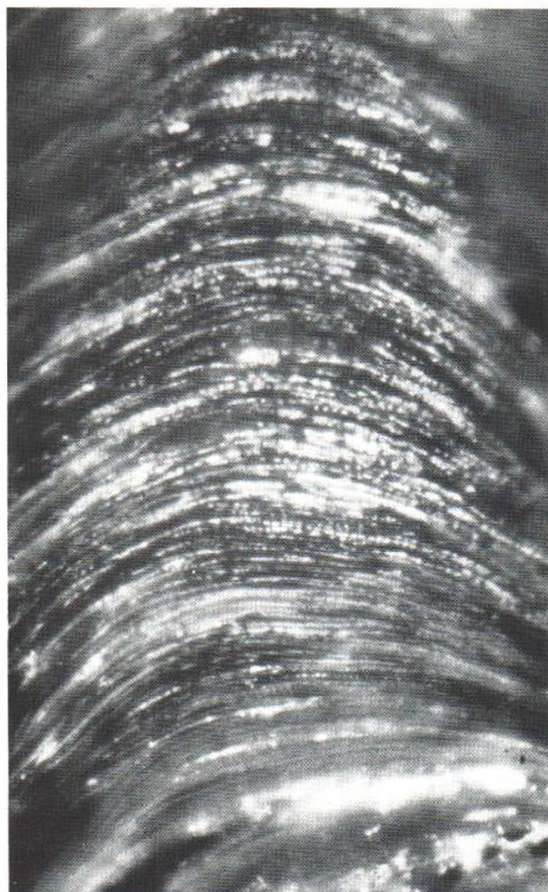


Fig. 3. Parakeratosis in case 2 stained with FITC-labelled anti-human fibrinogen to show linear deposition of fibrinogen in the intercellular space of the parakeratotic horny layer. $\times 1\ 400$.

structure than in parakeratotic areas. This substance was usually colloidal iron negative.

Immunohistochemically, strongly positive immunofluorescence for IgG, IgA, IgM, C3, and fibrinogen, respectively, was encountered in the intercellular space of the horny layer in both parakeratotic areas and "Hornmark"-like structure in all cases (Table II). This positive fluorescence was blocked by the pretreatment of non-labelled antisera against IgG, IgA, IgM, C3, and fibrinogen. In parakeratotic areas, linear deposition of these immunoglobulins, complement, and fibrinogen was observed mainly between the horny cells (Fig. 3). In "Hornmark"-like structure, oval or spindle-form deposition was observed mainly in the intercellular space of the horny layer (Fig. 4).

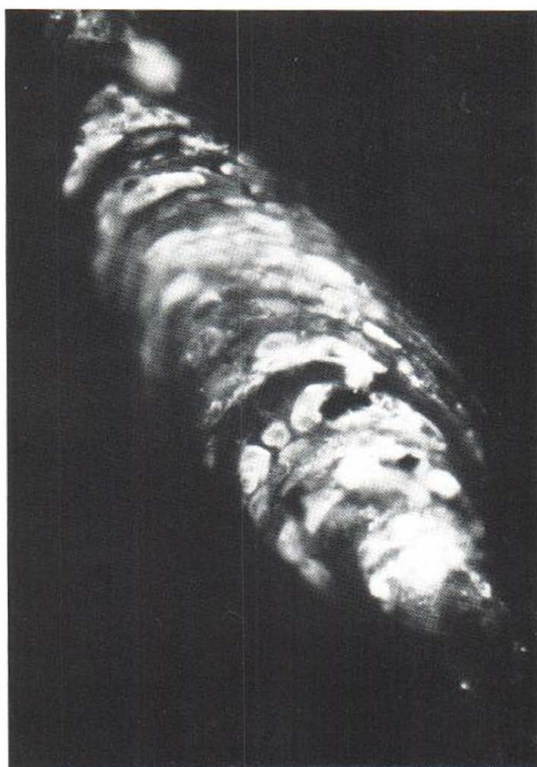

Fig. 4. "Hornmark"-like structure in case 2, stained with FITC-labelled anti-human fibrinogen to show oval or spindle-form deposition of fibrinogen. $\times 700$.

No immunofluorescence was observed in ortho-hyperkeratotic areas on application of FITC-labelled anti-human IgG, IgA, IgM, C3, and fibrinogen antisera. No positive fluorescence was observed in either parakeratotic areas or "Hornmark"-like structure with FITC-labelled anti-*S. schenckii* antiserum. These findings suggested that the deposition of these plasma proteins observed by immunofluorescence was specific.

Electronmicroscopically, alterations in the in-

Table II. Results of immunofluorescence staining

FITC-labelled antiserum	Parakeratosis	"Hornmark"-like structure
Fibrinogen	Positive	Strongly positive
IgG	Positive	Strongly positive
IgA	Positive	Strongly positive
IgM	Positive	Strongly positive
C 3	Positive	Strongly positive
<i>S. schenckii</i>	Negative	Negative

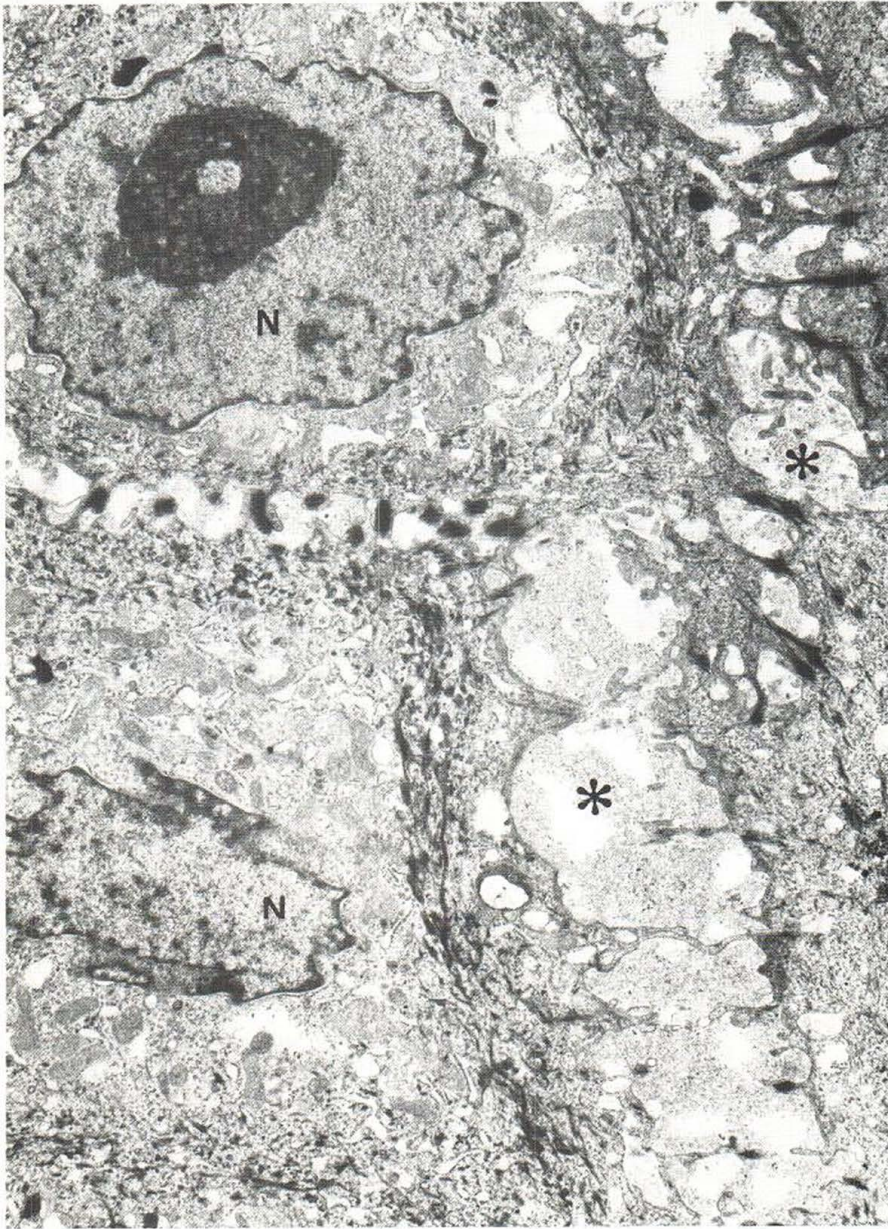

Fig. 5. Moderately electron-dense and fine granular substance (*) in the intercellular space of the prickle cell layer in case 2. N, Nucleus. $\times 9\ 000$.

tercellular space of the epidermis were demonstrated in both parakeratotic areas and "Hornmark"-like structure. Moderately electron-dense, fine granular and in part fine fibrillar substance was observed in the intercellular space of the Malpighian layer and sometimes in the cytoplasm of

the basal and prickle cells (Fig. 5). In the upper layer, the substance became more compact, and was observed in the intercellular space of the horny layer and in the cytoplasm of the horny cells (Fig. 6). In "Hornmark"-like structure, the substance was more abundant than in parakeratotic areas.

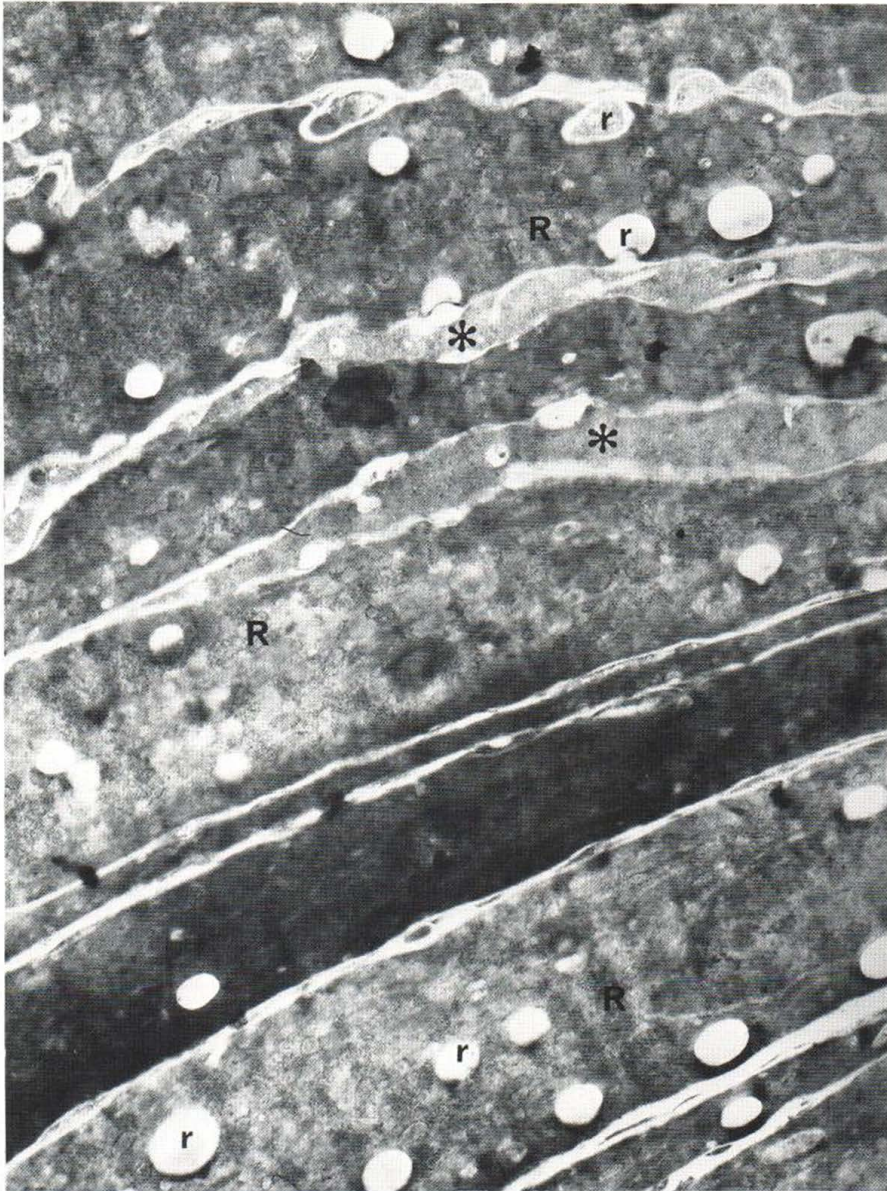


Fig. 6. Moderately electron-dense and fine granular substance (*) in the intercellular space of the parakeratotic horny layer in case 3. Round and oval bodies (r) seem to

be connected with the intercellular space. R: Ribosomes. $\times 17\,500$.

Sometimes, clefts were formed between the substance and the horny cells. Round and oval bodies were observed in the cytoplasm of the horny cells. Most of these bodies did not contain inclusions, but small amounts of homogeneous or fine granular substance were present in some places. These bodies seemed to communicate with the adjacent intercellular space, as shown in Fig. 6.

DISCUSSION

Earlier histological and histochemical studies on "Hornmark"-like structure indicated that the homogeneous substance found in this structure derived from the degenerated epidermal cells (1, 12, 13). Mainly on the basis of our previous studies on cutaneous horns (8, 9), it was surmised that this substance was derived not from the epidermal cells

but from the components of plasma protein. In the present study, we compared parakeratosis with "Hornmark"-like structure, and carried out the immunohistochemical and fine structural comparison between these two structures. From the findings of these studies, it can be concluded that there is no qualitative difference between the substance in parakeratosis and the one in "Hornmark"-like structure, but only a quantitative difference between them. In other words, "Hornmark"-like structure is merely an exaggerated form of parakeratosis and has larger amounts of the substance in the intercellular spaces. This substance, seen in these two structures, consists mainly of the components of plasma protein and may be a secondary product of inflammation or degeneration of the dermal papillae and overlying epidermis.

A similar substance has been found in the stratum corneum of parakeratotic psoriatic epidermis by using the immunofluorescence technique by Beutner et al. (2), Jablonska et al. (7), and Braun-Falco (3). They found IgG deposition in the intercellular space of the psoriatic horny layer and concluded that this deposition was a result of an antigen-antibody reaction. Brody (4), Hashimoto et al. (6), and Orfanos et al. (10) have published a number of electronmicroscopic studies on psoriatic epidermis and pointed out that the dilated intercellular space of the horny layer contained homogeneous, rather opaque substance and that round and oval, fairly opaque bodies were observed in varying numbers in the horny cells. The moderately electron-dense, fine granular substance in the intercellular space of the neoplastic epidermis, and round and oval bodies in the cytoplasm of the epidermal cells, as observed in our cases, are very similar to those reported by Brody et al.

We have already pointed out from histological, histochemical, immunohistochemical, and electronmicroscopical findings on cutaneous horns (8, 9) that "Hornmark"-like structure was probably a secondary change resulted from elongation and edema of the dermal papillae as well as from proliferation and degeneration of the epidermis, and that the homogeneous substance observed in this structure might, by its cohesive property, play an important role in the formation of cutaneous horns and allied disorders. Since "Hornmark"-like structure is considered to be an exaggerated form of parakeratosis, a similar property may be ascribed to

the substance observed in parakeratosis. Brody (4) is of the opinion that the substance in the intercellular space may well form the morphological basis for the increased cohesiveness of the horny cells observed in parakeratotic psoriatic epidermis.

In conclusion, it can be stated that there are identical characteristics in parakeratosis and "Hornmark"-like structure and there may be a considerable similarity between parakeratosis in tumors and that in psoriasis. The components of plasma protein observed in these two structures may play an important role in the increased cohesiveness of the horny cells and in the increased difficulty in shedding them. However, whether these are products of antigen-antibody reactions or the result of a process similar to blood coagulation remains to be elucidated.

ACKNOWLEDGEMENTS

I thank Prof. H. Hatano and Ass. Prof. M. Nagashima for their helpful suggestions and kind review of the manuscript.

REFERENCES

1. Alkiewicz, J., Lebioda, J. & Rokita, Z.: Über Kolloidkeratose. *Dermatol Monatsschr* 158: 329, 1972.
2. Beutner, E. H., Jablonska, S., Jarzabek-Chorzelska, M., Marciejowska, E., Rzesa, G. & Chorzelski, T. P.: Studies in immunodermatology. VI. IF studies of autoantibodies to the stratum corneum and of in vivo fixed IgG in stratum corneum of psoriatic lesions. *Int Arch Allergy Appl Immunol* 48: 301, 1975.
3. Braun-Falco, O.: Neuere Aspekte zur Pathogenese der Hauterscheinungen bei Psoriasis vulgaris. *Hautarzt* 27: 363, 1976.
4. Brody, I.: The ultrastructure of the horny layer in normal and psoriatic epidermis as revealed by electron microscopy. *J Invest Dermatol* 39: 519, 1962.
5. Coons, A. H. & Kaplan, M. H.: Localization of antigen in tissue cells. II. Improvements in a method for the detection of antigen by means of fluorescent antibody. *J Exp Med* 91: 1, 1950.
6. Hashimoto, K. & Lever, W. F.: Elektronen mikroskopische Untersuchungen der Hautveränderungen bei Psoriasis. *Dermatol Wschr* 152: 713, 1966.
7. Jablonska, S., Chorzelski, T. P., Jarzabek-Chorzelska, M. & Beutner, E. H.: Studies in immunodermatology. VII. Four-compartment system studies of IgG in stratum corneum and of stratum corneum antigen in psoriasis and control dermatosis. *Int Arch Allergy Appl Immunol* 48: 324, 1975.
8. Kimura, S.: Cutaneous horns. With special reference to genesis and function of "Hornmark". *J Keio Med Soc* 53: 537, 1976. (In Japanese.)
9. — Composition and function of "Hornmark" in cutaneous horns. *Arch Derm Res* 259: 161, 1977.

10. Orfanos, C. E., Schaumburg-Lever, G., Mahrle, G. & Lever, W. F.: Alterations of cell surfaces as a pathogenetic factor in psoriasis. *Arch Dermatol* 107: 38, 1973.
11. Simon, G.: *Die Hautkrankheiten*. p. 38, Berlin, 1848. Quoted from Unna (12).
12. Unna, P. G.: Das Fibrokeratom. *Dtsch Zschr Chirurg* 12: 267, 1880.
13. Veress, F. V.: Über die Histologie und Pathogenese der Hauthörner. *Monatsschr Prakt Derm* 46: 1, 1908.

Received March 21, 1977

S. Kimura, M.D.
Department of Dermatology
Keio University School of Medicine
Shinjuku
Tokyo, 160
Japan