

The intercellular IgG disappeared from the skin 6 months after therapy was commenced. When this phenomenon has been studied in a few other cases, positive intercellular staining has been shown to persist after therapeutic remission. The accepted indication of remission in pemphigus vulgaris is a fall in titre of desmosome antibody (2, 6, 7) but in this patient the disappearance of the antibody did not denote remission, since a reduction in therapy at this time precipitated a relapse.

Detailed and repeated immunofluorescence investigations have not previously been reported in childhood pemphigus vulgaris and the unusual findings in this patient suggest that the disease in adolescents may behave differently from that occurring in adults.

#### REFERENCES

1. Beuray, J., Duheille, J. & Montet, Y.: Conflit antigène—anticorps révélé par l'immunofluorescence dans le pemphigus. *Bull Soc Fr Dermat Syph* 74: 70, 1967.
2. Beutner, E. H., Chlorzelski, T. P., Bean, S. F. & Jordon, R. E.: *Immunopathology of the Skin: Labeled Antibody Studies*, chapter 2, p. 37. Dowden, Hutchinson & Ross, Inc., Stroudsburg, Pennsylvania, 1973.
3. Beutner, E. H., Chlorzelski, T. P. & Jordon, R. E.: *Autosensitization in Pemphigus and Bullous Pemphigoid*, chapter 3, Ch. C. Thomas, Springfield, Illinois, 1970.
4. Jordon, R. E., Schroeter, A. C., Rogers, R. S. & Perry, H. O.: Classical and alternate pathway activation of complement in pemphigus vulgaris lesions. *Invest Dermatol* 63: 256, 1974.
5. Menter, M. A., Bell, A. A. & Wells, R. S.: Pemphigus vulgaris in a boy aged thirteen. *Guy's Hosp Rep* 122: 123, 1973.
6. Sams, W. M. & Jordon, R. E.: Correlation of pemphigoid and pemphigus antibody titre with activity of disease. *Br J Dermatol* 84: 7, 1971.
7. Thivolet, J. & Beyvia, A. J.: Anticorps auto-epiderme dans les dermatoses bulleuses (documents cliniques et expérimentaux). *Bull Soc Fr Dermat Syph* 74: 300, 1967.
8. Waldorf, D. S., Smith, C. W. & Strauss, A. J. L.: Immunofluorescent studies in pemphigus vulgaris. *Arch Dermatol* 93: 28, 1966.
9. Wright, E. T., Epps, R. L. & Newcomer, V. D.: Fluorescent antibody studies in pemphigus vulgaris. *Arch Dermatol* 93: 562, 1966.

## Palpebral cellulitis

Jytte Roed-Petersen<sup>1</sup> and Hans-Walther Larsen<sup>2</sup>

<sup>1</sup>Department of Dermatology and <sup>2</sup>Department of Ophthalmology, Gentofte Hospital, Hellerup, the <sup>3</sup>Skin Clinic, Rødovre, Denmark

Received August 8, 1977

**Abstract.** Patients with palpebral cellulitis may turn in the first place to a skin clinic. The clinical picture and the course of disease are illustrated here by four case histories. The importance of differentiating between collateral orbital edema, palpebral cellulitis and orbital cellulitis is stressed.

Palpebral cellulitis is an uncommon infection. It can make its entry through an erosion or puncture or via the blood stream, or arise from an inflammation in the skin of the eyelids, the conjunctiva, the orbit, the lacrimal passages, the nasal sinuses, or even the teeth.

Palpebral cellulitis usually occurs unilaterally and is associated with swelling and redness of the involved area. The pre-auricular and mandibular lymph nodes usually become swollen, and some fever may be present. In the early stages the skin is intact, but subsequently erosions, pustules, or even gangrene may develop.

The bulbus and the orbit are usually not involved. The eye can therefore be moved freely, and protrusion is rare.

The condition must be distinguished from allergic contact dermatitis, angioneurotic edema, collateral edema due to ethmoiditis and orbital cellulitis.

Patients with palpebral cellulitis may turn first to a skin clinic, and we therefore think it worthwhile to present some cases and to discuss the differential diagnoses.

#### CASE REPORTS

##### Case 1

Female, 24 years old, developed in the course of about 6 weeks massive swelling and erythema of the eyelids on the left side. Her general condition was well, but she had bouts of low grade fever. On admission, there was massive swelling of the eyelids and the skin looked rather moist (fig. 1). Vision was unaffected, the eye could be moved freely, there was no exophthalmos, but conjunctival chemosis. ESR was 63 mm/l per hour; ear-nose-throat examination was normal. X-ray examination of the nasal sinuses showed a normal picture, but an inflammatory

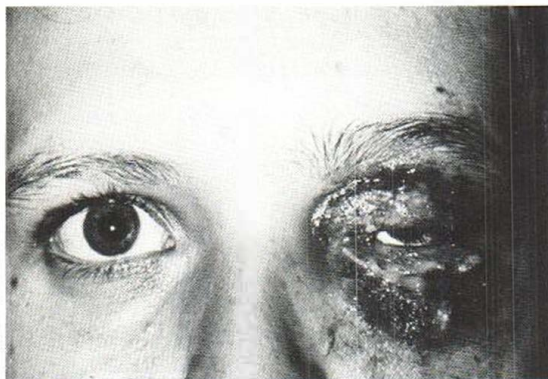

Fig. 1. Case 1. On admission to the hospital. Swelling, erythema and erosions of the eyelids on the left side.

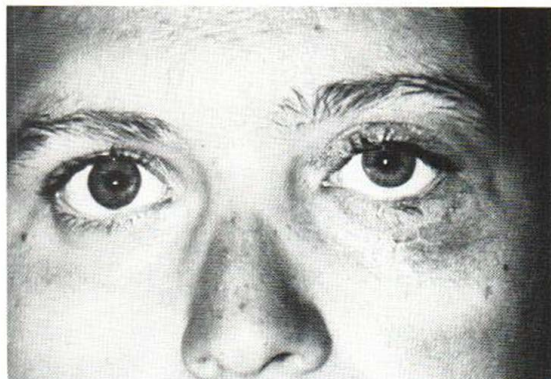

Fig. 2. Case 1. Palpebral cellulitis cured after treatment with tetracycline, prednisone and extraction of an abscessed tooth in the left upper jaw.

process was found around the root of a tooth in the left upper jaw. Biopsies from the left upper and lower lid showed cellular infiltration and abscess formation, but no signs of malignancy or granulomata. During antibiotic treatment, cultures for bacteria and fungi proved negative.

As the disease progressed in spite of treatment with different antibiotics it was decided to institute treatment with tetracycline 250 mg three times a day and prednisone 30 mg a day decreasing to 10 mg a day. On this treatment she showed a gradual improvement during the next 4 months. At that time she agreed to extraction of the abscessed tooth, whereafter the condition improved rapidly and she was cured within a month (Fig. 2).

#### Case 2

Female, 43 years old. She appeared as an emergency case in the skin clinic with the diagnosis: allergy? She presented marked swelling and redness of the eyelids on the left side, slight protrusion of the bulb, and chemosis (Fig. 3). Vision was not affected and her general condition was good. The right eye and the lids were normal. Four weeks previously a tooth with an inflammatory process around the root in the left upper jaw was extracted. At that time she had noticed a slight swelling of the left lower lid. During the next weeks swelling and erythema of the eyelids on the left side gradually increased. She was immediately referred to the Department of Ophthalmology, Rigshospitalet, where ophthalmological examination apart from the above described revealed limitations of ocular movement and slight venous stasis in the fundus of the left eye. Treatment with tetracycline and prednisone for 3 months cured the disease (Fig. 4).

#### Case 3

Female, 28 years old, developed swelling, tenderness, redness, and superficial ulcerations of the lids of the right eye in the course of 24 hours. She had a fever of 39°C. No nasal congestion, no previous trauma. X-ray examination showed normal nasal sinuses and all teeth extracted. Pus from the eyelids revealed haemolytic

streptococci. After 2 weeks' treatment with penicillin the ulcerations healed and the swelling disappeared, but there was still some redness of the skin.

#### Case 4

A 1-year-old girl suffered a slight trauma of the left orbital region with a subsequent small superficial wound. 24 hours later she developed an upper respiratory infection and at the same time swelling, tenderness and redness of the left lower eyelid, purulent infection of the conjunctiva and a fever of 39.7°C. The bulbus was unaffected and there was no exophthalmus. She had a purulent nasal discharge and acute inflammation of the right middle ear, which required paracentesis twice. The infection of the lower lid, conjunctiva, nose and ear disappeared within a week of penicillin treatment.

## DISCUSSION

Allergic contact dermatitis and angioneurotic edema are easily distinguished from palpebral cellulitis. Distinction between palpebral cellulitis, orbital cellulitis and ethmoiditis with collateral orbital edema presents difficulties. Nevertheless, it is of importance because palpebral cellulitis is a rather benign inflammation, whereas the others are serious and sometimes life-threatening.

Orbital cellulitis is usually unilateral, and the cardinal clinical signs are: 1) proptosis 2) swelling of the lids with redness of the skin 3) chemosis 4) limitations of ocular movement. General symptoms—fever, nausea, vomiting and prostration—usually accompany the disease. The histopathological changes are inflammatory edema and cellular infiltration with polymorph nuclear leukocytes. Thrombophlebitic changes may dominate in some cases and abscess formation in others. The infec-

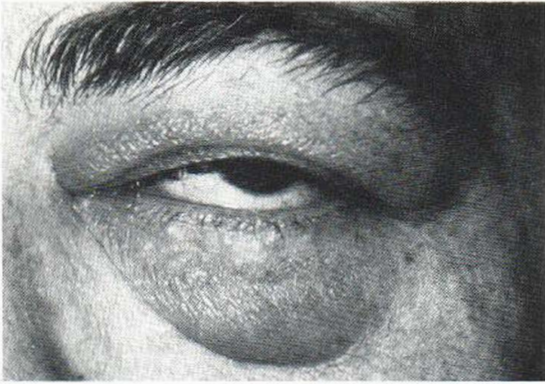


Fig. 3. Case 2. On admission to the hospital. Swelling and erythema of the eyelids on the left side.

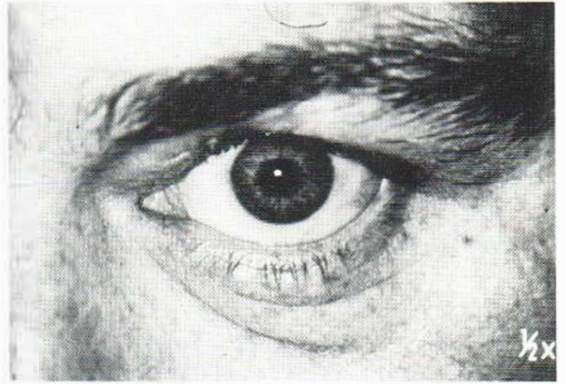

Fig. 4. Case 2. Palpebral cellulitis cured after treatment with tetracycline and prednisone.

tion may reach the brain and cause meningitis, thrombosis in the cavernous sinus, cerebral or subdural abscess (2, 3).

The clinical signs of collateral orbital edema are very much like those of orbital cellulitis (palpebral swelling, chemosis, exophthalmus, impairment of the mobility of the eyeball). The skin may be reddened, but more frequently it is pale and cyanotic. The majority of patients are children and the most frequent cause is an ethmoiditis (2, 3).

Before the era of antibiotics, orbital cellulitis left the affected eye blind in some 20% of those cases that did not have a fatal outcome (2). Even with the use of antibiotics, blindness may occur (1, 5). Gans et al. (4) reviewed 190 patients with acute orbital complications (collateral orbital edema, periostitis and subperiosteal abscess of the orbit, orbital abscess) caused by primary infections in neighbouring organs. Intracranial complications occurred in 15 patients, of whom 2 died, one developed complete bilateral blindness and 2 had permanent damage of the abducens nerve.

Thus, every case of palpebral swelling, not obviously attributable to an allergic reaction (al-

lergic contact dermatitis, edema Quincke) should immediately be referred to an ophthalmologist. Search for and treatment of inflammatory foci also involve otological and dental examination.

#### ACKNOWLEDGEMENTS

Our thanks are due to the Department of Ophthalmology and the Department of Oral Medicine and Oral Surgery, Rigshospitalet, Copenhagen, for permission to publish case 2 which we treated in collaboration.

#### REFERENCES

1. Amies, D. R.: Orbital cellulitis. *Laryngol Otol* 88: 559, 1974.
2. Duke-Elder, S.: *System of Ophthalmology*. XIII, part 1-2. Kimpton, London, 1974
3. Ehlers, H.: Clinical investigations on the inflammatory orbital affections. *Acta Ophthalmol [Suppl] (Kbh)* XII, 1937.
4. Gans, H., Sekula, J. & Wlodyka, J.: Treatment of acute orbital complications. *Otolaryngol* 100:329, 1974.
5. Gold, R. S. & Sager, E.: Pansinitis, orbital cellulitis and blindness as sequela of delayed treatment of dental abscess. *Oral Surg* 32: 40, 1974.