

A LEUKOTACTIC FACTOR IN THE STRATUM CORNEUM OF PUSTULOSIS PALMARIS ET PLANTARIS: A POSSIBLE MECHANISM FOR THE FORMATION OF INTRA-EPIDERMAL STERILE PUSTULES

Hachiro Tagami and Shigeo Ofuji

Department of Dermatology, Hamamatsu University School of Medicine, Hamamatsu and Department of Dermatology Faculty of Medicine, Kyoto University, Kyoto, Japan

Abstract. Previous studies on the chemotactic properties of soluble substances from psoriatic scales demonstrated the presence of complement-derived chemotactic factors (anaphylatoxins) that seem to play a crucial role in the production of typical psoriasiform tissue changes. The crude extract from the stratum corneum of lesions of pustulosis palmaris et plantaris (PPP) was also noted to contain highly chemotactic components for polymorphonuclear leukocytes (PMNs) as compared with a crude callus extract in the present study. The leukotactic factors contained in the major chemotactic fractions isolated by Sephadex G-75 chromatography revealed *in vitro* characteristics and *in vivo* biological activities very similar to those of the leukotactic factor derived from psoriasis scale reported in earlier work, i.e. complement cleavage products (C3a and C5a). On the basis of these findings we have reason to believe that pustule formation in PPP occurs through a mechanism that has a strong resemblance to that in pustular psoriasis. We hypothesize further that similar mechanism may be operative in other dermatoses in which the formation of sterile subcorneal pustules is a characteristic feature.

Key words: Pustulosis palmaris et plantaris; Pustular bacterid; Chemotaxis; Leukotaxis; Complement-derived chemotactic factors; Sterile pustule

The formation of sterile subcorneal pustules characterizes certain dermatoses such as pustular psoriasis, impetigo herpetiformis, pustulosis palmaris et plantaris (PPP), acrodermatitis continua, subcorneal pustular dermatosis, and Reiter's disease. Although there still remain many divergent opinions about their clinical classification, Pinkus & Mehregan (11) classified such dermatoses histologically under the heading of psoriasiform tissue reactions. As regards the mechanisms underlying the suprapapillary migration of leukocytes in psoriasis, we demonstrated the existence of potent leukotactic substances in the scales of psoriasis vulgaris as well as in those of pustular psoriasis (12). Further-

more, it was confirmed that complement cleavage products, C3a and C5a, are contained in them (13, 14). There is indirect evidence that also suggests the involvement of the complement system in the production of subcorneal sterile pustules in some of the above-mentioned pustular dermatoses (6, 8). However, no study has been done to verify the presence of a leukotactic factor in the lesions that could be responsible for the production of sterile pustules in these dermatoses, except for those performed by us in pustular psoriasis (12, 13, 14).

In an attempt to ascertain whether mechanisms similar to those underlying the subcorneal sterile pustule formation in pustular psoriasis also operate in other pustular dermatoses, we have examined the leukotactic properties of the stratum corneum of the lesions of PPP, because PPP is much more common than the other pustular dermatoses. It is often described under the names of pustular bacterid (1) or persistent palmoplantar pustulosis or even pustular psoriasis of the palms and soles (2). Even today much confusion still exists as to proper classification of PPP (5). However, on the basis of HLA typing study, psoriasis vulgaris, pustular psoriasis and PPP seem to be different etiological entities (18).

MATERIALS AND METHODS

Preparations of horny tissue extracts

We selected as cases of PPP only those patients with chronic pustular eruptions on the palms and soles who did not have any typical psoriatic lesions elsewhere. The roofs of pustules and brownish-yellow crusty scales were obtained from the lesions of 5 such patients. Pooled samples of callus and clavus that were utilized as a source of the horny layer extract of non-inflamed palmoplantar skin were collected from healthy volunteers and patients with PPP.

Water-soluble components were extracted in 1/15 M

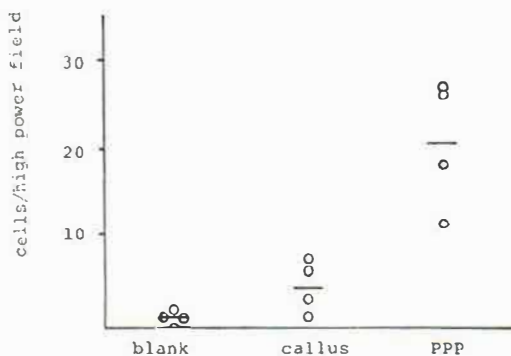


Fig. 1. Comparison of leukotactic activity of a 1:1000 crude callus extract and that of a 1:1000 crude horny tissue extract prepared from the lesions of PPP.

phosphate-buffered saline containing 0.01% streptomycin (PBS; pH 7.2) as described previously (12).

Molecular sieve chromatography

Analysis of material was carried out using Sephadex G-75 as the chromatographic medium in a column 2.5×75 cm. The column was calibrated with bovine serum albumin (BSA), cytochrome *c*, glucagon and vitamin B₁₂. Four ml of the horny tissue extracts was applied to the chromatographic column. The eluting buffer was PBS. Fractions of 6 ml were collected and the content of protein was estimated by measurement of absorption at 280 nm. The treatment of the eluted fractions for each experiment is as described in the Results section.

Chemotactic assay

Guinea pig neutrophils from glycogen-induced peritoneal exudates were used for the determination of leukotactic activity and were suspended at 4×10⁶ cells/ml Hanks' solution with 0.5% BSA. For the assay, modified Boyden chambers were fitted with Millipore filters of 3 μm pore size and were incubated at 37°C in air for 3 hours after loading with 0.5 ml cell suspension in the top compartment and 0.5 ml of the test material in the bottom compartment (12).

After the incubation period, the filters were removed, fixed, stained with hematoxylin, and examined by light microscopy (400× magnification). Chemotactic activity was expressed as the mean number of cells migrating completely through to the bottom surface per high power field.

Intradermal injections

0.05 ml of a chemotactic fraction was injected intradermally with a 27-gauge needle into depilated skin on the backs of guinea pigs. The resultant skin changes were observed until disappearance. At the same time, histological sections were prepared from biopsy specimens obtained from these sites at various intervals after injection, processed routinely and stained with hematoxylin and eosin.

Five animals were pretreated by an intracardiac injection

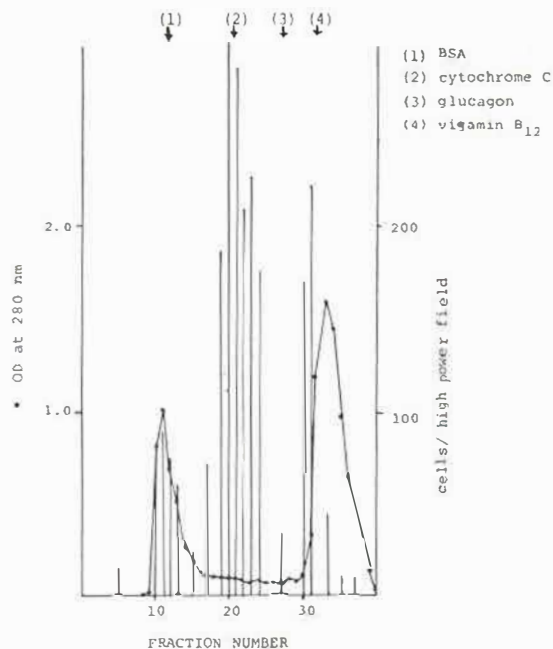


Fig. 2. Characterization of chemotactic activity in crude horny tissue extract from the lesions of PPP by Sephadex G-75. Four ml of a 1:20 extract was applied to a column 2.5×75 cm that had been calibrated with 1) bovine serum albumin (BSA), 2) cytochrome *c* 3) glucagon and 4) vitamin B₁₂. Bars stand for chemotactic activity expressed as the average number of cells per high power field.

of 1 ml of Evans blue (Daiichi Pharmaceutical Co., Tokyo, Japan) and the intensity of the lesion as shown by extravasated Evans blue was estimated for 30 min.

RESULTS

Chemotactic properties of crude horny layer extracts

Fig. 1 shows chemotactic activity of a 1:1000 crude horny tissue extract of the lesions of PPP in comparison with that of a crude extract of callus, the horny layer of non-inflamed plantar skin, prepared in the same way. It is clear that the extract prepared from the lesions of PPP showed definite chemotactic activity for PMNs, whereas the callus extract was only weakly leukotactic.

Molecular sieve chromatography

The Sephadex G-75 elution profile of 1:20 crude horny tissue extracts of the lesions of PPP, either prepared from the roofs of pustules or from the scales, revealed that the bulk of chemotactic activ-

Table I. *Effect of boiling, acidification and alkalinization*

Chemotactic fraction no. 20 (OD₂₈₀: 0.1) was used as a starting material. For acidification and alkalization, it was poured into cellophane bags (Thomas Tubing Vt 351; Arthur H. Thomas Co, Philadelphia, Pa., USA), dialysed for 24 hours against 50 volumes of 0.5 M buffer solutions pH 3 (HCl and NaH₂CO₃) and pH 11 (NaOH and Na₂HCO₃) respectively, and then dialysed against PBS for another 24 hours. Results are of triplicate assays

Materials tested	Cells/high power field
Starting material	133±27
Boiling (100°C for 10 min)	109±17
Acidification (pH 3)	92±4
Alkalization (pH 11)	125±40
Blank	6±1

ity consistently eluted in the same region as the cytochrome *c* marker (Fig. 2). This chemotactic activity resisted heating (56°C for 30 min or even boiling at 100°C for 10 min), acidity (pH 3) and alkalinity (pH 11) but was abolished by digestion with trypsin (Tables I and II).

Since these *in vitro* characteristics are quite similar to those of the leukotactic factor derived from psoriasis scale which was shown to contain complement cleavage products, C3a and C5a (14), an attempt was made to determine whether complement-derived chemotactic factors were also present in the major chemotactic fractions of the scale extract of PPP. Table III shows pronounced inhibition of the chemotactic activity with rabbit antiserum to human C3a and partial reduction with goat antiserum to human C5.

Intradermal injections of the chemotactic fraction no. 20 prepared from Sephadex G-75 chromatography (OD₂₈₀: 0.1) into depilated skin on the backs of 3 guinea pigs produced erythema at the injected sites in 2 hours. The erythematous reaction reached a peak after 6 hours and lasted for 48 hours. Although clinically no immediate wheal formation was noted shortly after injection, 5 animals which were given Evans blue beforehand intracardially began to show blueing of the injected sites after 3 min.

Biopsies showed a mild perivascular PMN infiltration in the skin even 30 min after the injection of the chemotactic fraction. The intensity of the PMN infiltrate increased corresponding to the macroscopic erythematous reaction. Additionally, in the 24-

hour-old skin lesion the epidermis showed scattered eosinophilic stained necrotic cells.

Another strongly leukotactic activity eluted in the same region as the bacterial chemotactic factors prepared from skin flora of the lesions, in low molecular weight fractions around fraction no. 30. Moderate chemotactic activity was observed coincident with the first high molecular weight peak but it was variable between different samples.

DISCUSSION

The typical histopathological feature of PPP consisting of a unilocular intra-epidermal pustule is distinct even from that of pustular psoriasis. However, it is of interest that the basic mechanism of leukocyte migration into the epidermis appears to be similar in both cases. Our findings show that the stratum corneum of the lesions of PPP contains components chemotactic for PMNs, the presence of which would seem to account for the phenomenon of migration and accumulation of PMNs at the subcorneal portion of the epidermis. The Sephadex G-75 chromatography of the PBS extracts of horny tissues from lesions of PPP showed that the bulk of the chemotactic activity was consistently found in the region of the cytochrome *c* marker (molecular weight 12500 Daltons) as noted in the extract of psoriasis scale.

Hugby et al. (6) demonstrated deposition of immunoglobulins and complement fraction C3 in the pustular areas of PPP as well as of pustular psoriasis. Since we have confirmed the presence of C3a and C5a in the leukotactic factor derived from psoriasis scale in our previous studies (13, 14), it is logical to presume that these complement-derived chemotactic factors also exist in the lesions of PPP.

Table II. *Effect of trypsin digestion*

Chemotactic fraction no. 20 (OD₂₈₀: 0.1) was used as a starting material. Trypsin was from Difco Inc., Detroit, Michigan, USA. Results are of duplicate assays

Condition	Cells/high power field
Starting material +37°C, 30 min +56°C, 30 min	98±34
Starting material+trypsin 20 µg +37°C, 30 min+56°C, 30 min	0
PBS+trypsin 20 µg+37°C, 30 min +56°C, 30 min	0

Table III. Effect of anti-C3a and C5 on the chemotactic factor derived from the lesions of *pustulosis palmaris et plantaris*

0.5 ml of starting material, fraction no. 20 (OD_{290} : 0.03) was incubated for 30 min at 37°C with 0.02 ml of rabbit anti-C3a, goat anti-C5 (both containing sodium azide at a concentration of 0.1% and purchased from Behringwerke AG (Marburg, West Germany)), non-immunized rabbit serum or non-immunized goat serum prior to testing for chemotaxis. Results of triplicate assays.

Conditions	Cell/high power field
Starting material +0.02 ml PBS ^a	25±4
Starting material +0.02 ml rabbit anti-C3a	4±1
Starting material +0.02 ml goat anti-C5	15±5
Starting material +0.02 ml preimmune rabbit serum ^a	18±1
Starting material +0.02 ml preimmune goat serum ^a	37±1
PBS +0.02 ml PBS ^a	1

^a PBS or serum with 0.1% sodium azide.

The results of the physico-chemical studies and specific inhibition of the leukotactic activity by antiserum to C3a and C5 confirmed this assumption. Furthermore, intradermal injections of this leukotactic factor into the skin of guinea pigs verified that it possesses the biological activity of anaphylatoxin that produces enhancement of vascular permeability and tissue neutrophilia (17).

Krog & Tönder (8) implicated the involvement of antibodies to stratum corneum in the in vivo formation of antigen-antibody complement complexes in the horny layer of lesions of patients with pustular psoriasis, subcorneal pustular dermatosis and pemphigus foliaceus. They speculated that this complex formation led to the chemotactic trimolecular complex (C567) of the complement system. Although available information indicates that C567 is not the sole complement-derived chemoattractant in vivo (16), their assumption appears to be quite plausible. The demonstration of an autoimmune process taking place in the stratum corneum of psoriatic lesions (3, 4, 7, 9) also strongly suggests the involvement of stratum corneum in the formation of complement derived chemotactic factors.

Recently Lazarus et al. (10) have reported increased amounts of a serine proteinase in the psoriatic epidermis that is effective in activating complement in the absence of an antigen-antibody reaction. There is a possibility that such a mechanism may also play a role in the induction of PMN accumulation in PPP. However, the results of the histopathological study performed by Uehara & Ofuji (15) strongly favor the direct involvement of stratum corneum in the morphogenesis of pustular

lesions. They observed that the pustulation of a vesicle in PPP took place only when direct contact between the blister fluid and stratum corneum occurred.

On the basis of HLA typing study, psoriasis vulgaris, pustular psoriasis and PPP seem to constitute differing etiological entities. However, we have demonstrated an identical leukotactic factor in horny tissues of the lesions of all of these dermatoses. We are therefore inclined to consider that a common mechanism possibly operates in the formation of the above-mentioned pustular dermatoses. At first, non-specific exudative inflammatory changes seem to take place that facilitate the subsequent reaction between serum components and stratum corneum. The complement activation may take place with a resultant release of anaphylatoxins that in turn provoke the enhancement of vascular permeability and migration of leukocytes into the epidermis. Further investigation of the chemotactic properties of the stratum corneum of the lesions of rather rare pustular dermatoses is needed.

ACKNOWLEDGEMENT

We are grateful to Mr Hirosh Nomura and Miss Michiko Hatsuoka for their able technical assistance. This work was supported by grant 267168 from the Ministry of Education, Japan, and a research grant from the Japan Lydia O'Leary Memorial Foundation.

REFERENCES

1. Andrews, G. C. & Machacek, G. G.: Pustular bacterids in the hands and feet. *Arch Dermatol Syphilol* 32: 837, 1935.

2. Barber, H. W.: Acrodermatitis continua vel perstans (dermatitis repens) and psoriasis pustulosa. *Br J Dermatol* 42: 500, 1930.
3. Beutner, E. H., Jablonska, S., Jarzabek-Chorzelska, M., Maciejowska E., Rsesa, G. & Chorzelski, T. P.: Studies in immunodermatology. VI. IF studies of autoantibodies to the stratum corneum and in vivo fixed IgG in stratum corneum of psoriatic scales. *Int Arch Allergy Appl Immunol* 48: 301, 1975.
4. Cormane, R. H., Hunyadi, J. & Hammerlinck, F.: The role of lymphoid cells and polymorphonuclear leukocytes in the pathogenesis of psoriasis. *J Dermatol* 3: 247, 1976.
5. Hellgren, L. & Mobacken, H.: Pustulosis palmaris et plantaris. Prevalence, clinical observations and prognosis. *Acta Dermatovener (Stockholm)* 51: 284, 1971.
6. Hugby, G., Rajka, G. & Larsen, E. E.: Immunofluorescence studies in pustulosis palmoplantaris. *Acta Dermatovener (Stockholm)* 53: 123, 1973.
7. Jablonska, S., Chorzelski, T. P., Jarzabek-Chorzelska, M. & Beutner, E. H.: Studies in immunodermatology. VII. Four-compartment system studies of IgG in stratum corneum and of stratum corneum antigen in biopsies of psoriasis and control dermatoses. *Int Arch Allergy Appl Immunol* 48: 324, 1975.
8. Krogh, H. K. & Tönder, O.: Subcorneal pustular dermatosis. Pathogenetic aspects *Br J Dermatol* 83: 429, 1970.
9. — Antibodies in psoriasis scales. *Scand J Immunol* 2: 45, 1973.
10. Lazarus, G. S., Yost, F. J. & Thomas, C. A.: Polymorphonuclear leucocytes: Possible mechanisms of accumulation in psoriasis. *Science* 198: 1162, 1977.
11. Pinkus, H. & Mehregan, A. H. Psoriasiform tissue reactions. *In* A Guide to Dermatohistopathology, pp. 107. Appleton-Century-Crofts, New York, 1969.
12. Tagami, H. & Ofuji, S.: Leukotactic properties of soluble substances in psoriasis scale. *Br J Dermatol* 95: 1, 1976.
13. Tagami, H. & Ofuji, S.: Demonstration of C3 cleavage product in leukotactic substances of scale extract from pustular psoriasis. *Br J Dermatol* 96: 95, 1977.
14. Tagami, H. & Ofuji, S.: Characterization of a leukotactic factor derived from psoriasis scale. *Br J Dermatol* 97: 509, 1977.
15. Uehara, M. & Ofuji, S.: The morphogenesis of pustulosis palmaris et plantaris. *Arch Dermatol* 109: 518, 1974.
16. Wilkinson, P. C.: Chemotaxis and Inflammation, pp. 121. Churchill Livingstone, Edinburgh, 1974.
17. Wuepper, K. D., Bokish, V. A., Müller-Eberhard, H. J. & Stoughton, R. B.: Cutaneous responses to human C3 anaphylatoxin in man. *Clin Exp Immunol* 11: 13, 1972.
18. Zachariae, H., Petersen, H. O., Nielsen, F. K., & Lamm, L.: HL-A antigens in pustular psoriasis. *Dermatologica* 154: 73, 1977.

Received February 20, 1978

H. Tagami, M.D.
 Department of Dermatology
 Hamamatsu University School of Medicine
 3600 Handa-cho
 Hamamatsu 431-31
 Japan