

## TOPICAL NITROGEN MUSTARD INDUCED CARCINOGENESIS

Paul H. Kravitz and Charles J. McDonald

*Sub-Section of Dermatology, Brown University and Division of Dermatology, Department of Medicine  
Roger Williams General Hospital, Providence, Rhode Island, USA*

**Abstract.** Mycosis fungoides is a rare malignant lymphoma that primarily affects the skin. Lymph node and visceral involvement may follow. The disease is chronic in course, displaying numerous clinical variations. Two cases of mycosis fungoides complicated by the development of cutaneous squamous cell carcinoma will be discussed. One of the two patients developed metastatic squamous cell carcinoma from an initial primary cutaneous lesion. Both patients were treated for long periods with topical nitrogen mustard in addition to systemic therapy. The question of topical nitrogen mustard induction of squamous cell carcinoma is raised.

**Key words:** Mycosis fungoides; Squamous cell carcinoma

In 1956, Sapos (13) first described the remissions of cutaneous lesions in mycosis fungoides following topical application of nitrogen mustard. Haserick, Richardson & Grant (7) followed with a case report. Arundell (1) indicated that patients treated weekly with whole body paintings with the drug may have periods of many months without recurrence of the cutaneous lesions. Sapos (14) again followed with additional cases. Since the original reports, most dermatologists have had occasion to use topical nitrogen mustard in the management of patients with mycosis fungoides. In some patients the effects are comparable to or better than those observed using other forms of therapy. Van Scott & Winters (15) has described several presumptive cures using topical nitrogen mustard in patients with the disease in its early stage.

Is the response in mycosis fungoides related to the cytotoxic effect of the agent, is it related to a hypersensitivity reaction in the skin and tumour site, or is the response related to a combination of both? The exact mechanism, whereby cutaneous lymphomatous lesions are caused to resolve after applications of topical nitrogen mustard, remains unknown.

The nitrogen mustards as well as other alkylating

agents are known to induce biochemical reactions which result in abnormal base pairing in deoxyribonucleic acid (DNA), ring cleavage of purine bases, and depurination with resultant DNA chain scission. Although the overall effect is interference, with mitosis and cell division, theoretically, depurination and chain scission, both of which are compatible with continued growth and cell division rather than cell death, are associated with cell modifications that can result in mutagenicity and carcinogenicity. We are therefore reporting two cases in which the question of topical nitrogen mustard induction of squamous cell carcinoma is raised.

### CASE REPORTS

The first patient is a 64-year-old white female with generalized, eczematous, plaque-type and ulcerative mycosis fungoides for nearly 20 years who developed multiple squamous cell carcinoma of both cheeks and anterior chest in 1975. Over the years she had been treated with numerous therapeutic regimens including electron beam and systemic chemotherapeutic agents including azaribine, cytoxan, methotrexate, bleomycin, and adriamycin. In 1972 dinitrochlorobenzene (DNCB) sensitization using 2 mg/ml under occlusion was attempted, but without success.

Since 1968, except for those periods, in which she was receiving systemic agents in experimental protocols, topical nitrogen mustard was used continuously. She applied topical nitrogen mustard (10 mg of powder diluted in 20 ml of water and 20 ml of propylene glycol) to her entire body, including her face, for an 8-hour period, once daily.

In November 1975, she developed a superficially invasive squamous cell carcinoma of anterior chest and an invasive squamous cell carcinoma of her cheeks. Clinical evidence of cutaneous solar damage was not evident at these sites. The biopsy of the chest lesion (Fig. 1) showed parakeratosis, irregular acanthosis, considerable dysplasia of epidermal cells, sometimes with central keratinization and increased mitoses in the dermis. There was a heavy inflammatory cell infiltrate in the superficial dermis consisting of polymorphonuclear leukocytes, plasma

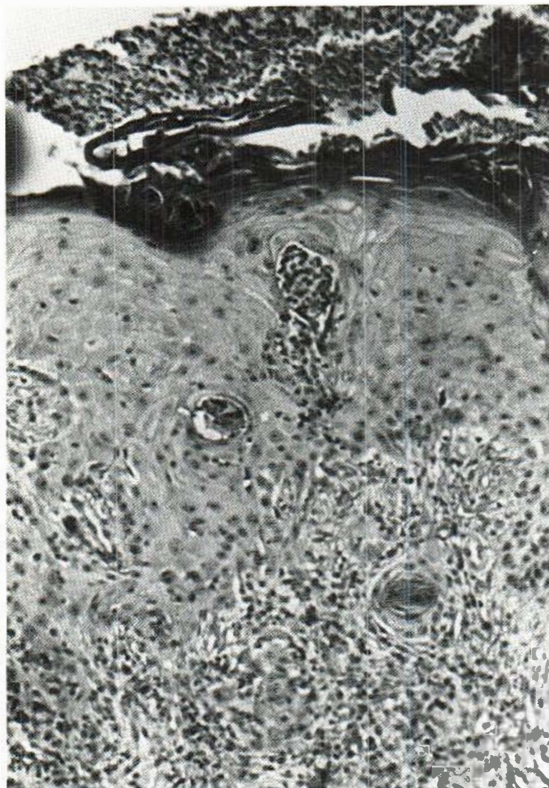


Fig. 1. Biopsy of chest lesion showing parakeratosis, irregular acanthosis, considerable dysplasia of epidermal cells, sometimes with central keratinization and increased mitoses in the dermis (Patient no. 1).

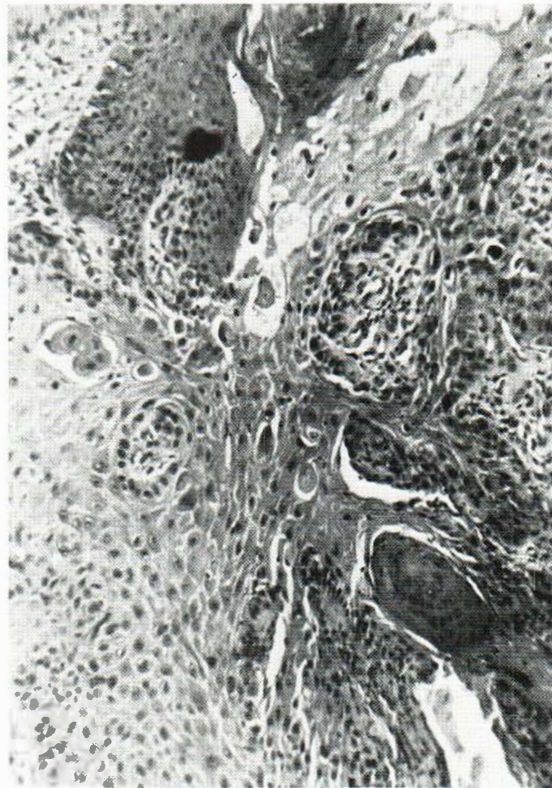


Fig. 2. Biopsy of right cheek lesion showing hyperkeratosis and marked epidermal hyperplasia with severe dysplastic changes. There is abnormal differentiation of epidermal cells, single cell keratinization and considerable pleomorphism of epithelial cells with many giant cell forms. Most changes were intra-epidermal with one area suggestive of microinvasion (Patient no. 1).

cells, lymphocytes, and histocytes. The biopsy of the right cheek lesion (Fig. 2) showed hyperkeratosis and marked epidermal hyperplasia with severe dysplastic changes. There was abnormal differentiation of epidermal cells, single cell keratinization and considerable pleomorphism of epithelial cells with many giant cell forms. Most changes were intra-epidermal with one area suggestive of microinvasion. She was treated with cryosurgery of the cheek lesion and electrodesiccation and curettage of the chest lesion. She continued to use topical nitrogen mustard over these areas. On admission to the hospital in March, 1976 because of an exacerbation of her mycosis fungoides, clinical evidence of new squamous cell carcinomas on both cheeks became evident. Biopsy of the left cheek lesion revealed a well-differentiated squamous cell carcinoma penetrating into the reticular dermis. During the next 2 months a large subcutaneous mass developed in the patient's left thigh and biopsy showed tumour stage mycosis fungoides. Shortly thereafter and before systemic therapy could be initiated, the patient died of an acute pulmonary embolus.

The second patient is an 82-year-old white male who has had mycosis fungoides for over 40 years. A biopsy of the skin taken some time prior to 1940 was compatible

with a diagnosis of poikiloderma vasculare atrophicans. In 1963, he developed generalized scaling and hyperpigmented patches. Subsequently, plaque, nodular and tumour-like lesions developed on his entire body including the face. In 1969 biopsies of multiple cutaneous lesions were consistent with mycosis fungoides.

Shortly thereafter, treatment with azaribine was initiated but severe neurotoxicity required that this form of therapy be discontinued. Moderate dose intravenous methotrexate and leucovorin rescue resulted in 80% clearing of all lesions. No further systemic therapy was used. In 1971, new tumours and plaques appeared. Total body application of topical nitrogen mustard was begun (10 mg of powder diluted in 20 ml of water and 20 ml of propylene glycol). During the next 3 years, daily topical nitrogen mustard painting kept him relatively free of active lesions.

In November 1974, a 2 cm ulceration was noted on the left lateral lower leg. This was surrounded by papules and nodules. There was never any history of chronic leg ulcers or arsenic ingestion. Biopsy revealed infiltrating squamous cell carcinoma (Fig. 3). The tumour was well-differentiat-

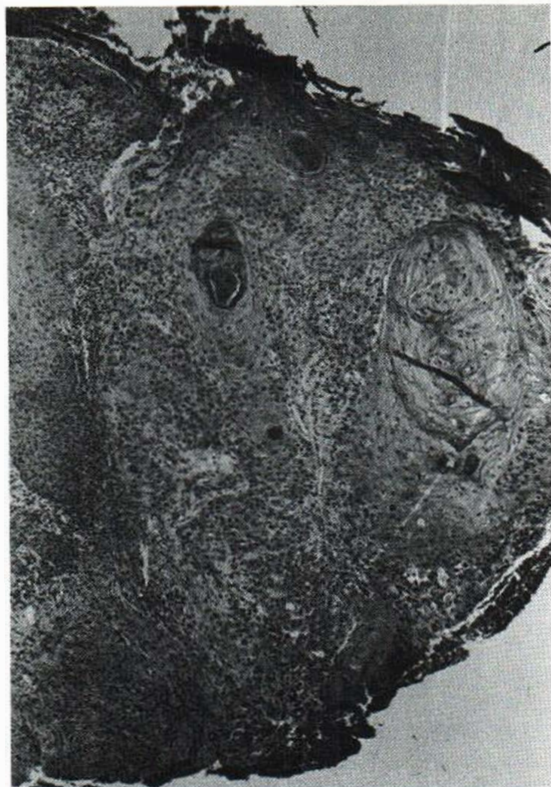

Fig. 3. Biopsy of left lower leg revealing infiltrating squamous cell carcinoma. The tumour is well differentiated, showing keratinization and horn pearl formation extending well into the dermis (Patient no. 2).

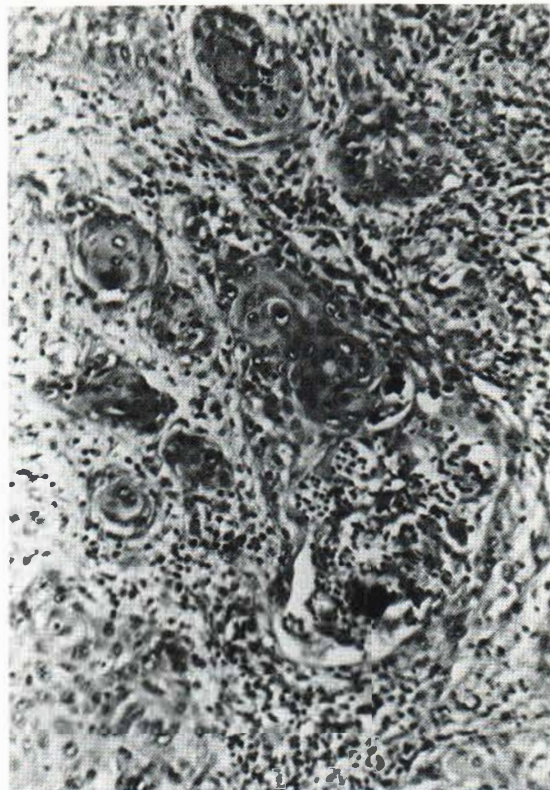


Fig. 4. Lymph node biopsy showing metastatic squamous cell carcinoma disrupting lymph node architecture (Patient no. 2).

ed, showing considerable keratinization and horn pearl formation and extending well into the dermis. Radiation therapy was used to treat this area. He received 6000 rads at 240 kV in divided doses to an 8×12 cm field. Topical nitrogen mustard application continued during this time but not to the healing tumour site. In April 1975, biopsy revealed recurrence of tumour at the margin of the treated site. In July 1975, a cluster of several, hard, 1 cm in diameter, violaceous nodules was seen on the left medial thigh. Infiltrating squamous cell carcinoma was seen after biopsy. Approximately 8 weeks later, hard inguinal nodules were detected. After hospitalization, excisional biopsy revealed metastatic squamous cell carcinoma (Fig. 4). Non-invasive diagnostic studies including chest X-ray, liver function studies, and renal studies failed to reveal tumour involvement. The patient refused additional diagnostic studies or further surgery. Radiation treatments to the left groin and thigh were used. Topical nitrogen mustard was continued to the left leg and the rest of the body except in areas previously involved with squamous cell carcinoma. Subsequently, recurrent tumour developed at the original tumour site and left proximal thigh. In June 1976, biopsy of a nodule on the upper back revealed another primary squamous cell carcinoma. Skin

testing of the patient at this time showed no reaction to purified protein derivative (PPD), streptokinase, streptodornase, trichophyton, and histoplasmin. Baseline skin tests prior to the use of chemotherapy had not been done.

## DISCUSSION

In the two patients described above, we strongly believe that long-term application of topical nitrogen mustard to their skin rendered both patients susceptible to developing multiple squamous cell carcinomas. The continuous use of nitrogen mustard may be the most significant contributing factor in each patient's disease. One patient experienced metastasis of a generally non-metastasizing tumour. The previous or cumulative effects of having had systemic chemotherapy in both patients cannot be discounted.

Though the exact mechanism of resolution of cutaneous lymphoma by topical mechlorethamine is

not known, the biochemical actions of nitrogen mustards may result in therapeutic as well as oncogenic potential. The group of nitrogen mustards used in chemotherapy include mechlorethamine (topical and systemic), cyclophosphamide, uracil mustard, melphalan, and chlorambucil. Nitrogen mustards act on cells at any stage of the cell cycle. The primary target is DNA, thereby interfering with cell growth, mitotic activity, differentiation, and function. Specifically, alkylating agents form covalent linkages (alkylation) with phosphate, amino, sulfhydryl, hydroxyl, carboxyl, and imidazole groups within the cell nucleus. The key biological compound alkylated is the purine base guanine; less extensive alkylation may occur with adenine or cytosine. Bifunctional cross-linking that occurs with mechlorethamine is accomplished by the two reactive arms of the molecule reacting at two points on the double helix of DNA. Bifunctional cross-linking is usually cytotoxic toward cells. Monoalkylation also occurs and, being less cytotoxic for the cell and therefore a lesser threat to cell survival, can be mutagenic or carcinogenic (17).

Secondary neoplastic lesions have been reported in patients who were treated with alkylating agents and other systemic cytotoxics (8). Reimer (11) has showed a 21 to 36 fold increase in developing acute leukemia after treating patients with ovarian cancer with alkylating agents. With increased survival, increased risk was found. A considerable body of evidence from animal experimentation has demonstrated the carcinogenic potential of alkylating agents (12). Nitrogen mustards have caused teratogenic effects in rodents (4).

Most alkylating agents are cytotoxic to rapidly proliferating tissues in which a large proportion of cells are in division. They also have damaging effects on tissues with normally low mitotic indices; for example, liver, kidney, and mature lymphocytes. The skin that is treated with topical mustard may represent a tissue where carcinogenic potential is reached. In susceptible skin cells, ribonucleic acid (RNA) and protein synthesis with cytoplasmic growth and differentiation might continue, while binding of DNA results in arrested nuclear cell division (5). If the injury to DNA is not repaired but does not result in early cell death, the defect may eventually be replicated and passed on to the progeny of the cell. Price (10) treated six patients with mycosis fungoides with topical mechlorethamine for 2 years. Biopsy of normal skin in a non-sun

exposed area failed to show signs of cellular atypia or loss of polarity. No histological changes suggestive of early malignancy were noted. Perhaps a longer later latency period was needed? Perhaps these patients were not immunologically susceptible to second malignancy during the time of his study.

Because of similarities in biological effects of nitrogen mustards and X-irradiation, mustards have been referred to as "radiomimetic agents." Administration of alkylating agents in toxic doses and X-irradiation can result in 1) delayed cell deaths occurring 3 to 7 days after exposure to LD<sub>50</sub> doses; 2) involution in the size of lymph nodes, thymus, and spleen; 3) progressive reduction in the number of leukocytes and platelets in the peripheral blood and aplasia of the bone marrow; 4) ulcerations and sloughing of the intestinal mucosa; 5) decrease in antibody production and an increased susceptibility to infection; and 6) decrease in spermatogenesis (5).

Alkylating agents have been shown to have therapeutic immunosuppressive capability. This is clearly seen in renal transplant patients who receive cyclophosphamide to decrease host versus graft reactions. Interestingly, these same patients experience an increased occurrence of neoplasia. If host defense systems are inadequate, a transformed or alkylated cell may develop into a malignant cell (6). The chronic topical application of nitrogen mustard in both patients may have been immunosuppressive, as seen by failure to respond to DNCB and common skin antigens. It may be speculation to assume that patients with mycosis fungoides who usually have normal immunologic reactivity (2) may become immunosuppressed with topical mustard therapy and therefore are prone to cutaneous cancer. But the anergy of our second patient, with two distinct primary squamous cell tumours, may be suggestive of some defect in cell-mediated immunity.

The span of years between the onset of the use of the topical nitrogen mustard and the clinical appearance of the squamous cell carcinoma probably represents in these 2 patients the latency period needed for this agent to produce carcinogenesis. A comprehensive review of carcinogenicity of anti-neoplastic agents in man by Sieber & Adamson (12) has indicated a latent period of 4 years from the initiation of drug exposure to occurrence of second malignancies. Patients with mycosis fungoides may have second malignancies, but cutaneous squamous

cell carcinoma has not been reported at any increased frequency (3). An increased frequency of actinic keratoses and squamous cell carcinoma was observed by Vonderheid (16), perhaps by topical nitrogen mustard augmenting precarcinogenic solar damage in patients with mycosis fungoides. Our patients did not have clinical evidence of chronic solar damage at the sites of their tumours. Cutaneous squamous cell carcinoma is generally a locally aggressive tumour. The virulence of our second patient's squamous cell carcinoma as seen by its multiple recurrences and rapid metastases to his inguinal nodes may be related to external stimuli or to impaired delayed hypersensitivity. Could the combined effects of the topical mustard and local X-ray therapy for squamous cell carcinoma have produced a more virulent tumour based on the mutagenic potential of each? This question is difficult to answer. Usually metastases of cutaneous squamous cell carcinoma are related to antecedent lesions, i.e., burns, scars, chronic ulcers, arsenic and X-ray therapy (9).

A comparison of treated patients with matched controls is obviously needed to ascertain the risk of using topical nitrogen mustard. Adjuvant use of this drug in patients who have regressed tumour or disease may also need to be reconsidered. Complications of topical nitrogen mustard heretofore described deal mostly with allergic contact dermatitis. The development of multiple cutaneous malignancies with a strongly aggressive potential is now presented as a possible complication of the topical use of nitrogen mustard treatment of mycosis fungoides. Further reports are needed to solidify this association.

## REFERENCES

1. Arundell, F. D.: Topical use of nitrogen mustard in recurrent cases. *California Medicine* 109: 458, 1968.
2. Blaylock, W. K.: Normal immunologic reactivity in patients with the lymphoma mycosis fungoides. *Cancer* 19: 233, 1966.
3. Brehmer-Andersson, E.: Mycosis fungoides. *Acta Dermatovener (Stockholm) Suppl.* 75, 56: 1976.
4. DiPaolo, J. A.: Teratogenic agents: Mammalian test systems and chemicals. *Ann NY Acad Sci* 163: 801, 1969.
5. Dowling, M. D., Krakoff, I. H. & Karnofsky, D. A.: Mechanism of action of anti-cancer drugs. *In* *Chemotherapy of cancer* (ed. by W. H. Cole), p. 1. Lea & Febiger, Philadelphia, 1970.
6. Harris, C. C.: Immunosuppressive anti-cancer drugs in man: their oncogenic potential. *Radiology* 114: 163, 1975.
7. Haserick, J. R., Richardson, J. H. & Grant, O. J.: Remissions of lesions in mycosis fungoides following topical application of nitrogen mustard. *Cleve Clin Q* 26: 144, 1959.
8. Kyle, R., Pierre, R. V. & Bayrd, E. D.: Multiple myeloma and acute myelomonocytic leukemia. *N Engl J Med* 283: 1121, 1970.
9. Lund, H. Z.: How often does squamous cell carcinoma of the skin metastasize? *Arch Dermatol* 92: 635, 1965.
10. Price, N.: Topical mechlorethamine. *Arch Dermatol* 118: 1387, 1977.
11. Reimer, R.: Acute leukemia after alkylating agent therapy of ovarian cancer. *N Engl J Med* 297: 177, 1977.
12. Sieber, S. M. & Adamson, R. H.: Toxicity of antineoplastic agents in man: chromosomal aberrations are: fertility effects, congenital malformations and carcinogenic potential. *Adv Cancer Res* 22: 57, 1975.
13. Sipos, K.: A mustarnitrogen hely: alkalmazasa nehany gorbetegsegben. *Borgyoegyasza Es Venerologiai Szemle* 32: 198, 1956.
14. Sipos, K.: Painting treatment of nitrogen mustard in mycosis fungoides. *Dermatologica* 130: 3, 1965.
15. Van Scott, E. J. & Winters, P. C.: Responses of mycosis fungoides to intensive external treatment with nitrogen mustard. *Arch Dermatol* 102: 507, 1976.
16. Vonderheid, E. C., Van Scott, E. J., Johnson, W. C., Grekin, D. A. & Asbell, S. O.: Topical chemotherapy and immunotherapy of mycosis fungoides. *Arch Dermatol* 113: 459, 1977.
17. Wheeler, G. P.: Alkylating agents. *In* *Cancer medicine* (ed. by J. F. Holland & E. Frei, III), p. 791. Lea & Febiger, Philadelphia, 1973.

Received January 30, 1978

Charles J. McDonald, M.D.  
Department of Medicine  
Roger Williams General Hospital  
825 Chalkstone Avenue  
Providence, RI 02908, USA