

manage less severe cases of acne vulgaris of the face by topical means exclusively. Other erythromycin derivatives and other antibiotics should be examined. We see erythromycin base as a prototype illustrating the feasibility of external antibiotic treatment. Many of the good and excellent clinical results seen with topically applied erythromycin occurred in patients who could be characterized as being "fair complexioned". Also, in general, it has been our experience that the more severe cases of acne vulgaris frequently require full dosages of oral antibiotics.

It is perhaps fortunate that erythromycin should be the first topically effective antibiotic in acne. Erythromycin ointment has been on the market for many years. Adverse reactions are exceedingly uncommon. Erythromycin is not an irritant, a contact allergen, or a photosensitizer. So far, after many tests, we have not encountered resistant strains of *P. acnes*; this parallels our experience with oral tetracyclines. The usual objections to topical antibiotics which are also used systemically do not apply to acne vulgaris. *P. acnes* is not a pathogen in the usual sense and it would be of little consequence if it did acquire resistance. Pathogens such as *S. aureus* and b-hemolytic streptococci are not part of the acne microflora (7) nor of the normal cutaneous biotica (6). Hence, there is little danger of inducing resistant strains of virulent bacteria. Unlike *P. acnes*, the resident aerobes do become resistant to erythromycin but it is difficult to imagine what harm can come from that.

In contrast to oral use of erythromycin, we have obtained no proof that topical application substantially decreases the *P. acnes* population (4, 9). The FFA, however, undergo a significant reduction (1, 4) and follicular porphyrin fluorescence also disappears (4). These are signs which unmistakably indicate an effect on the metabolic activities of *P. acnes*.

REFERENCES

1. Fulton, J. E. & Pablo, G.: Topical antibacterial therapy for acne. *Arch Dermatol* 110: 83-86, 1974.
2. Kaidbey, K., Kligman, A. M. & Yoshida, H.: Effects of intensive application of retinoic acid on human skin. *B J Dermatol* 92: 693-701, 1975.
3. Kligman, A. M.: An overview of acne. *J Invest Dermatol* 62: 268-287, 1974.
4. Kligman, A. M., Mills, O. H., McGinley, K. J. & Leyden, J. J.: Acne therapy with tretinoin in combination with antibiotics. *Acta Dermatovener (Stockholm)*, Suppl. 74: 111-115, 1975. International Symposium, Flims, January, 1975.
5. Kligman, A. M., Wheatley, V. R. & Mills, O. H.: Comedogenicity of human sebum. *Arch Dermatol* 102: 267-275, 1970.
6. Marples, M.: *The Ecology of Human Skin*. Charles C. Thomas, Springfield, Ill., 1965.
7. Marples, R. R., Leyden, J. J., Stewart, R., Mills, O. H. & Kligman, A. M.: The skin microflora in acne vulgaris. *J Invest Dermatol* 62: 37-41, 1974.
8. Mills, O. H. & Kligman, A. M.: Assay of comedolytic agents in the rabbit ear. *In* *Animal Models in Dermatology* (ed. H. Maibach), pp. 176-183. Churchill Livingstone, New York, 1975.
9. Mills, O. H., Kligman, A. M. & Stewart, R.: The clinical effectiveness of topical erythromycin in acne vulgaris. *Cutis* 15: 93-96, 1975.
10. Mills, O. H., Marples R. R. & Kligman, A. M.: Acne vulgaris. Oral therapy with tetracycline and topical vitamin A acid. *Arch Dermatol* 106: 200-203, 1972.

Pediculosis Capitis Treated with Quassia Tincture

O. Jensen, A. Otkjær Nielsen and P. Bjerregaard

Department of Dermatology, Municipal Hospital, Copenhagen, Denmark

Received May 20, 1978

Abstract. 454 patients were treated with quassia tincture for head lice. At examination one week later only three patients had hatched lice. There was firm evidence that these patients had been reinfested. The treatment procedure was acceptable both to patients and to staff and no side-effects were observed. As resistance to clophenothane has appeared, alternative cures are needed. This study confirms earlier reports on the effectiveness of quassia tincture, which seems to be a useful alternative to clophenothane. At present the recommended treatment is two applications with an interval of one week.

Key words: Pediculosis capitis; Quassia tincture

During recent years we have noticed increasing numbers of patients with head lice and, among these, a large proportion who were not cured by our then current treatment with preparations of clophenothane.

Therefore a change of treatment was considered. We decided to resume the treatment with quassia tincture, which was introduced for the treatment of

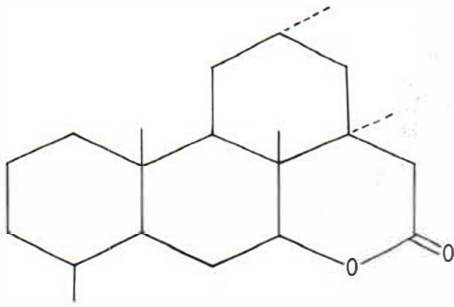


Fig. 1. Basic structure of quassinoids.

head lice in Denmark in 1932 and was at that time found effective (2, 4). *Quassia*, earlier used in bitters and in enemas against threadworm (5), seems to be atoxic and easily decomposed.

CHEMISTRY

Quassia is a member of the plant family *Simaroubaceae*, which is widespread in the tropics. Only two species are of interest in this connection, viz. *Quassia amara* known as Surinam quassia, and *Picrasma exelsa* known as Jamaica quassia. Surinam quassia is a small bush and Jamaica quassia a tall tree.

Quassia wood contains a bitter principle earlier known as "quassin". Further chemical analysis has shown that "quassin" consists of several substances, known as quassinoids (9) (Fig. 1). It is not yet known which of the quassinoids are of importance for killing lice.

A tincture is prepared by maceration in 86% alcohol for 5 days (8). Filtration gives a yellow liquid with a bitter taste and a peculiar, not unpleasant smell. It has the following composition: *Lignum quassia minutum concisum* 150 g, *Spiritus concentratus* 1000 g. In this study the tincture was prepared mainly from Jamaica quassia.

MATERIAL AND METHODS

During the period 1.8.75–31.12.76 a total of 454 patients were treated and followed up after treatment.

The patients either visited the clinic of their own accord or were referred by general practitioners, schools or kindergartens. All were examined twice, at the initial consultation by doctor and nurse and, one week later, by the nurse only. Patients who did not return for the second examination were excluded from this study. Indication for treatment was the presence of live lice or eggs, but persons in close contact with patients infested with live lice or eggs were also treated.

The treatment was carried out at the clinic and consisted in a thorough rinsing of the hair with the tincture, followed by air drying. Hair wash was not allowed during the first 18 hours. One week later a careful inspection for live lice was made, and thereafter all patients received a second treatment.

RESULTS

Table 1 shows the distribution of the patients according to the findings at the initial examination. Among the 160 patients with live lice there were a considerable number (65=41%) who had been treated with clophenothane preparations within the previous 14 days. Most of these patients had treated themselves at home.

At the follow-up examination one week later, only 3 patients had living lice, and for all 3 patients we have good reason to assume that they had been reinfested.

No side-effects were noted by the patients and apart from slight discomfort from the alcoholic vapour, the staff had no complaints and prefer quassia tincture to the alcoholic solutions of clophenothane previously used. Blood alcohol levels were measured in 2 members of the staff after 12 and 16 applications in one morning. In neither case could alcohol be demonstrated in the blood.

DISCUSSION

The high proportion of patients not cured by clophenothane confirms our initial observation. These failures may be due to inaccurate treatment or reinfections, but the great number of failures may also support the assumption that clophenothane-resistant lice have been present.

The first report on head lice resistant to clophenothane appeared in 1971 (7), and, in 1974, resistance was found among head lice in Denmark (10).

A number of alternative treatments exist. Gamma benzene hexachloride, an organochlorine insecticide similar to clophenothane, has proved effective (12), but resistance has already been reported (7), and probably a cross-resistance to any other organochlorine insecticide exists (7).

Table 1. Distribution of the patients according to the findings at the initial examination

	Number	%
Patients with live lice	160	35
Patients with eggs but without live lice	191	42
Close contacts without live lice or eggs	103	23
Total	454	100

Malathion, which is ovicidal, in contrast to the organochlorine insecticides, is effective (1, 6). In England it is considered the treatment of choice in areas where clophenothane resistance has developed (3). However, failures of even this treatment have already been reported (11).

Our investigation have confirmed that quassia tincture is highly effective against head lice. It is cosmetically acceptable and no side effects were seen.

REFERENCES

1. Coates, K. G.: Control of head infestation in schoolchildren. *Community Med* 126: 148, 1971.
2. Jørgensen, G.: Behandling af pediculi capitis med Quassiaspiritus. *Nord Hyg T* 16: 128, 1935.
3. Leading article: A nit or not a nit? *Br Med J* i: 354, 1975.
4. Magnussen, J. D. & Debes Joensen, H.: Bekæmpelse af pediculosis capitis. *Farm Tid* 17: 217, 1944.
5. Martindale: Quassia. In *The Extra Pharmacopoeia*, 26th ed., pp. 327-328. The Pharmaceutical Press, London, 1972.
6. Maunder, J. W.: Use of Malathion in the treatment of lousy children. *Community Med* 126: 145, 1971.
7. Maunder, J. W.: Resistance to organochlorine insecticides in head lice, and trials using alternative compounds. *Med Off* 125: 27, 1971.
8. *Pharmacopoeia danica* 3: 435, 1948.
9. Polonsky, J.: Quassinoid Bitter Principles. *Fortschr Chem Org Naturst* 30: 101, 1973.
10. Rosdahl, N.: Klofenotanresistente hovedlus. *Ugeskr Laeger* 137: 1931, 1975.
11. Silverton, N.: Malathion-resistant pediculosis capitis. *Br Med J* iii: 646, 1972.
12. Wexler, L.: Simplified treatment of pediculosis. *Clin Med* 75: 28, 1968.