

## ULTRASTRUCTURAL CHANGES IN DISSEMINATED CONNECTIVE TISSUE NEVI

Lis Danielsen, Takasi Kobayasi and Grete Krag Jacobsen

*From the Department of Dermatology, University of Copenhagen, Rigshospital,  
and the Dermatology Clinic, Municipal Hospital, Copenhagen, Denmark*

**Abstract:** Skin biopsy specimens from a patient with disseminated connective tissue nevi and from her son and daughter who had no such clinical alterations were studied with the electron microscope. The nevi showed increased amounts of thick elastic fibres, which were composed of irregularly arranged, often finger-like, subunits surrounded by a thready material. Both structures probably represent malformed components of elastic fibres, the thready material representing malformed elastic fibrils. Many of the collagen fibrils showed increased diameters and twistings, which alterations are believed to represent malformation of collagen. The fibroblasts showed changes which might be related to a pathological protein synthesis. Examination of biopsy specimens from normal skin of the patient and from the skin of her son and daughter failed to demonstrate similar alterations. The present case is regarded as an entity, distinct from dermatofibrosis lenticularis disseminata and from shagreen patch.

**Key words:** Nevus; Connective tissue; Elastic tissue; Collagen; Fibroblast

Connective tissue nevi are developmental dysplasias of connective tissue with variable histologic changes, particularly as regards the amounts of collagen and elastic tissues (17, 19, 23). A number of clinical variants characterized by papules, plaques or nodules have been described (19, 23). They are skin-coloured, yellow, or ivory. While most connective tissue nevi are regarded as isolated non-genetically determined developmental defects, one type—named shagreen patch—appears as a feature of tuberous sclerosis (14), which is determined by an autosomal dominant gene (11). Dermatofibrosis lenticularis disseminata of Buschke and Ollendorff has been regarded as a type of connective tissue nevus (18, 20, 22). This condition occurs together with developmental defects in the bones, named osteopoikilosis, and is inherited more or less as a

strictly dominant trait (1, 4). As long as the pathogenesis of the above-mentioned conditions is not clarified, it is impossible to define their mutual relationship.

To further elucidate the pathogenesis, we conducted electron microscopy studies on skin biopsy specimens from a patient with disseminated connective tissue nevi as well as skin biopsy specimens from her son and daughter.

### MATERIAL

The patient was a 59-year-old woman with an eruption on the skin of the trunk and extremities of diffusely spread 2-5 mm large, soft, yellow papules, present over many years (Fig. 1). The papules were seen in both extensor and flexor areas of the extremities. Similar cases had not been observed in the family. Over many years the patient had developed an alcohol-conditioned cirrhosis of the liver and for 4 months she had been treated for myxedema. X-ray examinations of the extremities failed to disclose osteopoikilosis. Ophthalmoscopy showed no angioid streaks. Beside a questionable increase in the  $\alpha$ -1-lipoprotein, no changes were observed in the lipid contents of her serum. Biopsies were taken from lesions in the skin of the right forearm and of the upper area of the right femur as well as from normal skin of the upper area of the right femur.

The patient's 37-year-old son and 32-year-old daughter were also examined. Neither of these showed lesions in the skin similar to those of their mother. The son had several 2 mm large depigmented macules in the upper area of the back, the daughter similar lesions in the sacral region. Biopsies were taken from these lesions as well as from normal skin in both subjects. X-ray examination of the son failed to disclose osteopoikilosis.

### METHODS

**Light microscopy.** Paraffin sections were stained with hematoxylin and eosin, with the method of van Gieson, Weigert's staining for detection of elastic fibres. Foot's

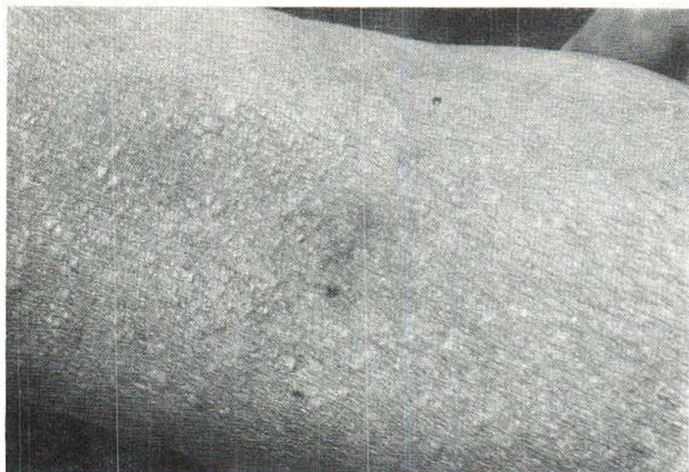

Fig. 1. Numerous round and oval 2-5 mm papules in the skin of the antecubital area.

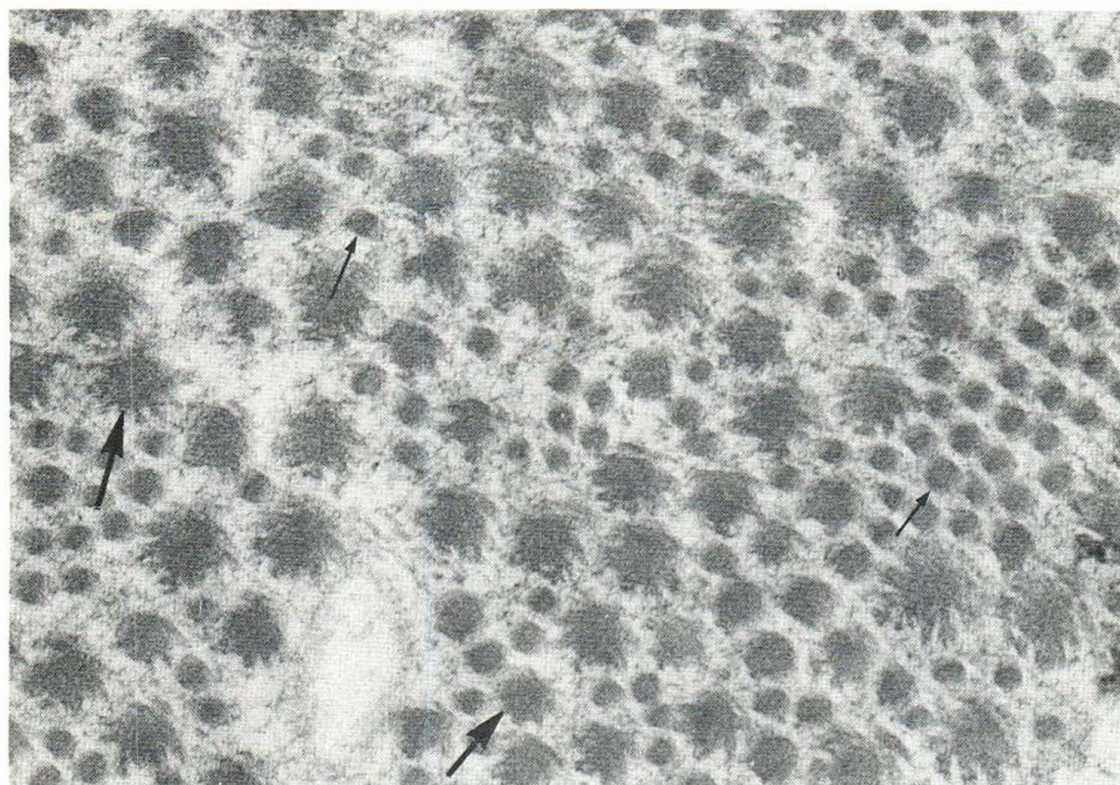


Fig. 2. Twisted collagen fibrils with increased diameters (thick arrows) are mixed with normal collagen fibrils (thin arrows), both in cross-section. Electron micrograph of skin lesion from right forearm.  $\times 60\,000$ .

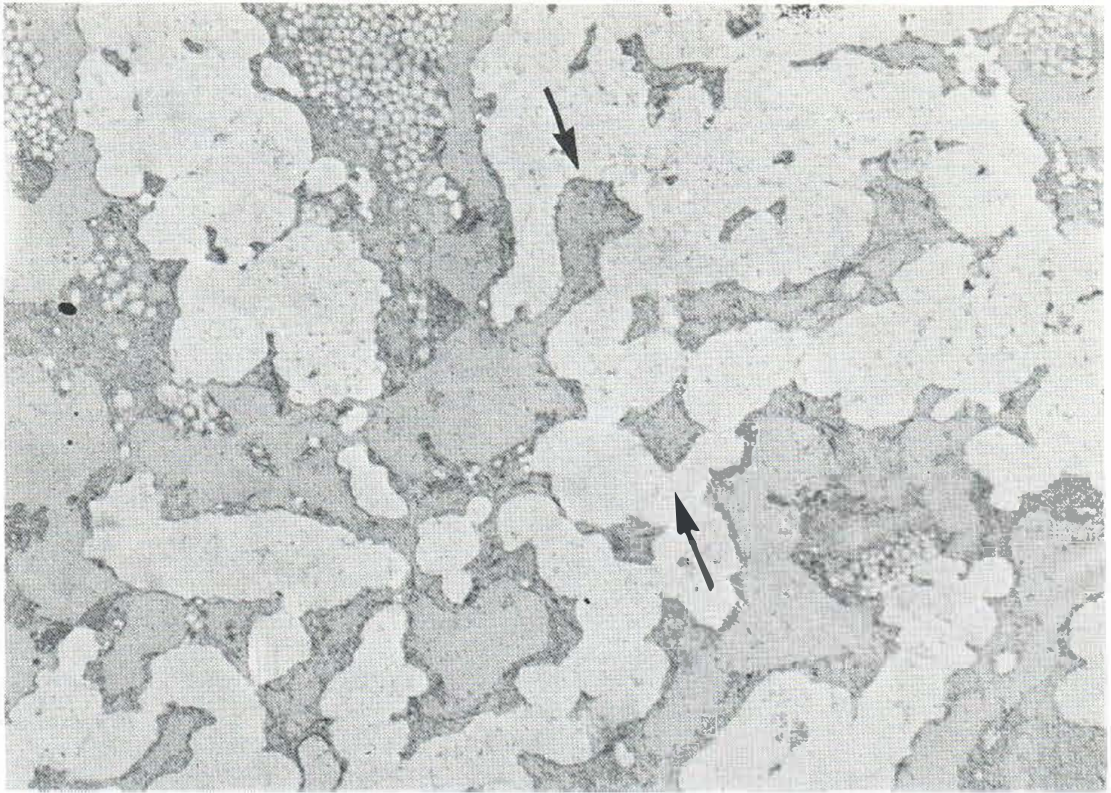


Fig. 3. Elastic tissue, appearing as finger-like, irregularly arranged ramifications, occasionally at right angles to each other (arrows). No elastic fibrils surround the indi-

vidual units. Electron micrograph of skin lesion from upper right femur.  $\times 12\,000$ .

silver impregnation for reticulin fibres and Alizarin red S for calcium. Frozen sections were stained with Oil Red O for lipids.

**Electron microscopy.** The specimens were fixed in glutaraldehyde 6% in Veronal acetate buffer (pH 7.2) with 7.5% sucrose, and then osmicated. After stepwise dehydration in increasing concentrations of ethanol, the specimens were embedded in epoxy resin, and ultrathin sections were cut with an LKB ultramicrotome. The sections were stained according to a combined technique using uranyl acetate and lead citrate. A Siemens electron microscope (Elmiskop IA) was operated at 80 kV with double condensers for the study.

## RESULTS

**Light microscopy.** A yellow papule from the upper right femur showed an increased amount of elastic fibres in all layers of the dermis except for a thin band immediately below the epidermis. Many of the elastic and some of the collagen fibres were thickened. Abnormal amounts of reticulin fibres

were not observed in the affected area, which showed a blurred border toward the surrounding tissue. Neither were deposits of calcium or lipids seen. Apart from the changes mentioned above, a yellow papule from the right forearm showed actinic elastosis in the subepidermal zone.

**Electron microscopy.** The yellow papules contained increased amounts of thick elastic fibres, which were often surrounded by a thready material. Many of the collagen fibrils were thickened and twisted (6) (Fig. 2), and some of the fibroblasts were abnormal.

The elastic fibres in considerable areas were partly split into subunits, which appeared as finger-like, irregularly arranged ramifications, often at right angles to each other (Fig. 3). These subunits presented a regularly round cut-surface, only occasionally surrounded by a few normal elastic fibrils. Within the remaining areas of the fibres, thin electron-dense lines were observed. In contrast to

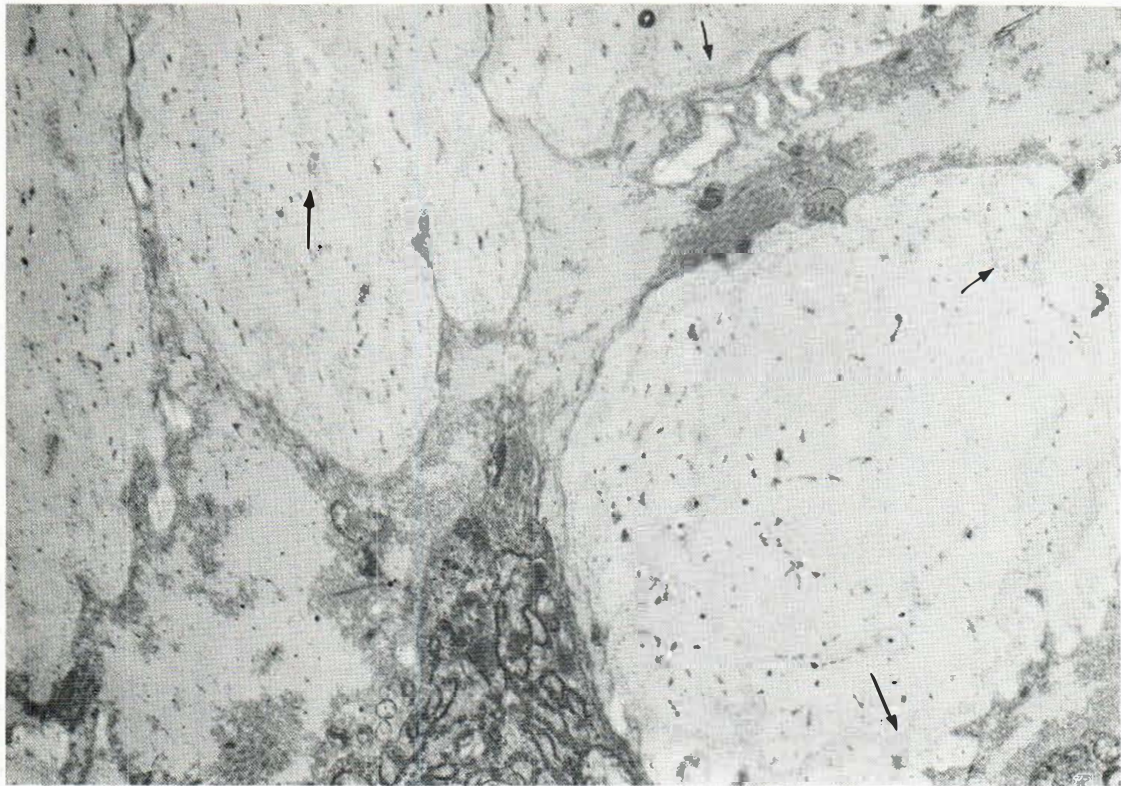


Fig. 4. Elastic fibres presenting dotted and curved lines (arrows) in the matrix. No elastic fibrils surround the

fibres. Electron micrograph of skin lesion from right forearm.  $\times 12000$ .

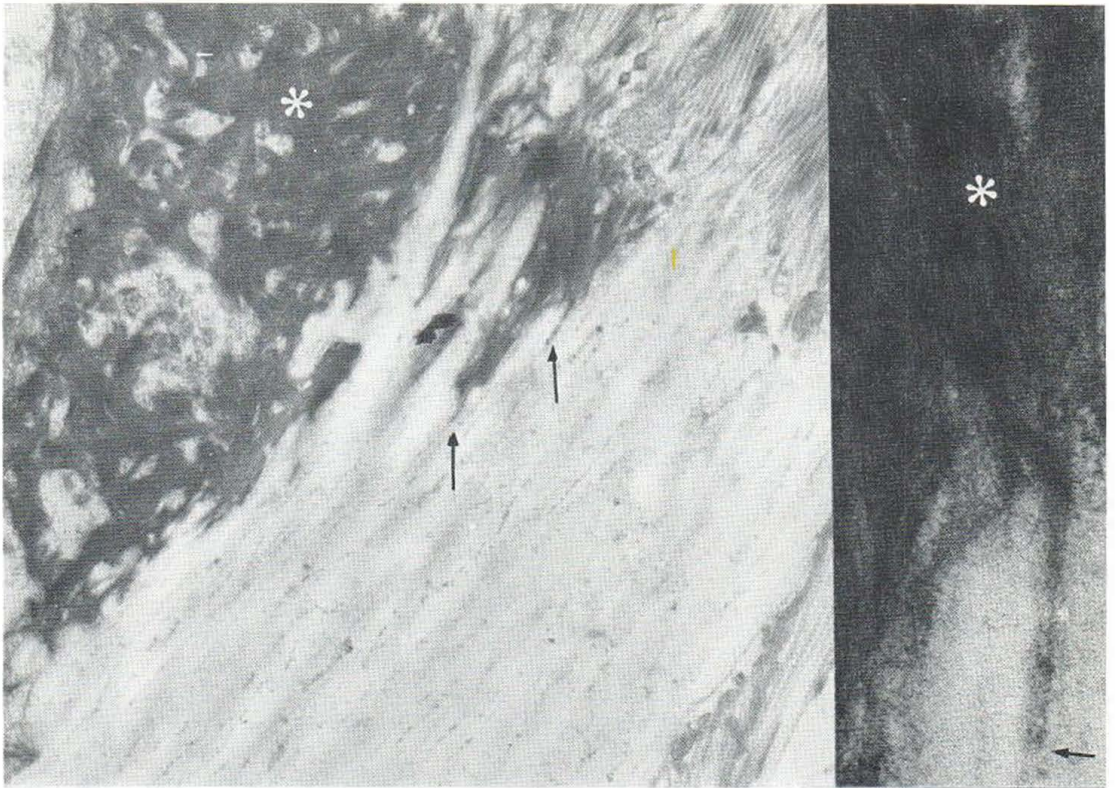
the long straight and parallel lines seen inside normal elastic fibres (7, 13), some of these lines were dotted, curved and irregularly arranged (Fig. 4).

Large amounts of thready material were seen surrounding some of the elastic fibres in both lesions studied (Fig. 5). The material were located in close apposition to the above-mentioned subunits of the elastic fibres and often also inside the matrix of the fibres (Fig. 5). In the last-mentioned areas, the threads were arranged in narrow bands related to the thin lines of matrix. The presence of threads inside the elastic fibres was particularly pronounced in the severely degenerated fibres (8) of the upper, light-exposed corium of the biopsy specimens from the forearm skin (Fig. 6). Slight degeneration was demonstrated in elastic fibres of the unexposed corium, the degeneration appearing less prominent than would be expected according to the age of the patient (8). In the extra-fibrillar spaces, the threads were arranged in bundles of varying width and length, crossing each other at different angles (Fig.

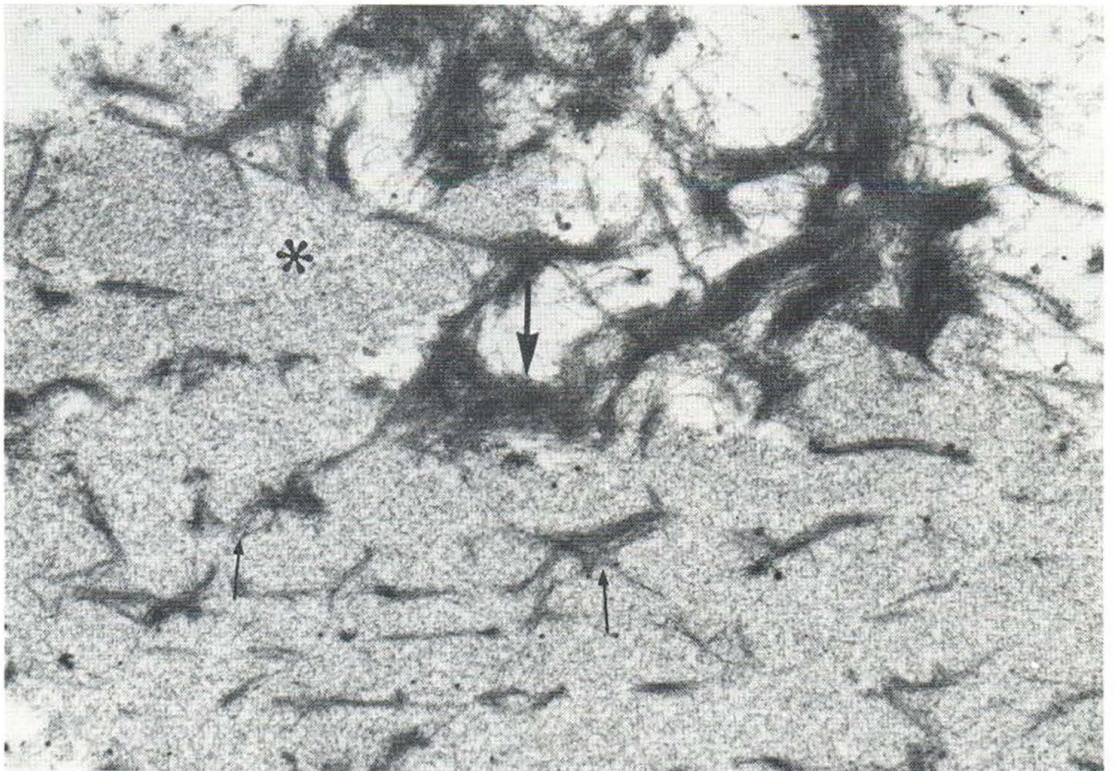
7). Occasionally, they formed sheaf-like bundles reminiscent of those of fibrin, only without their banding. In some areas they were mixed with elastic fibrils, showing direct continuity with these (Fig. 8). Occasionally, thready material surrounded collagen fibrils. The fibroblasts showed numerous invaginations of the nuclear membrane by cytoplasmic processes, 'nuclear pockets' (Fig. 9), and occasional cysts between the laminae of the nuclear envelope. The endoplasmic reticulum of some of

Fig. 5. Large amounts of thready material (asterisks) around and inside an elastic fibre, following the thin lines of matrix (arrows). Electron micrograph of skin lesion from right forearm.  $\times 12000$ . Inset: Area of Fig. 5 at  $\times 60000$ .

Fig. 6. Thready material (thick arrow) around and inside a severely degenerated elastic fibre, following the thin lines of matrix (thin arrows). The granular matrix is indicated by an asterisk. Electron micrograph of upper, light-exposed part of skin lesion from right forearm.  $\times 30000$ .



5.



6.

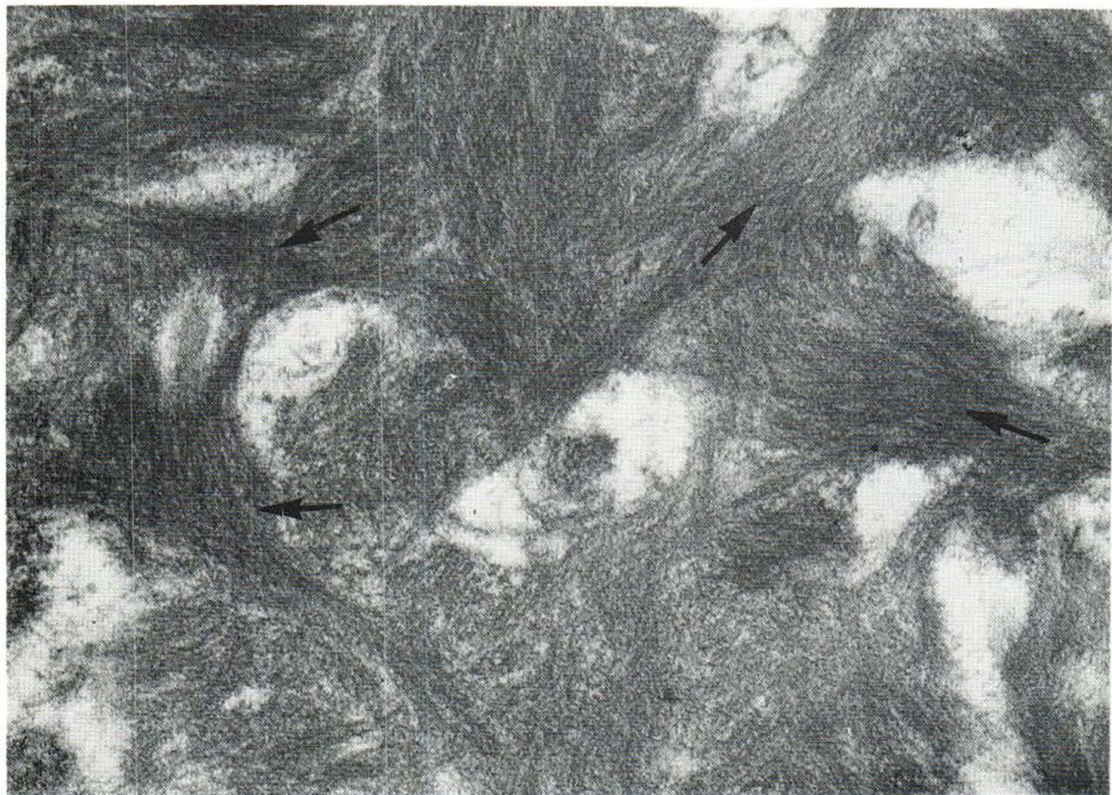

Fig. 7. Bundles of threads crossing each other at different angles. Sheaf-like bundles indicated by arrows. Electron micrograph of skin lesion from right forearm.  $\times 60\,000$ .

the fibroblasts was severely changed, displaying large round lamellar figures (Fig. 10).

The biopsy specimens from normal skin of the patient and all the biopsy specimens from her son and daughter failed to show changes like those described above.

#### DISCUSSION

The changes in the elastic fibres are interpreted as malformations, as the subunits of the fibres were arranged in a pattern not observed in elastic fibres of normal skin. It cannot be excluded with certainty, that the thready material observed around elastic fibres represents fibrin. However, we suggest that the threads represent malformed elastic fibrils, as they were observed in areas known to contain elastic fibrils, i.e. around and within large areas of the elastic fibres and related to the thin lines of fibre matrix (7, 13). Furthermore, they showed a direct

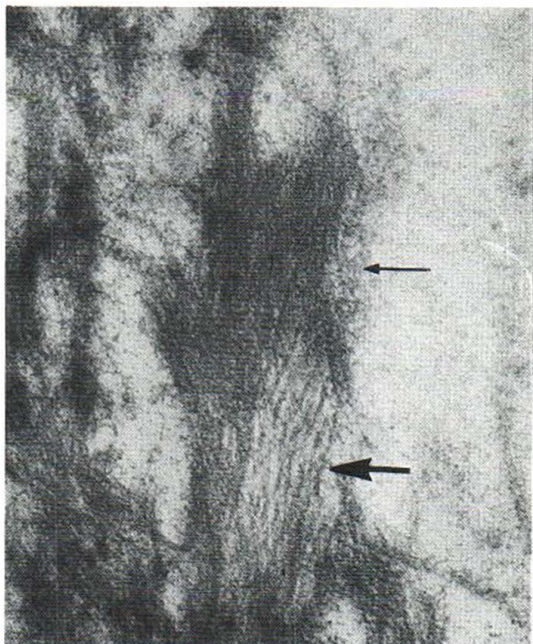


Fig. 8. Thready material (thin arrow) mixed with elastic fibrils (thick arrow). The two structures appear to be interconnected. Electron micrograph of skin lesion from right forearm.  $\times 60\,000$ .

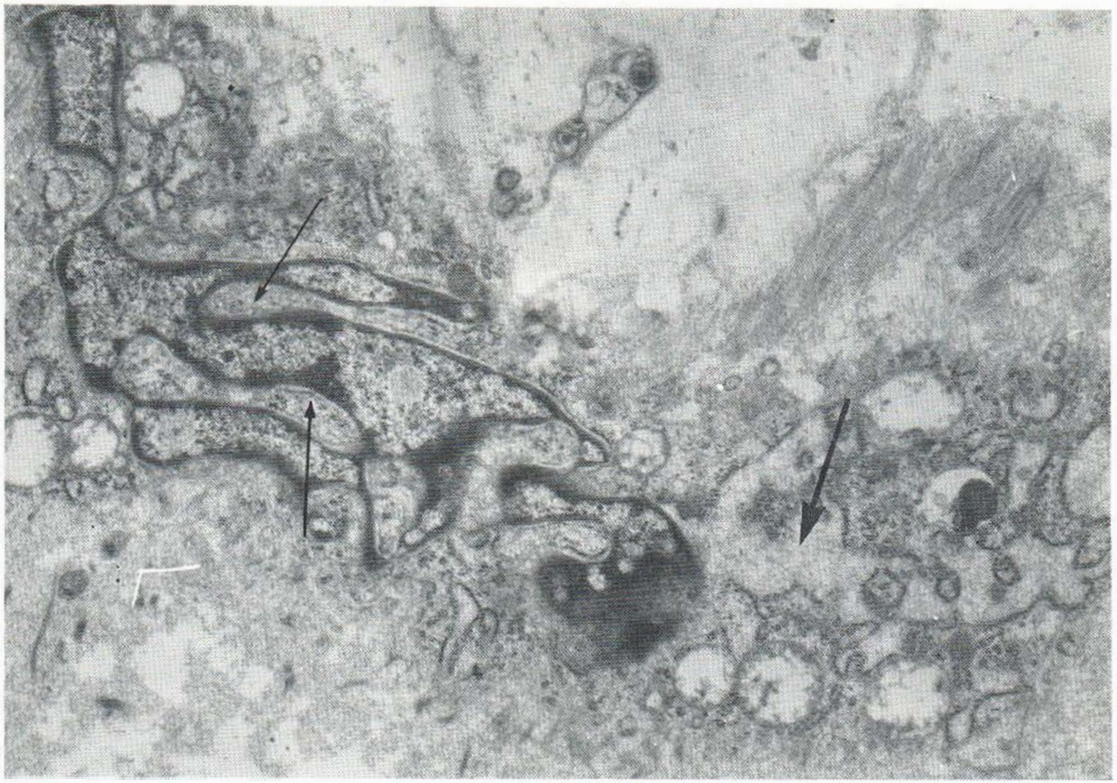


Fig. 9. "Nuclear pockets" (thin arrows) in the periphery of the nucleus of a fibroblast. Cystic endoplasmic reticulum (thick arrow) connected with the nuclear envelope.

Electron micrograph of skin lesion from right forearm.  $\times 15\,000$ .

continuity with elastic fibrils. Large masses of a thready material have also been observed in the genetic diseases pseudoxanthoma elasticum and shagreen patch of the tuberous sclerosis syndrome (6, 9, 10, 14). However, there is evidence that the thready material of those diseases is related to a malformation of collagen, the collagen fibrils appearing split into thin threads, partly with axial periodicity, partly without (9, 10, 14).

The thready material of the present case appeared rather well organized in contrast to the thready material of pseudoxanthoma elasticum and shagreen patch, mainly appearing as compact masses. Only in certain areas did the last-mentioned material show a tendency to circular or band-like arrangements (6, 9, 10, 14). Furthermore, the thready material of the present case appeared more electron dense than the thready material in the other diseases (6, 9, 10, 14). Alterations in the elastic fibres as observed in our case have neither been found in dermatofibrosis lenticularis disseminata

(5) nor in shagreen patch (14). This fact suggests that the present case represents an entity, distinct from the two conditions mentioned. In one case of dermatofibrosis lenticularis disseminata (5) the elastic fibres were hypertrophic and showed granular bands separating longitudinal bands of matrix as seen in degenerated fibres of aged and sun-exposed skin (8). There was only a slight indication of irregularity of the bands of matrix in that case (5).

Many of the collagen fibrils had an increased diameter and twisting, changes which have been related to malformation (9, 10, 14). Experimentally, twisting of normal collagen fibrils can be produced by the influence of collagenase (15) and of citrate buffer (16). However, no thickening of the fibrils was seen in these studies (15, 16). In pseudoxanthoma elasticum (6) and shagreen patch (14) as well as in the present case, twisted collagen fibrils showing considerable thickening were regularly found, thus relating the phenomenon of these cases to a malformation rather than to a degradation. As

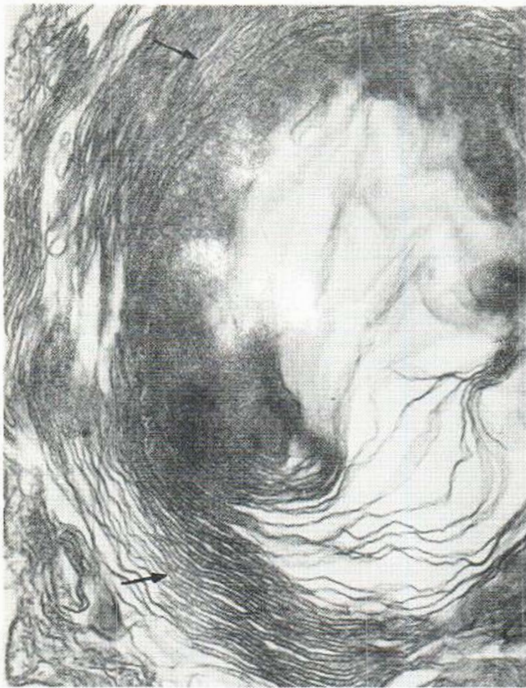


Fig. 10. Severely changed endoplasmic reticulum appearing as a large, round, lamellar figure (arrows) inside a fibroblast. Electron micrograph of skin lesion from upper right femur.  $\times 40000$ .

mentioned above, the presence of large masses of thready material in pseudoxanthoma elasticum and shagreen patch is also suggested to be related to a malformation of collagen. It seems less likely that the threads represent degradation, as none of them showed a regular segmentation, a phenomenon which, according to recent studies (12, 15), appears to be related to extracellular breakdown of collagen. Furthermore, biochemical studies of skin in pseudoxanthoma elasticum have shown evidence of an abnormal synthesis of collagen (2).

The changes in the fibroblasts observed in the present study might be related to a pathological protein synthesis. The presence of "nuclear pockets" in large quantities has been observed in rapidly growing or synthesising cells (3, 21). The phenomenon is believed to be related to enhancement of the nucleolo-cytoplasmic interactions (3). Concentric rings of endoplasmic reticulum similar to those observed in the present study have been noticed inside "nuclear pockets" of leukemic lymphocytes (21).

Clinically, the skin lesions of the present patient

were similar to those of the patient mentioned above who had dermatofibrosis lenticularis disseminata (5). However, osteopoikilosis of bones was not observed in our patient.

The absence of changes in the relatives studied does not support the suggestion of a genetic origin of the disorder.

#### ACKNOWLEDGEMENTS

The authors gratefully acknowledge the valuable technical assistance of Miss Lise Fredebo, Mrs Sidsel Lorenzen, Miss Anne-Marie Hansen and Mr John Winter.

#### REFERENCES

- Berlin, R., Hedensjö, B., Lilja, B. & Linder, L.: Osteopoikilosis—a clinical and genetic study. *Acta Med Scand* 181: 305, 1967.
- Blumenkrantz, N., Danielsen, L. & Asboe-Hansen, G.: Biosynthesis of collagen in pseudoxanthoma elasticum. *Acta Dermatovener (Stockholm)* 53: 429, 1973.
- Burns, E. R., Soloff, B. L., Hanna, C. & Buxton D. F.: Nuclear pockets associated with nucleolus in normal and neoplastic cells. *Cancer Res* 31: 159, 1971.
- Busch, K. F. B.: Familial disseminated osteosclerosis. *Acta Radiol* 18: 693, 1937.
- Danielsen, L., Midtgaard, K. & Christensen, H. E.: Osteopoikilosis associated with dermatofibrosis lenticularis disseminata. *Arch Dermatol* 100: 465, 1969.
- Danielsen, L., Kobayasi, T., Larsen, H.-W., Midtgaard, K. & Christensen, H. E.: Pseudoxanthoma elasticum. A clinico-pathological study. *Acta Dermatovener (Stockholm)* 50: 355, 1970.
- Danielsen, L.: Abnorme elastiske fibre. Degeneration og forkalkning i hud og arterier. *Ugeskr Laeg* 134: 2759, 1972.
- Danielsen, L. & Kobayasi, T.: Degeneration of dermal elastic fibres in relation to age and light-exposure. Preliminary report on electron microscopic studies. *Acta Dermatovener (Stockholm)* 52: 1, 1972.
- Pseudoxanthoma elasticum. An ultrastructural study of scar tissue. *Acta Dermatovener (Stockholm)* 54: 121, 1974.
- Pseudoxanthoma elasticum. An ultrastructural study of oral lesions. *Acta Dermatovener (Stockholm)* 54: 173, 1974.
- Gunther, M. & Penrose, L. S.: The genetics of epiloia. *J Genet* 31: 413, 1935.
- Hentzer B. & Kobayasi, T.: Ultrastructural changes of human skin in organ culture. *J.R.C.S. Med Sci* 3: 211, 1975.
- Kobayasi, T.: Electron microscopy of the elastic fibres and the dermal membrane in normal human skin. *Acta Dermatovener (Stockholm)* 48: 303, 1968.

14. Kobayasi, T., Wolf-Jürgensen, P. & Danielsen, L.: Ultrastructure of shagreen patch. *Acta Dermatovener (Stockholm)* 53: 275, 1973.
15. Kobayasi, T. & Hentzer, B.: Influence of collagenase, elastase and dithioerythriol on dermal fibres. Presented at the 2nd European Meeting on Electron Microscopy applied to Cutaneous Pathology, Milan, January 1975.
16. Kobayasi, T.: Personal observations.
17. Lewandowsky, F.: Über einen eigentümlichen Naevus der Brustgegend. *Arch Derm Syph* 131: 90, 1921.
18. Raque, C. J. & Wood, M. G.: Connective-tissue nevus. Dermatofibrosis lenticularis disseminata with osteopoikilosis. *Arch Dermatol* 102: 390, 1970.
19. Rocha, G. & Winkelmann, R. K.: Connective tissue nevus. *Arch Dermatol* 85: 722, 1962.
20. Schorr, W. F., Opitz, J. M. & Reyes, C. N.: The connective tissue nevus-osteopoikilosis syndrome. *Arch Dermatol* 106: 208, 1972.
21. Schrek, R.: Ultrastructure of blood lymphocytes from chronic lymphocytic and lymphosarcoma cell leukemia. *J Nat Cancer Inst* 48: 51, 1972.
22. Smith, C. A. D. & Waisman, M.: Connective tissue nevi: familial occurrence and association with osteopoikilosis. *Arch Dermatol* 81: 249, 1960.
23. Woringe, F. & Laugier, P.: Dysembryomes élastiques rares. *Bull Soc Fr Derm Syph* 68: 544, 1961.

*Received January 15, 1976*

L. Danielsen, M.D.  
Dermatology Clinic  
Municipal Hospital  
Ø. Farimagsgade 5  
DK-1399 Copenhagen  
Denmark

#### *Addendum*

In April 1976 abnormal elastic fibre subunits similar to those observed in the present case were demonstrated in juvenile elastoma by M. Ledoux-Corbusier at the 3rd European Meeting on Electron Microscopy applied to Cutaneous Pathology in Brussels.