

NODULES ON THE LEGS

A Clinical, Histological and Immunohistological Study of 82 Patients Representing Different Types of Nodular Panniculitis

K. M. Niemi, L. Förström, M. Hannuksela,
K. K. Mustakallio and O. P. Salo

From the Department of Dermatology, University Central Hospital, Helsinki, Finland

Abstract. Eighty-two cases of nodular panniculitis of the legs were examined clinically, histologically and immunohistologically. Clinically the cases could be divided into four groups: typical erythema nodosum (EN_{ty}) (35 cases), erythema nodosum migrans (EN_{mi}) (11 cases), erythema induratum (EI) (11 cases) and the remaining 25 cases not consistent with the others as "non-definite panniculitis" (NDP). The main histological categories were septal panniculitis and lobular panniculitis, the former including erythema nodosum, both typical and migrans, the latter EI and NDP. Lobular panniculitis was divided into three subgroups in which the most prominent histological features were epithelioid cell granuloma, vasculitis and palisading granuloma, respectively. Immunoglobulins in the vessel walls were found in 5 of the 46 cases of erythema nodosum, in 19 of the 36 EI and NDP cases and, in the histological groups in 4 of the 43 cases of septal panniculitis and in 19 of the 35 cases of lobular panniculitis, respectively. Fibrin was found in the walls of the papillary capillaries and deep dermal vessels in the majority of cases of lobular panniculitis. In EI and NDP the follow-up time was 40 months, on average. Twenty-two patients were treated with antituberculous drugs, 15 became symptomless, as did 5 of the 12 patients who were not treated at all.

Key words: Lobular panniculitis; Septal panniculitis; Immunofluorescence; Antituberculous drugs

During the last two decades numerous attempts to make a reasonable classification of the diseases manifesting themselves as nodules on the legs have been made, but none of the classifications has been generally accepted. Typical erythema nodosum (EN_{ty}) can be easily distinguished from other conditions. Erythema nodosum migrans (EN_{mi}) is considered a clinical variant of erythema nodosum (4, 17) although some authors include this entity in more or less ill-defined larger groups of nodular diseases (13, 26, 36). Erythema induratum (EI) is

still seen in countries with relatively high tuberculosis morbidity, but there is some doubt as to its existence as a condition per se (27, 29). On the other hand, nodular vasculitis, Weber-Christian's panniculitis, Rothman-Makai's syndrome, cutaneous periarteritis nodosa and Whitfield's erythema induratum are not such clear-cut clinical entities as the conditions mentioned above.

The introduction of the immunohistological method as a diagnostic aid has shed more light on the pathogenesis of these diseases. Yet, the results—and especially their interpretation—have been very confusing, not least owing to the different clinical and histological diagnostic criteria used.

This study is an effort to compare both histological and immunohistological findings with clinical data in some nodular diseases of the legs.

PATIENTS AND METHODS

Eighty-two patients with nodules on the legs were included in this study over a period of 12 months in 1970-1971. Patients with inadequate biopsy specimens were excluded from the series.

The patients were grouped into four categories on the basis of the clinical picture and the course of the disease:

1. In typical erythema nodosum (EN_{ty}) the nodes are red, non-ulcerating and warm; they are most often situated on the frontal surfaces of the lower legs but quite often also on the calves and arms. Their diameter varies from 1 to 15 cm. They subside without any visible scarring. Fever and malaise, as well as aches and pain in the joints often precede or accompany the nodes.

2. In erythema nodosum migrans (EN_{mi}) the nodules are unilateral or asymmetrical, and they persist somewhat longer than those in EN_{ty}. The nodes may migrate or at least change their form and size during the illness. The general symptoms are few (2).

Table I. *Quantitative Mantoux test in clinical subgroups*

Mantoux positive to	Diagnosis			
	ENty <i>n</i>	ENmi <i>n</i>	EI <i>n</i>	NDP <i>n</i>
0.01 TU	2	0	3	4
0.1	7	2	5	12
1	8	4	2	9
10	9	4	1	0
100	5	0	0	0
Negat. to 100	3	0	0	0
Not done	1	1	0	0
Total	35	11	11	25

3. Erythema induratum (EI) manifests itself as chronic, cold, ulcerating nodules predominantly on the calves. They heal with scarring.

4. The group of non-definite panniculitis (NDP) included patients with large, diffuse, chronic indurations without ulceration and healing with scars or pits. This group also included patients with small nodules with or without ulcerations. These could be found on various locations on the extremities. All the star-like ulcers with the healing stage known as atrophie blanche were excluded from the entire series.

Biopsies were taken under local anaesthesia. One-half of the specimen was processed in paraffin, cut, and stained with hematoxylin-eosin, resorcin and methyl-green-pyronin. The other half was snap-frozen for immunohistological studies, which were performed as described previously (32). 22 patients provided more than one biopsy. Altogether 123 specimens were cut throughout and reviewed. The histological classification is based on the studies of Montgomery et al. (22), Röckl & Thies (31), Eberhartinger (11) and Reed & Clark (28).

In addition to clinical and routine laboratory examinations and chest X-ray, the following roentgenological and laboratory examinations were carried out in the vast majority of the cases of EI and NDP: lymphography of the legs, quantitative Mantoux test, fasting blood sugar or glucose tolerance test, and in 29 patients serological

autoimmune studies consisting of the Waaler-Rose, latex, antinuclear antibody, direct Coombs and cryoprecipitation tests.

RESULTS

I. Clinical Study

Thirty-five patients were classified as having ENty, 8 of whom were men and 27 women. The age distribution of the patients was 33.3 years (range 25–72). Sarcoidosis was encountered in 6 cases, streptococcal infection in 7, yersiniosis in 10, and pregnancy in one case. In 11 cases, the possible cause underlying the EN remained obscure. The mean duration of the disease was approximately 2 weeks.

Eleven patients had ENmi which in one case was accompanied by pregnancy and streptococcal infection but in the remaining 10 cases there was no evident trigger for the eruption. The mean age of the patients was 36.9 years. There was only one man in this group. Duration of the disease was at least one month.

In the EI group, there were 2 men and 9 women. The age range was 25 to 67 years and the mean age 49.6 years. Their medical history revealed tuberculosis in the family in 5 cases, and 2 patients had suffered from active tuberculosis earlier, but one youth. In 4 patients lymphography revealed only non-specific changes in retroperitoneal lymph nodes, and in 4 cases it was normal. Changes compatible with tuberculosis were seen in 2 cases. In other roentgenological and laboratory examinations, no signs of active tuberculosis were found. The mean duration of the disease was 11 years (4 months to 26 years).

Patients not fulfilling the criteria of the three groups mentioned above were classified clinically

Table II. *The histopathological features in clinical subgroups*

Clinical diagnosis	Septal		Lobular				
	Septal	Septal with vasculitis	Epithelioid cell granuloma, necrosis	Vasculitis (necrosis, epithelioid cell granuloma)	Palisading granuloma	Unclassified	Non-definite mild panniculitis
ENty	27	5	–	–	–	–	3
ENmi	10	–	–	–	–	–	1
EI	–	–	6	1	4	–	–
NDP	1	–	6	5	6	7	–
Total	38	5	12	6	10	7	4

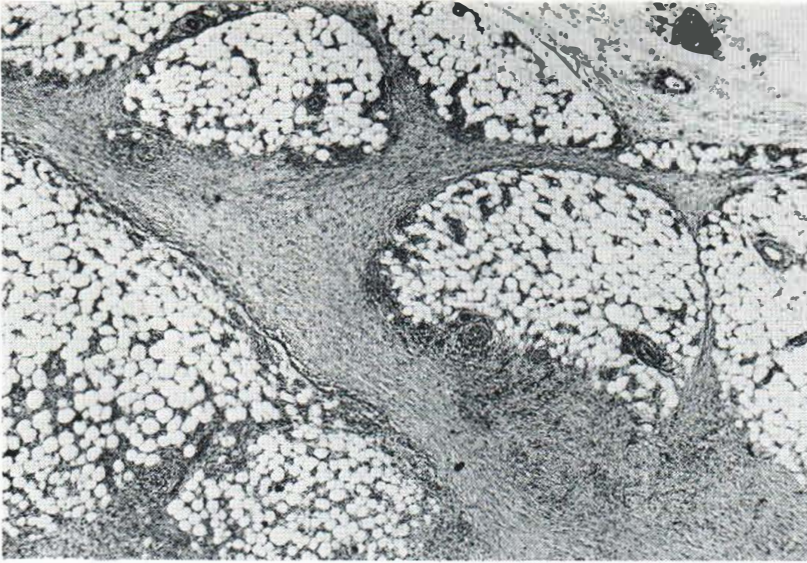

Fig. 1. Septal panniculitis of a clinically typical erythema nodosum (HE, 2.5×12.5).

as non-definite panniculitis. One patient had Weber-Christian's panniculitis with periodical feverish attacks. Only one of the patients was a man. Lymphography was carried out in 19 cases. The result was normal in 13 cases, and only non-specific changes were seen in 6 cases. Five patients had suffered from active tuberculosis earlier, but one of the cases revealed current, active tuberculosis. Six patients had a family history of tuberculosis. The mean duration of the disease was 4.5 years (2 months to 25 years). The age range of the pa-

tients was 25 to 72 years and the mean age was 47.9 years. In EI and NDP groups the direct Coombs test and the Waaler-Rose test were negative in all cases, but latex fixation test and the cryoprecipitation test were positive in 2 cases. Antinuclear antibody of immunoglobulin IgM class (1:20 – 1:50) was found in 5 cases and of the IgG class (1:50 – 1:100) in 2 of the 29 patients examined. One patient with SLE had high antinuclear antibody titres and was included in the clinical group of NDP. Three patients had elevated blood

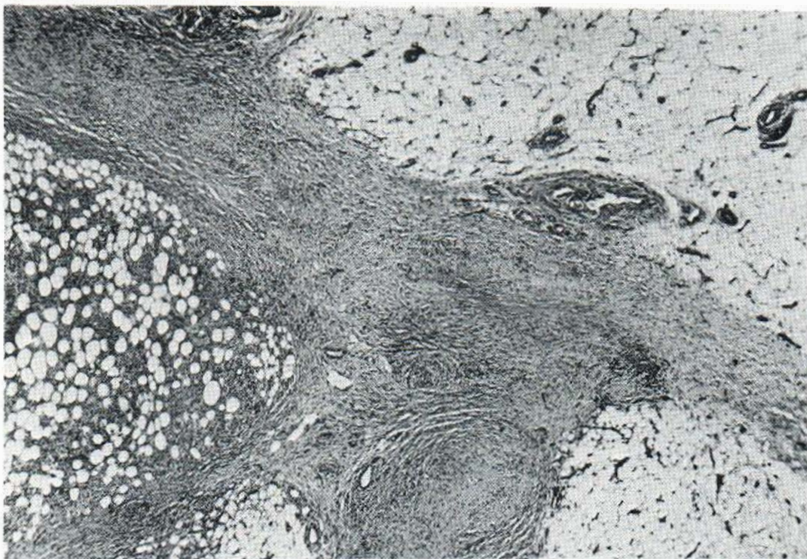


Fig. 2. Septal panniculitis with vasculitis of a clinically typical erythema nodosum. At the bottom the occluded lumen of a medium-sized artery can be seen (HE, 2.5×12.5).

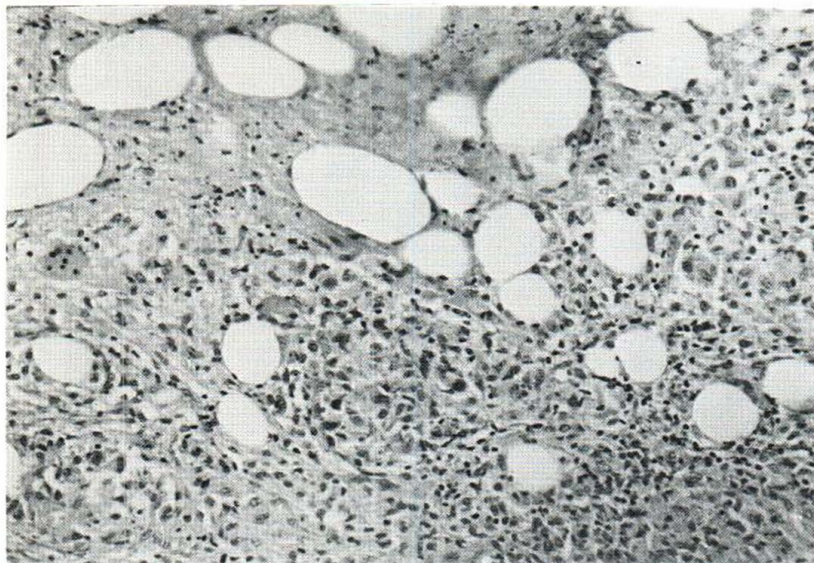


Fig. 3. Lobular panniculitis with a large subcutaneous necrosis and three or four small epithelioid cell granuloma formations at the bottom. The case represented clinically non-definite panniculitis (HE, 10×12.5).

sugar values; all belonged to the clinical EI group. Quantitative Mantoux test was performed in almost the whole series (Table I). The patients with EI and NDP were more sensitive to tuberculin than those with ENTy and ENmi, but there was no difference in the tuberculin sensitivity between EI and NDP and between ENTy and ENmi, respectively.

II. Histopathological Study

Without any knowledge of the clinical diagnosis the patients were divided into two main groups, namely those with septal and those with lobular

panniculitis and the latter into a further 4 subgroups on the basis of other histopathological findings (Table II). In this study, the term vasculitis means necrosis or fibrinoid degeneration of the vessel wall, also showing an infiltration of polymorphonuclear leukocytes. Perivascular lymphocytic inflammation is regarded as perivasculitis.

The inflammatory changes were so diffuse and mild in 4 cases that these could not be classified either as septal or as lobular panniculitis. These cases were clinically classified as erythema nodosum.

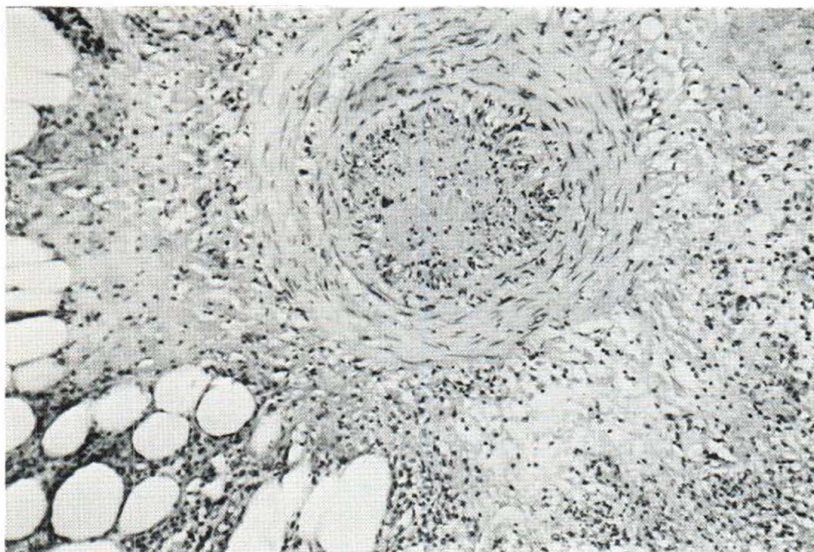


Fig. 4. Lobular panniculitis with medium-sized arteritis. The whole intima is necrosed and lumen occluded. Clinically the case belonged to non-definite panniculitis (HE, 10×12.5).

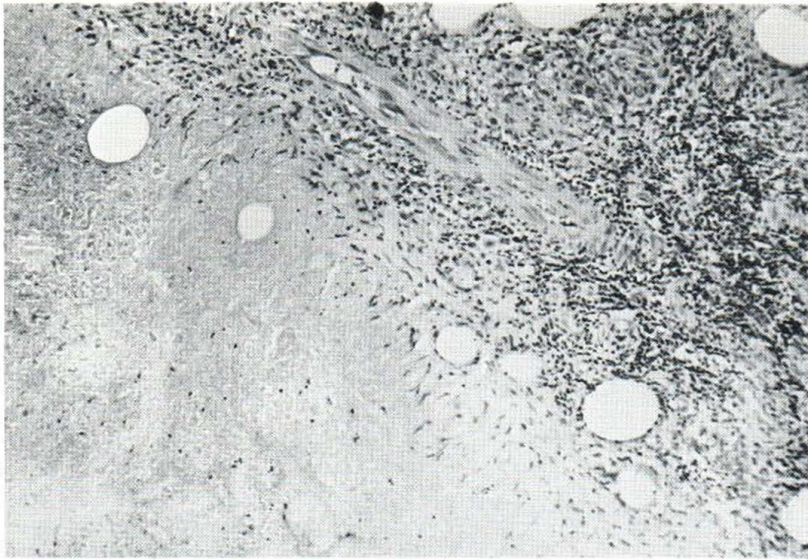


Fig. 5. Lobular panniculitis with palisade granuloma formation in erythema induratum (HE, 10×12.5).

Septal panniculitis

The 43 cases of septal panniculitis belonged either to ENTy or ENmi groups and in one case to NDP. Histologically there was no difference between ENTy and ENmi. Thirty-eight cases were classified as pure septal panniculitis (Fig. 1). In 5 additional cases, there were also inflammatory changes in the vessel walls, either in a large vein, or in small vessels, or in large arteries as in 3 cases (Fig. 2). Four of these 5 patients with vasculitis had yersinia EN.

Lobular panniculitis

This main group was divided into four subgroups: 1. epithelioid granuloma with necrosis of the fat tissue, 2. lobular panniculitis with vasculitis, 3. palisading granuloma, and 4. unclassified (Table II).

Epithelioid cell granulomas with necrosis in the subcutaneous tissue but without vasculitis were the most prominent findings in 12 cases (Fig. 3).

Six cases were included in the subgroup panniculitis with vasculitis. In these, small or medium sized arteries (Fig. 4) of the subcutis were inflamed, with small foci of necrosis in 4 cases. Granulomas were found in only 2 cases. In 2 cases the perivascular tissue was fibrosed in a way reminiscent of septal panniculitis.

In 10 cases, palisading granulomas were seen in the subcutis (Fig. 5).

The fourth subgroup consisted of 3 cases with large masses of polymorphonuclear leukocytes, one

case with masses of lipophages (Fig. 6) in the fat tissue without any other alterations, and 3 cases in which necroses of varying size were seen in the middle of fat lobes. In this group vasculitis was absent, as was any kind of granuloma formation. The comparison of the histological findings of lobular panniculitis with clinical diagnosis revealed no correlation between the clinical and histological categories other than that all the cases belonged to the groups EI and NDP (Table II). Special attention was paid to the occurrence of the eosinophils, pyroninophils and giant cells. These were seen in equal numbers in different clinical and histological types.

III. Immunohistological Study

Immunoglobulins in the walls of the dermal vessels could be demonstrated in 2 cases of ENTy and in 2 cases of ENmi and in one case a variable result in consecutive biopsies was found (Table III) when a polyvalent anti-human immunoglobulin conjugate was used. In 4 out of 11 cases of EI and in 11 out of 25 cases of NDP, immunoglobulins were found in vessel walls in the dermis or subcutis, and also in capillaries of the papillary area in one case of NDP. In the last-mentioned case, the capillaries were enormously thickened and hyalinized. Variable results in consecutive biopsies were seen in one case of EI and in 3 cases of NDP. The results of the immunohistological study are compared with those of the histological study in Table IV. In the




Fig. 6. Lobular panniculitis with large macrophages. Clinical features consistent with Weber-Christian's panniculitis (HE, 10×12.5).

main group, septal panniculitis, there were only 4 cases with a positive immunoglobulin finding. In the lobular panniculitis group, cases of palisading granulomas showed immunoglobulins less frequently than those of epithelioid cell granulomas and those of vasculitis. One case in the vasculitis group with a negative immunohistological result showed histologically very severe necrotizing vasculitis. The histologically and clinically typical case of Weber-Christian's disease had immunoglobulins neither in the cutis nor in the subcutis.

Fifteen patients with positive immunohistological findings were examined with monovalent conjugates. In all of them either IgM or C₃ or both were positive. IgG was positive in one case but IgA in none.

A rabbit antihuman fibrinogen conjugate was used for the demonstration of fibrin. In the erythema nodosum groups (Table V) fibrin was found in EN_{mi} in nearly half of the cases but only in 3 of the EN_{ty} cases. The histological examination revealed a conspicuous number of lymphocytes around the fibrin-negative capillaries, whereas the fibrin-leaking capillaries were devoid of lymphocytes. In general, the duration of EN_{mi} did not correlate with leaking of the fibrin, whereas the duration of the disease in the 2 patients with EN_{ty} where fibrin could be demonstrated was unusually long (7 weeks and 3 months). The duration of the disease in the third case was short. Fibrin could be demonstrated in 10 of the 11 cases of EI and in 17 of

the 25 cases of NDP. When most conspicuous, the finding of fibrin was always present in the walls of the papillary capillaries. The comparison with the different histological groups (Table VI) showed fibrin in all cases of lobular panniculitis with vasculitis and in the majority of the other groups of lobular panniculitis but in only 8 out of 43 cases of septal panniculitis.

IV. Follow-up Study

Erythema induratum

Eight patients received antituberculous treatment. This usually consisted of streptomycin, INH and PAS for 3 months, after which streptomycin was discontinued and treatment with INH and PAS was continued for over 12 months (Table VII). The average follow-up time was 40 months (18–64 months), and all the 8 patients have remained symp-

Table III. Demonstration of immunoglobulins in dermal and/or subcutaneous vessels in clinical groups

Diagnosis	No. of cases	Immunoglobulins in the vessel walls		
		Positive	Variable	Negative
EN _{ty}	35	2	1	32
EN _{mi}	11	2	—	9
EI	11	4	1	6
NDP	25	11	3	11

Table IV. Demonstration of immunoglobulins in different histological groups of panniculitis

Immuno- globulins	Septal		Lobular				
	Septal	Septal with vascu- litis	Epithe- lioid cell granuloma, necrosis	Vasculitis (necrosis, epithelioid cell gran- uloma)	Palis- sading gran- uloma	Unclassi- fied	Non-definite mild pannicu- litis
Negative	34	5	3	3	7	3	3
Positive	4	—	9	2	1	3	—
Variable results at different times	—	—	—	1	2	1	1
Total	38	5	12	6	10	7	4

tomless. One more patient is still under antituberculous treatment, and one patient failed to appear for the follow-up study. One patient has received no treatment, and she still has nodules on her legs.

Non-definite panniculitis

Lung tuberculosis was found in one patient. She received antituberculous treatment for 12 months, during which the nodes disappeared and lung tuberculosis became inactive. Five additional cases received antituberculous treatment for 12–18 months. Three of them have remained symptomless (follow-up time 36–42 months) but in 2 cases the nodes reappeared after treatment. Seven patients received antituberculous treatment for only 3–6 months. In 4 of them, the treatment was discontinued because it had had no effect on the nodes. Three patients stopped taking the drugs of their own volition, when the nodes had disappeared. All 3 patients have been symptomless since then (follow-up time 36–40 months). Of the remaining 12 cases, one had Weber-Christian's panniculitis,

one proved to have systemic lupus erythematosus with high antinuclear antibody titres. The disease in these 2 cases is still active. In 9 cases no specific treatment has been tried. Four of them still have nodes on the legs but in 5 cases all symptoms disappeared within a few months and the patients are still symptomless. One patient failed to appear for the follow-up study.

DISCUSSION

Typical erythema nodosum is a well-established entity. Its milder but more chronic form, on the other hand, is known as erythema nodosum migrans, especially in Northern Europe (2, 3, 4, 17, 18). The series of migratory panniculitis of Vilanova and Piñol Aguadé (36, 37) and that of Perry & Winkelmann (26) apparently consisted of patients with ENmi but also of patients with other diseases.

The most prominent histological feature of EN is septal panniculitis (21). In its chronic form, granuloma formation can be seen within the septa but

Table V. Localization of fibrin in nodules on the legs

Diagnosis	No. of cases	Fibrin present in			Negative
		papillary capillaries and deep vessels	papillary capillaries only	deep vessels only	
ENty	35	0	1	2	32
ENmi	11	4	0	1	6
EI	11	6	3	1	1
NDP	25	9	5	3	8

Table VI. Demonstration of fibrin by immunofluorescent method in different histological groups

Fibrin	Septal		Lobular				Non-definite mild panniculitis
	Septal	Septal with vasculitis	Epithelioid cell granuloma, necrosis	Vasculitis (necrosis, epithelioid cell granuloma)	Palisading granuloma	Unclassified	
Negative	30	5	2	0	4	2	4
Positive	8	—	9	4	5	4	—
Variable results in diff. biopsies	—	—	1	2	1	1	—
Total	38	5	12	6	10	7	4

sometimes also in the subcutaneous fat (15). In this study, septal panniculitis was seen in every case of EN except in some initial cases with only mild inflammatory changes. Formation of epithelioid granuloma was seen neither in EN_{ty} nor in EN_{mi}. In EN due to yersiniosis, arteritis was also seen in the medium-sized arteries. Nevertheless, yersinia EN heals sooner than other types of EN, without necrosis and without scarring (23).

Immunohistological studies of EN are few. In some of them, immunoglobulins have not been demonstrated (14, 33). Some investigators have been able to demonstrate immunoglobulins in the vessel walls (24, 34) but the numbers of patients have been very small. In this study the almost constant lack of immunoglobulins is considered typical of septal panniculitis.

The clinical criteria of EI were inadequate as such. According to the results of the histological study, granuloma formation and caseation necrosis were the dominant features in only 6 cases in the EI group. In addition, such changes were seen in 6 cases of NDP, which shows that a subcutaneous necrosis does not always lead to ulceration of nodules.

Palisading granuloma as a dominant feature was found in 10 patients. Four of them had clinically typical EI but the other 6 cases belonged to the NDP group. Conditions associated with palisading granulomas have been said to belong to the major group of rheumatic diseases (rheumatoid arthritis, rheumatic fever and allied conditions) (19). However, cases without any symptoms of rheumatoid diseases have also been described (20, 38). Of our 10 cases, only one had a positive latex test, but even in this case other signs of rheumatoid diseases were absent. Necrobiosis lipoidica cannot be excluded, although the nodose clinical picture is not compatible with the diagnosis and the blood sugar test was also normal.

The variable clinical picture of lobular panniculitis with vasculitis raises the question of whether cutaneous periarteritis nodosa must be considered as a disease entity. The findings in our cases with vasculitis of medium-sized vessels agree with the descriptions of Borrie (1) and Diaz-Perez & Winkelmann (9). In one case vasculitis of small vessels was also encountered, but this patient was found to have SLE. Immunoglobulins were present in 19 of the 36 cases of EI and NDP in the walls of the

Table VII. Prognosis with or without antituberculous treatment

Patients	Antituberculous treatment		No treatment		
	Symptom-free	Continuing symptoms	Symptom-free	Continuing symptoms	Incomplete follow-up
Erythema induratum, 11	8	1	—	1	1
Non-definite panniculitis, 25	7	6	5	6	1

deep dermal or subcutaneous vessels. According to the histological groups, cases of palisading granuloma showed immunoglobulins more seldom than those with epithelioid granulomas or vasculitis.

Earlier immunohistological studies on the nodular diseases of the legs have usually concerned only a few patients. These studies have shown that immunoglobulins are occasionally found in cases of so-called nodular vasculitis, corresponding to our lobular panniculitis without vasculitis but with a perivascular inflammation (25, 30, 35). The findings in cases of vasculitis or in so-called cutaneous periarteritis nodosa are also variable (1, 9).

The pathomechanism of the diseases manifesting themselves as nodules on the legs is poorly understood. Necrotizing vasculitis and the presence of immunoglobulins in the vessel walls of the lower dermis and subcutis suggest that at least some cases in our clinical groups EI and NDP represent the Arthus type reaction. The absence of immunoglobulins and vasculitis in cases of EN does not rule out the possibility of an Arthus reaction. A possible explanation is the rapid disappearance of immunocomplexes (6) after which the reaction continues as a delayed-type reaction. Studies on yersinia EN and yersinia erythema multiforme favour this concept (23).

The role of fibrin in the lesions remains somewhat obscure. It is usually found in the site of an antigen-antibody reaction. A decreased fibrinolytic activity in the tissue has been demonstrated in connection with the nodular vasculitis (7, 10). In addition, fibrinolytic therapy seems to have a positive effect on the clinical course of the disease (8). It is probable that the presence of fibrin in the vessel walls at least reflects the lowered fibrinolytic activity and is a sign of the chronic nature of the process.

The natural course of EI and allied conditions is usually highly chronic. Antituberculous treatment of EI is usually beneficial (5, 12, 16, 39). The present results are in agreement with the previous studies. They also call for the use of such drugs in other cases of lobular panniculitis, even if their target is not known.

In this study septal and lobular panniculitis corresponded the clinical and immunohistological entities. At present, further classification of lobular panniculitis seems unjustified. The historical diagnoses, erythema induratum, cutaneous periarteritis nodosa and the like can be used only if one

bears in mind their clinical, histological, immunohistological and prognostic overlapping.

REFERENCES

1. Borrie, P.: Cutaneous polyarteritis nodosa. *Br J Dermatovener (Stockholm)* 34: 181, 1954.
2. Bäfverstedt, B.: Erythema nodosum migrans. *Acta Dermatovener (Stockholm)* 34: 181, 1954.
3. — Zur Kenntnis des atypischen Erythema nodosum. *Arch Klin Exp Derm* 208: 291, 1959.
4. — Erythema nodosum migrans. *Acta Dermatovener (Stockholm)* 48: 381, 1968.
5. Cour Andersen, S. Ia: Erythema induratum Bazin treated with isoniazid. *Acta Dermatovener (Stockholm)* 50: 65, 1970.
6. Cream, J. J., Bryceson, A. D. M. & Ryder, G.: Disappearance of immunoglobulin and complement from the Arthus reaction and its relevance to studies of vasculitis in man. *Br J Dermatol* 84: 106, 1971.
7. Cunliffe, W. J., Dodman, B., Holmes, R. L. & Forster, R. A.: Local fibrinolytic activity in patients with cutaneous vasculitis. *Br J Dermatol* 84: 420, 1971.
8. Cunliffe, W. J. & Menon, I. S.: The association between cutaneous vasculitis and decreased blood fibrinolytic activity. *Br J Dermatol* 84: 99, 1971.
9. Diaz-Perez, J. L. & Winkelmann, R. K.: Cutaneous periarteritis nodosa. *Arch Dermatol* 110: 407, 1974.
10. Dodman, B., Cunliffe, W. J. & Roberts, B. E.: Observations on tissue fibrinolytic activity in patients with cutaneous vasculitis. *Br J Dermatol* 88: 231, 1973.
11. Eberhartinger, C.: Das Problem der Erythema induratum Bazin. *Arch Klin Exp Derm* 217: 196, 1963.
12. Feiwel, M. & Munro, D. D.: Diagnosis and treatment of erythema induratum. *Br Med J*: 1109, 1965.
13. Fine, R. U. & Meltzer, H. D.: Chronic erythema nodosum. *Arch Dermatol* 100: 33, 1969.
14. Frank, H. & Metz, J.: Immunfluoreszenzmikroskopische Untersuchungen bei Erythema nodosum und Vasculitis allergica. *Z Haut Geschlechtskr* 48: 419, 1973.
15. Förström, L. & Winkelmann, R. K.: Granulomatous panniculitis in erythema nodosum. *Arch Dermatol* 111: 335, 1975.
16. Förström, L. & Hannuksela, M.: Antituberculous treatment of erythema induratum Bazin. *Acta Dermatovener (Stockholm)* 50: 143, 1970.
17. Hannuksela, M.: Erythema nodosum migrans. *Acta Dermatovener (Stockholm)* 53: 313, 1973.
18. Hellerström, S.: Erythema nodosum. *Acta Dermatovener (Stockholm)* 46: 469, 1966.
19. Johnson, W. C.: Palisading and miscellaneous granulomas. In *Dermal Pathology* (Graham, J. H., Johnson, W. C. & Helwig, E. B., eds.) Harper & Row, Publishers, Hagerstown 1972.
20. Kresbach, H.: Zur Ätiopathogenese der Vasculitiden. *Arch Klin Exp Derm* 227: 759, 1966-67.
21. Löfgren, S. & Wahlgren, F.: On the histopathology of erythema nodosum. *Acta Dermatovener (Stockholm)* 29: 1, 1949.

22. Montgomery, H., O'Leary, P. A. & Barker, N. W.: Nodular vascular diseases of the legs. Erythema induratum and allied conditions. *JAMA* 128: 335, 1945.
23. Niemi, K. M., Hannuksela, M. & Salo, O. P.: Skin lesions in human yersiniosis. *Br J Dermatol* 94: 155, 1976.
24. Parish, W. E.: Cutaneous vasculitis; antigen-antibody complexes and prolonged fibrinolysis. *Proc R Soc Med* 65: 276, 1972.
25. Parish, W. E. & Rhodes, E. L.: Bacterial antigens and aggregated gammaglobulin in the lesions of nodular vasculitis. *Br J Dermatol* 79: 131, 1967.
26. Perry, H. O. & Winkelmann, R. K.: Subacute nodular migratory panniculitis. *Arch Dermatol* 89: 58, 1964.
27. Pierini, L. E., Abulafia, J. & Wainfeld, S.: Idiopathic lipogranulomatous hypodermatitis. *Arch Dermatol* 98: 290, 1968.
28. Reed, R. J. & Clark, W. H.: Basic pathologic reactions of the skin p. 192. *In* *Dermatology in General Medicine* (Fitzpatrick, T. B., Arndt, K. A., Clark, W. H., Eisen, A. Z., Van Scott, E. J. & Vaughan, J. H., eds.). McGraw Hill Book Company, New York, 1971.
29. Röckl, H.: Die Bedeutung der Histopathologie für die Diagnostik knotiger Unterschenkel-Dermatosen. *Hautarzt* 19: 540, 1968.
30. Röckl, H., Metz, J. & Frank, H.: Vasculitis allergica profunda. *Hautarzt* 25: 477, 1974.
31. Röckl, H. & Thies, W.: Herdförmige chronisch rezidivierende Krankheitszustände des subcutanen Fettgewebes. Zur Histopathogenese der Lipogranulomatosis. *Hautarzt* 8: 58, 1957.
32. Salo, O. P. & Hannuksela, M.: Immunohistology of the Kveim reaction. *Ann Clin Res* 4: 169, 1972.
33. Schroeter, A. L., Copeman, P. W. M., Jordan, R. E., Sams, W. M. & Winkelmann, R. K.: Immunofluorescence of cutaneous vasculitis associated with systemic disease. *Arch Dermatol* 104: 254, 1971.
34. Scott, D. G. & Rowell, N. R.: Preliminary investigations of arteritic lesions using fluorescent antibody techniques. *Br J Dermatol* 77: 211, 1965.
35. Stringa, S. G., Bianchi, C. & Zingale, S. B.: Nodular vasculitis: Immunofluorescent study. *J Invest Dermatol* 46: 1, 1966.
36. Vilanova, X. & Piñol Aguadé, J.: Hypodermite nodulaire subaiguë migratrice. *Ann Dermatol Syphiligr* 83: 369, 1956.
37. — Subacute nodular migratory panniculitis. *Br J Dermatol* 71: 45, 1959.
38. Winer, L. H.: Histopathology of the nodose lesions of the lower extremities. *Arch Dermatol* 63: 347, 1951.
39. Wong, K. O.: Erythema induratum: Follow-up study of 46 patients. *Derm Dig* 10: 51, 1971.

Received January 15, 1976

K. M. Niemi, M.D.
 Department of Dermatology
 University Central Hospital
 Snellmaninkatu 14
 SF-00170 Helsinki 17
 Finland