

LICHEN PLANUS AND ACNE PROVOKED BY GOLD

Anders Hjortshøj

From the Department of Dermatology and Venerology, University Hospital, Odense, Denmark

Abstract. A 58-year-old man with rheumatoid arthritis developed lichen planus during treatment with gold. Four months after cessation of treatment, a severe acne with comedones, papules, pustules, and small cystic elements broke out. No connection could be demonstrated between the eruption and other drugs or chemicals. Acne provoked by gold seems not to have been described elsewhere. The case history confirms that gold treatment, even in the same patient, can give rise to a wide range of skin disturbances, which in many cases do not break out until long after the drug has been withdrawn.

Key words: Gold reactions; Gold dermatitis; Lichen planus; Acne

Since the 'thirties it has been known that lichen planus may be produced by gold (4)—actually it is not an uncommon form of gold dermatitis (6). Acneiform eruptions may be induced by several drugs (2), but acne provoked by gold seems not to have been reported previously. Our patient is remarkable in that after gold treatment he initially developed lichen planus and subsequently acne.

CASE HISTORY

A 58-year-old man who has been suffering from joint pain for several years. A sister had rheumatoid arthritis. There was no family history of skin diseases. Previously the patient has been in good health, with no history of acne in youth.

In 1972, due to suspicion of gout, treatment with allupurinole (Apurin, GEA) was started. The concentration of uric acid in serum was normal. However, in February, 1975, tests for rheumatoid factor became positive, and X-ray film revealed changes in the wrists and the metacarpophalangeal joints of hands and feet, compatible with rheumatoid arthritis. Consequently the treatment with allupurinole was discontinued, and on 11th March treatment with gold sodium thiomalate (Myocrisin, Pharma-Rhodia) 50 mg at weekly intervals was started in the rheumatological outpatient clinic. In April, when 210

mg had been given, the patient was transferred to his family doctor for continued gold treatment. In the middle of May signs of stomatitis occurred and, therefore, on 21st May the drug was withdrawn. A total of 510 mg gold sodium thiomalate had been given. The stomatitis was aggravated, and an exanthema broke out. On 29th May triamcinolone acetonide in orabase (Kenalog, Squibb) was prescribed, and from 4th June in addition, prednisone 30 mg per day, from 9th June 15 mg per day, from 12th June 10 mg per day, and from 17th June 5 mg per day until in the last days of June when the drug was withdrawn. In spite of the treatment with prednisone the skin disease was still aggravated. It spread over the entire body and produced severe itching.

On 25th July the patient was seen for the first time in the dermatological outpatient clinic. Physical examination showed a universal rash consisting of violaceous, partly confluent papules, some of which were hyperkeratotic. In the buccal mucosa white spots, streaks and small erosive lesions were seen.

Diagnosis: Lichen planus (gold induced).

A biopsy specimen of skin taken from the back demonstrated hyperkeratosis, liquefaction degeneration of the basal cell layer, and sawtooth-like border between epidermis and dermis. High in the dermis an intense, band-like infiltration of lymphocytes was seen.

Histopathological diagnosis: Lichen planus (signed O. B. Henriksen and H. E. Christensen).

The lichenoid eruption disappeared, and the buccal mucosa returned to normal after treatment with betamethasone valerate (Celestonvalerate, Essex) for 2 weeks and hydrocortisone butyrate (Locoid, Gist-Brocades) for 4 weeks, supplemented with triamcinolone acetonide in orabase.

Approximately 2 weeks after the first admission an increased pigmentation was observed on the face. This hyperpigmentation gradually spread and intensified, affecting the face, neck, and upper parts of chest and back.

Examination on 4th November showed numerous open comedones and a few papules and pustules on the chest. During the following 2 months the patient's acne worsened, and numerous comedones developed on the face and shoulders. On the chest a steadily increasing

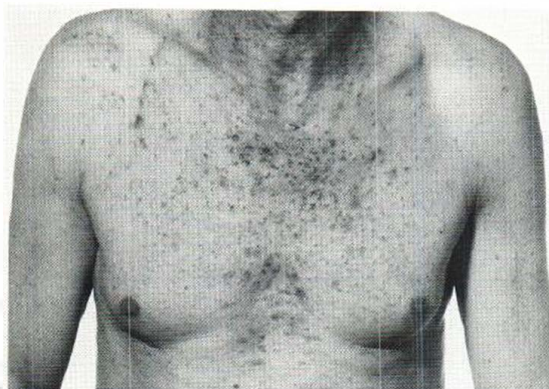


Fig 1. Comedones, papules, pustules, and small cystic elements on the chest. Hyperpigmentation on the neck.

number of papules, papulo-pustules, and small cystic elements appeared (Figs 1 and 2).

Diagnosis: Acne medicamentosa (gold).

Laboratory examinations

Hb, WBC, platelet count and serum-creatinine: normal. ESR was 16 mm/h rising to 30 mm/h. All liver function tests were normal. IgG, IgA, IgM and alfa-2-macroglobulin were all normal.

DISCUSSION

Lichen planus-like eruptions after gold treatment have been reported previously. In their comprehensive material including 900 patients treated with gold, Hartfall et al. (4) found in 1937 262 cases of skin disturbances, only 2 of which were lichen planus. However, according to a recent investigation (6) lichen planus is one of the more common eruptions provoked by gold.

Distinctive hyperpigmentation is common after drug-induced lichen planus (8). Chrysiasis might be a theoretical possibility, though it has only been seen after doses exceeding altogether 50 mg of gold sodium thiosulphate per kilogram body weight (9), and it is not common until 150 mg of gold sodium thiomalate per kg of body weight have been given (1). Our patient had received about 6 mg of gold sodium thiomalate per kg of body weight only.

Systemic treatment with corticosteroids may provoke an acneiform eruption. It will usually be characterized by papules, however, and not by comedones (2, 5), and moreover it will often occur in persons who have grown cushingoid due to treatment with corticosteroids (2, 5). Our patient had

been treated for approximately 3 weeks only, with rather small doses of prednisone and he did not show any signs of Cushing's syndrome. Furthermore, on the outbreak of his acne the treatment with prednisone had been discontinued for 4 months.

Prolonged treatment with high strength steroids under occlusion may produce papulous acne which, some weeks later, will be followed by a comedo formation consisting mainly of closed comedones (7).

For about 2 weeks our patient was treated with topical application of high potency steroid (betamethasone valerate), and then for approximately 4 weeks with a less potent steroid (hydrocortisone butyrate). Occlusive treatment has not been given at any time. When the acne broke out, the topical treatment had been discontinued for 6 or 8 weeks. It is thus rather unlikely that the patient's acne was caused by the steroid, either the topical or the systemic administration.

The patient was a shipbuilder. He had a clean and dry job as a sorter, and he did not come into contact with oil products or any other acneogenic materials.

It is a well known fact that gold is retained in the body for a very long time, especially bound in the kidneys, liver, and skin (1), and the excretion of gold can be demonstrated in the urine for up to 12 months after treatment has ceased (3). As the patient did not take any kind of drugs, and he did not come into contact with acneogenic materials, it seems most likely that his acne was provoked by the gold.

The patient's reaction to the gold treatment was peculiar and unusual. The case history shows that gold treatment even in the same patient may cause a

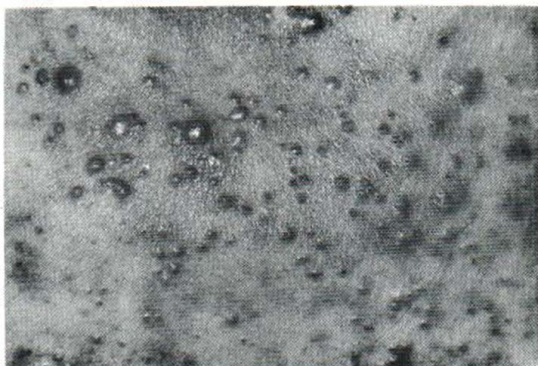

Fig 2. Close-up of acne elements on the chest.

number of skin disturbances, which often do not break out until long after the treatment has been discontinued.

REFERENCES

1. Almeyda, J. & Baker, H.: Cutaneous reactions to antirheumatic drugs. *Br J Dermatol* 83:707, 1970.
2. Fegeler, F.: Acneiforme Arzneixantheme. *Arch Klin Exp Derm* 219:335, 1964.
3. Goodman, L. S. & Gilman, A.: *The Pharmacological Basis of Therapeutics*, p. 971. The Macmillan Company, New York, 1970.
4. Hartfall, S. J., Garland, H. G. & Goldie, W.: Gold treatment of arthritis, a review of 900 cases. *Lancet* II:838, 1937.
5. Hitch, J. M.: Acneiform eruptions induced by drugs and chemicals. *JAMA* 200:879, 1967.
6. Penneys, N. S., Ackerman, A. B. & Gottlieb, N. L.: Gold dermatitis, a clinical and histopathological study. *Arch Dermatol* 109:372, 1974.
7. Plewig, G. & Kligmann, A. M.: Induction of acne by topical steroids. *Arch Dermatol Forsch* 247:29, 1973.
8. Rook, A., Wilkinson, D. S. & Ebling, F. J. G.: *Textbook of Dermatology*, p. 1351. Blackwell Scientific Publications, Oxford, 1972.
9. Schmidt, O. E. L.: Chrysiasis. *Arch Dermatol Syph* 44:446, 1941.

Received February 27, 1976

A. Hjortshøj, M.D.
Department of Dermatology
Odense Sygehus
DK-5000 Odense
Denmark