

SHORT REPORT

Crohn's Disease—Non-caseating Granulomas on the Legs

Joseph A. Witkowski, Lawrence Ch. Parish,
and John E. Lewis

*Department of Dermatology,
University of Pennsylvania School of Medicine,
Philadelphia, Pennsylvania, USA*

Received October 26, 1976

Abstract. A 27-year-old black man with Crohn's disease and nodules on the legs is described. Such nodules constitute one of three types of cutaneous manifestations which have a histological picture of a non-caseating granuloma. The two other varieties of skin lesions described are: that resulting from a direct spread from the gastrointestinal tract, and that resulting from spread over contiguous skin.

Key words: Crohn's disease; Non-caseating granuloma

In recent years, several types of non-caseating granulomatous skin lesion have been reported on patients afflicted with Crohn's disease. These cutaneous manifestations have been found (1) in the perianal area caused by direct extension of the disease process, as well as in laparotomy scars, around colostomies, ileostomies, fistulae and the umbilicus; (2) on the buttocks, perineum, crural folds, and abdominal wall, due to spread over contiguous skin; and (3) at distant sites far removed from the gastrointestinal tract.

This last variety is the least common. Our review of the literature has disclosed only one other report of such remote lesions, in the breast area and on the penis (2). We recently had the opportunity to observe a patient who had such granulomatous lesions on the legs.

CASE REPORT

A 27-year-old black man reported to the Dermatology Clinic of Philadelphia General Hospital for evaluation of painful and tender nodules which had been present on his legs for approximately 5 years. Ten months before the nodules appeared, he had noted the gradual onset of malaise, lassitude and diarrhea. He has had between 5 and 15 brownish to reddish watery stools daily. The nodules have a tendency to appear in November and to persist throughout the cold weather. He found that wearing elastic hose was partially helpful in relieving the leg discomfort.

There was a history of occasional episodes of arthritis in the knees and ankles, bouts of low grade fever, "night sweats" and a twenty pound weight loss over the preceding 6 months. Two years before, a large horseshoe-shaped perianal abscess required surgical drainage. Unfortunately this appeared again one year ago, at which time he also had bilateral uveitis. He is presently receiving salicylazosulfapyridine (Azulfidine®; Pharmacia) 1.0 gram Q.I.D. with minimal relief of his symptoms.

The physical examination revealed a well developed, thin black man who did not appear to be chronically ill. Extensive scarring could be seen on the perianal and gluteal areas. The legs and ankles showed firm, reddish brown, tender nodules and plaques on the anterior surfaces (Fig. 1).

Investigations disclosed a hypochromic microcytic anemia (hemoglobin 10 grams per 100 ml), white blood cells 8700 per mm³, erythrocyte sedimentation rate 23 mm/hr (Wintrobe-corrected) and gamma globulin 2.1 (normal 0.97-1.75) on serum protum electrophoresis. Barium enema and small-bowel X-rays showed changes typical of Crohn's disease in the terminal ileum, cecum, entire colon, but sparing the rectum. The X-ray picture of the knees and ankles was normal. Rectal biopsy showed lymphoid hyperplasia capillary proliferation, marked eosinophilia and scattered epithelioid granulomas. Skin biopsy from the leg showed proliferation of capillaries in the dermis with perivascular aggregations of lymphocytes and epithelioid cells, with an occasional giant cell (Fig. 2).

DISCUSSION

Although Crohn's disease is primarily a gastrointestinal condition, between 20 and 44% of the patients have cutaneous involvement (1, 3). The most

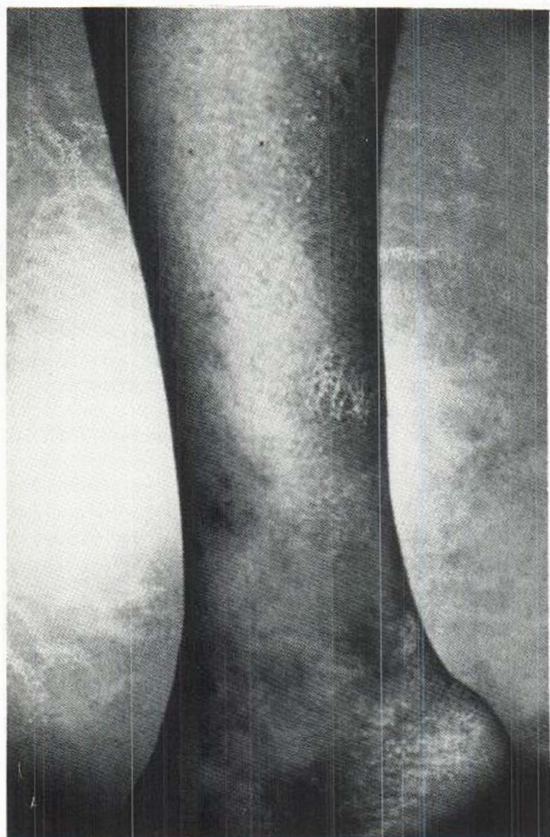


Fig. 1. Nodules on the lower extremity.

commonly seen lesions are those occurring in close proximity to the gastrointestinal tract and are apparently due to direct extension of the disease process. The range includes perianal ulcers, fissures, fistulae, ischio-rectal abscesses, bluish edematous nodules which often become indolent ulcers, and condyloma-like lesions. Histologic examination of most of these lesions will reveal a non-caseating granuloma. Cutaneous manifestations appearing on areas remote from the gastrointestinal tract are less common. They may be separated into four clinical forms: (1) erythema nodosum, (2) pyoderma gangrenosum, (3) livido reticularis with nodules, and (4) indolent nodules and ulcers. Whereas the first three varieties are vasculitic in origin, the last-mentioned is characterized by a sarcoid-like histologic pattern.

The differential diagnosis of these nodose lesions on the legs might include nodular vasculitis, erythema induratum, subacute migratory panniculitis, and subcutaneous fat necrosis associated with pancreatic disease. A histological picture of a non-caseating granuloma would necessarily exclude all but sarcoidosis.

Why such non-caseating granuloma would choose to appear on skin sites remote from the gastrointestinal tract is open to speculation. One

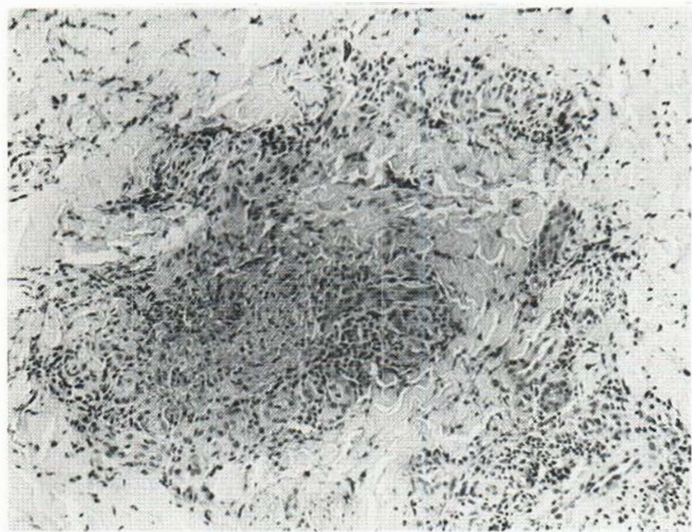


Fig. 2. High magnification of a section from nodule on lower extremity showing capillary proliferation with perivascular collections of lymphocytes, epithelioid cells and an occasional giant cell representing part of non-caseating granuloma. (Hematoxylin-Eosin, original magnification $\times 95$.)

possibility could include a local reaction to a toxin or immunogen localized at a site of trauma, or on the legs because of stasis. Although conclusive evidence is currently unavailable, the history of an intertrigo preceding the appearance of the lesion on the breast area and the improvement associated with use of elastic stockings does suggest an etiological role for these factors.

REFERENCES

1. McCallum, D. I. & Kinmont, P. D. C.: Dermatological manifestations of Crohn's disease. *Br J Dermatol* 80: 1, 1968.
2. Parks, A. G., Morson, B. C. & Pegum, J. S.: Crohn's disease with cutaneous involvement. *Proc Roy Soc Med* 58: 241, 1965.
3. Samitz, M. H.: Skin complications of ulcerative colitis and Crohn's disease. *Cutis* 12: 533, 1973.