

## DEPOSITION OF FIBRINOGEN (FR-ANTIGEN) IN SKIN DISEASES

### III. Synovial Joint Membranes in Psoriatic Arthritis

Ole Fyrand and Ove Johan Mellbye

*From the Department of Dermatology and Institute of Immunology  
and Rheumatology, Rikshospitalet, Oslo, Norway*

**Abstract.** Synovial joint membranes obtained by synovectomy in open bloodless fields were examined for FR-antigen (fibrinogen/fibrin-related antigen) in 15 patients with psoriatic arthritis (ps.a.) and in a control group of 5 patients with meniscal tears. All frozen and paraffin sections from ps.a. demonstrated FR-antigen at the synovial lining. In the tissue it was located at the surface and in cytoplasm of the superficial synovial cells. In the control group, FR-antigen was present in all frozen samples as a thin layer at the synovial lining surface, but absent in the paraffin sections. The presence of FR-antigen may contribute to the further development of the inflammatory changes of the arthritis.

**Key words:** Psoriatic arthritis; Synovial joint membranes; FR-antigen (fibrinogen/fibrin-related antigen)

Deposits of FR-antigen (fibrinogen/fibrin-related antigen) (16), investigated with direct immunofluorescence (IF) technique, have been demonstrated in the skin in psoriatics (8, 9, 18). The IF was found in the upper part of the dermis near the dermo-epidermal junction as a continuous network of fine threads. This deposition was found in psoriasis vulgaris (8), but most pronounced in psoriatic arthritis (ps.a.) (8) and pustulosis palmo-plantaris (9). Increased amounts of heparin-precipitable fraction have been demonstrated in plasma in ps.a. (7, 8), consisting mainly of unchanged fibrinogen and cold insoluble globulin (11, 12). Deposition of FR-antigen has been demonstrated in synovial membranes in rheumatoid arthritis (17), and has been claimed to be of significance for the disease process (6). As such studies on synovial joint membranes in ps.a. have evidently not been reported, this aspect was chosen as the subject of the present investigation.

### TISSUES

Synovial joint tissues were obtained by synovectomy in bloodless fields from 15 patients (7 females and 8 males) with psoriatic arthritis (ps.a.) and from 5 male patients with meniscal tears serving as a control group. The diagnosis of ps.a. was based upon the presence of seronegative arthritis as judged by the Rose-Waaler and latex tests for rheumatoid factor (15/15 cases), preferably affection of distal interphalangeal joints (11/15 cases), with typical psoriasis of the skin (15/15 cases) and mostly with psoriatic changes of the nails (onycholysis, pitting) (11/15 cases). In 4/8 cases examined, tissue typing demonstrated the presence of the antigen HLA-B27 in ps.a.

### METHODS

Immediately after synovectomy the synovial joint membranes were kept for a few minutes in 0.15 M NaCl at 4°C and then quickfrozen in Tissue-Tec OCT compound (Lab-Tek Products Division, Miles Laboratories Inc., Naperville, Ill., USA) using dry ice-acetone/isopentane and stored at -25°C until used. In 3/15 cases, parallel with quick freezing, synovial joint tissues were stirred in phosphate-buffered saline, pH 7.4, for 18 hours at 4°C and embedded in paraffin according to a modified Sainte-Marie technique (5).

#### *Immunofluorescence studies*

For direct IF studies on FR-antigen, FITC-labelled rabbit anti-fibrinogen was obtained from Behringwerke (Marburg Lahn, West Germany). The F/P ratio of the conjugate was 2.1, with a final IgG concentration of 2.5 mg/ml. The specificity of the conjugate was tested by immunoelectrophoresis and selective blocking of positive immunofluorescence by the addition of fibrinogen (AB

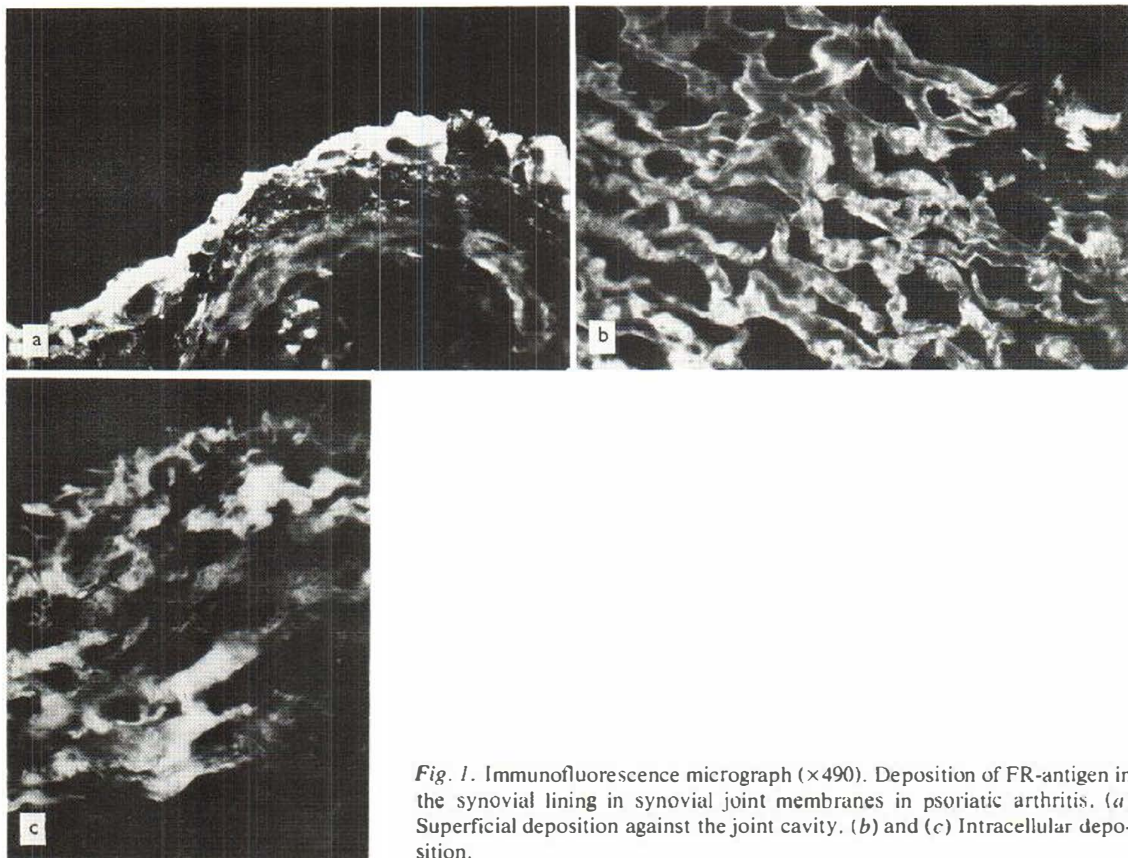


Fig. 1. Immunofluorescence micrograph ( $\times 490$ ). Deposition of FR-antigen in the synovial lining in synovial joint membranes in psoriatic arthritis. (a) Superficial deposition against the joint cavity. (b) and (c) Intracellular deposition.

Kabi, Stockholm, Sweden). Direct immunofluorescence examinations were performed on  $4\ \mu\text{m}$  thick sections and with a Leitz Orthoplan microscope equipped for incident light.

## RESULTS

### *Depositions of FR-antigen*

By direct IF examination, FR-antigen was found in all frozen and paraffin-embedded sections from patients with ps.a. (Table I). The IF was located at the synovial lining, mostly concentrated at its surface (Fig. 1a), though often extending into the deeper cell layers. In some samples, these depositions were seen only in a few villous structures, but mostly they formed a continuous pattern. The staining intensity was greatest at the synovial lining surface, often as a homogeneous layer, gradually weakening in the deeper parts of the sections. In samples with villous hypertrophy, the picture was often that of an alveolar-like structure, with FR-

antigen deposited along the alveolar lumina. In the other sections, a broader zone of hypertrophic synovial lining cells demonstrated IF (Fig. 1b) with the staining being most pronounced at the cell membrane, though also present in the cytoplasm, forming a pattern of grains, streaks and 'cotton-wool' structures (Fig. 1c).

In frozen sections from the control group, FR-antigen was found as a thin layer at the surface of the superficial lining cells, but was absent in the corresponding washed, paraffin-embedded sections. This was in contrast to its persistence in paraffin-sections in ps.a. (Table I).

## DISCUSSION

When evaluating results from different research groups investigating ps.a., it must be remembered that the groups of patients from which these are obtained may not be comparable, due to the lack of fixed criteria for the diagnosis of this disease.

Table 1. FR-antigen in synovial joint membranes in psoriatic arthritis and meniscal tears (control group) based upon direct immunofluorescence studies

Diagnosis	No.	FR-antigen		
		Positive	Degree <sup>a</sup>	Localization <sup>b</sup>
<i>Psoriatic arthritis</i>				
Frozen sections	15	15/15	12/15 strong 3/15 medium	10/15 S+D 5/15 S
Paraffin sections	3	3/3	1/3 strong 2/3 medium	2/3 S+D 1/3 S
<i>Meniscal tears</i>				
Frozen sections	5	5/5	3/5 medium 2/5 weak	5/5 S
Paraffin sections	5	0/5	—	—

<sup>a</sup> Degree of immunofluorescence.

<sup>b</sup> S=superficial, D=deeper.

Labelled anti-fibrinogen may react with various antigenetically related proteins, which is why we are using the term FR-antigen (16). When quoting information from the literature in this field, we are using the terms indicated by the different authors.

In normal synovial fluid, FR-antigen is absent (2, 19), and when isotope-labelled fibrinogen is injected into normal rabbit joints, it is rapidly and almost completely removed from the liquor, though significant amounts (24%) are found in the synovial membrane (15).

In synovial tissues, only traces of thromboplastic activity are found, which, together with rapid fibrinogenolysis, is probably responsible for the partial clotting failure of blood in the joints, whereas fibrinolysis occurs very slowly, if at all (14). This is demonstrated in rheumatoid arthritis, where fibrinolysis is completely absent from synovial cells (3) and fibrin persists in the superficial layers of the synovial membranes (13).

FR-antigen is generally present in inflammatory joint lesions, and this correlates well with its presence in our cases in both the ps.a. and the control group. The deposits in our cases were localized mainly in the superficial layer of the synovial membrane, where the greatest amount of fibrin stabilizing factor is found (3), together with a generally low degree of fibrinolytic activity of the synovial tissue (1, 14). The persistence of FR-antigen in washed, paraffin-embedded samples in ps.a., in contrast to the control group where it was found only in frozen unwashed sections, indicates a different mode of binding or deposition of FR-antigen

in ps.a. Furthermore, the types of FR-antigen (fibrin, fibrinogen, or degradation products) operative in ps.a. and in the controls, may differ. With our methods, this cannot be asserted conclusively, however. The type of FR-antigen may be of further importance in the development of the arthritis, demonstrating different degrees of leukocytotactic action, and thus may determine the severity and duration of the arthritic component (4). Experiments in rabbits with intra-articular injections of fibrin induce an arthritis resembling rheumatoid arthritis, and if rheumatoid arthritis is an autoimmune disease, the products of inflammation may be just as important in the process as the primary auto-antigen (6).

The presence of immunoglobulins has been demonstrated in plasma cells and in the tissue in synovial joint membranes in ps.a. (10). In contrast to rheumatoid arthritis (17), complement (C3) was absent.

The presence of immunoglobulins and FR-antigen most likely represents an important factor in the development of psoriatic arthritis. FR-antigen probably does not represent the primary event in the pathogenesis of psoriatic arthritis, but it may be an important contributory factor in the further development of the disease.

## REFERENCES

1. Astrup, T. & Sjølin, K.: Thromboplastic and fibrolytic activity of human synovial membrane and fibrous capsular tissue. *Proc Soc Biol (N.Y.)* 97: 852, 1958.

2. Bach Andersen, R. & Gormsen, J.: Fibrin dissolution in synovial fluid. *Acta Rheum Scand* 16: 319, 1970.
3. — Fibrinolytic and fibrin stabilizing activity of synovial membranes. *Ann Rheum Dis* 29: 287, 1970.
4. Barnhart, M. I., Riddle, J. M., Bluhm, G. B. & Quintana, C.: Fibrin promotion and lysis in arthritic joints. *Ann Rheum Dis* 26: 206, 1967.
5. Brandtzaeg, P. & Kraus, F. W.: Autoimmunity and periodontal disease. *Odont T* 73: 338, 1965.
6. Dumonde, D. C. & Glynn, L. E.: The production of arthritis in rabbits by an immunological reaction to fibrin. *Br J Exp Path* 43: 373, 1962.
7. Fyrand, O.: Heparin-precipitable fraction (HPF) in an unselected material of dermatological inpatients. *Acta Dermatovener (Stockholm)* 54: 293, 1974.
8. Fyrand, O. & Husby, G.: Deposition of fibrinogen (FR-antigen) in skin diseases. I. Psoriasis vulgaris and psoriasis arthropathica. *Acta Dermatovener (Stockholm)* 55: 175, 1975.
9. Fyrand, O., Mellbye, O. J. & Eeg Larsen, T.: Deposition of fibrinogen (FR-antigen) in skin diseases. II. Pustulosis palmaris et plantaris. *Acta Dermatovener (Stockholm)* 55: 469, 1975.
10. Fyrand, O., Mellbye, O. J. & Natvig, J. B.: Immunofluorescent studies on synovial tissue in psoriatic arthritis. *J Invest Dermatol* 66: 255, 1976.
11. Fyrand, O. & Solum, N. O.: Heparin precipitable fraction (HPF) from dermatological patients. II. Studies on the non-clottable proteins. Identification of cold insoluble globulin as the main non-clottable component. *Thromb Res* 8: 659, 1976.
12. Fyrand, O., Solum, N. O. & Kierulf, P.: Heparin precipitable fraction (HPF) from dermatological patients. I. Characterization of the thrombin-clottable protein. *Thromb Res* 8: 17, 1976.
13. Glynn, L. E.: The chronicity of inflammation and its significance in rheumatoid arthritis. *Ann Rheum Dis* 27: 105, 1963.
14. Harold, A. J.: Fibrinogenolysis in joints. *Nature* 186: 1057, 1960.
15. — Elimination of fibrinogen from synovial joints. *Ann Rheum Dis* 32: 29, 1973.
16. Merskey, C., Lalezari, P. & Johnson, A. J.: Tanned red cell hemagglutination immunoassay for fibrinogen-fibrin-related antigen ("Fibrinolytic degradation products") in human serum. *Scand J Hematol. Suppl.* 13: 83, 1971.
17. Munthe, E. & Natvig, J. B.: Immunoglobulin classes, subclasses and complexes of IgG rheumatoid factor in rheumatoid plasma cells. *Clin Exp Immunol* 12: 55, 1972.
18. Salo, O. T., Kousa, M., Mustakallio, K. K. & Lassus, A.: Demonstration of fibrin in skin diseases. II. Psoriasis. *Acta Dermatovener (Stockholm)* 52: 295, 1972.
19. Zvaifler, N. J.: The immunopathology of joint inflammation in rheumatoid arthritis. *In Advances of Immunology* (ed. J. F. Dixon & H. G. Kunkel), vol. 16, p. 265. Academic Press, New York and London 1973.

Received September 6, 1976

O. Fyrand, M.D.  
 Department of Dermatology  
 Rikshospitalet  
 Oslo  
 Norway