

BETA-2-MICROGLOBULIN IN BASAL CELL CARCINOMA

Ulla Malmnäs Tjernlund and Urban Forsum

From the Department of Dermatology, University Hospital, Uppsala, Sweden

Abstract. Differences in the cell surface of malignant cells, as compared with normal cells, are believed to be characteristic of many features of tumour cell behaviour. We have obtained evidence suggesting that solid and superficial basal cell carcinomas lack immuno-reactive beta-2-microglobulin (beta-2-m) on the cell surface, in contrast to normal epidermis and that of various non-malignant dermatoses, including basal cell papillomas.

Key words: Basal cell carcinoma; Beta-2-microglobulin; Immunofluorescence

The major human histocompatibility antigens, the HLA antigens, are composed of two types of polypeptide chains (2, 8, 10): one heavy chain, carrying the antigenic specificity, and one light chain, which is invariant and has been identified as beta-2-microglobulin (beta-2-m) (1, 5, 6, 8).

Beta-2-m appears to be present at the surface of all human nucleated cells hitherto investigated, most of which have been studied in cell culture systems (3, 7) with the exception of the B-cell derived human Daudi lymphoblastoid line (7). It has been claimed that HLA heavy chains are present on the surface of the Daudi cells (11). By means of immunofluorescence (IFL), antibeta-2-m has been shown to bind to cell surface associated beta-2-m in both epithelial cells cultures (9) and cyrostat sections of human epidermis (4).

Changes in the surface properties of tumour cells have attracted widespread attention in recent years, as they may be important in determining behavioural characteristics of the tumour, such as its ability to proliferate in an uncontrolled fashion, invade normal tissue, and metastasize to distant sites. One may ask what alterations in the surface properties of tumour cells contribute to their escape from the controls to which normal cells are subject.

In this study we have investigated the cell surface reactivity to antibeta-2-m, concanavalin A (Con A) and pemphigus antibodies in basal cell carcinomas and basal cell papillomas, with the aim of elucidating possible differences in the cell surface binding of these markers in epidermal tumours.

MATERIALS AND METHODS

Skin biopsies were taken from basal cell carcinoma lesions and basal cell papillomas, using a punch 3-5 mm in diameter, and were quick-frozen in isopentane at -70°C . Most specimens were then sectioned immediately at $6\ \mu\text{m}$ on a cryostat, but some were stored at -70°C and sectioned within 3 days.

Fluorescein isothiocyanate (FTC)-conjugated Con A and FTC-conjugated rabbit antihuman beta-2-m (Dakopatts A/S, Copenhagen, Denmark), lot no. 066, diluted in phosphate-buffered saline (PBS) with 4% bovine serum albumin (PBS-BSA) to a titre of 1/10-1/320 were used for direct immunofluorescence, and binding of pemphigus antibodies was traced by indirect immunofluorescence, using conjugated specific antihuman IgG (lot no. 075) as described previously (4). Con A was conjugated with fluorescein isothiocyanate as described earlier (4).

The slides were air dried, incubated with conjugates for 30 min at room temperature, washed thoroughly in PBS (pH 7.0) and mounted in 10% glycerol PBS (pH 7.2). For indirect tests, the slides were first incubated with positive pemphigus serum (diluted in PBS-BSA 4% to a titre of 1:10) for 30 min at room temperature, and then with conjugates.

The slides were examined in a Leitz Orthoplan microscope with incident light and blue, narrow band activation, and illuminated with a Xenon XBO-75 lamp. FTC fluorescence was detected with the filter combination K 480, 2 KP 490, TK 510/K 515 and a secondary filter K 510.

The slides were read blind and decoded after examination. The same sections that were examined for IFL were afterwards stained with hematoxylin-eosin for light microscopy. Routine histo-pathological examination was made on parallel biopsies taken from the lesion.

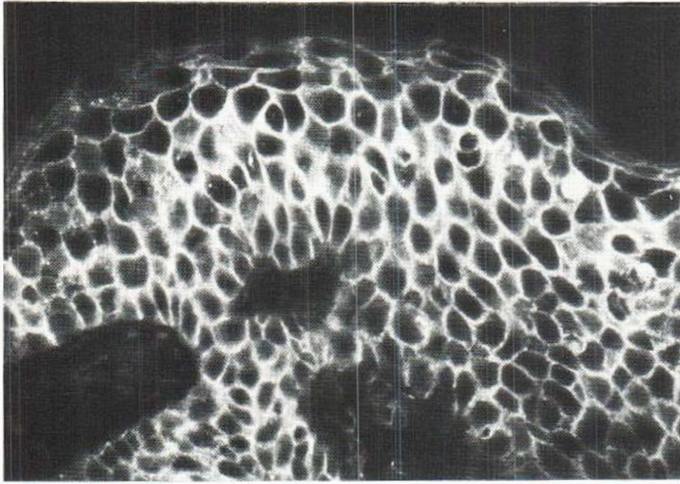


Fig. 1. Immunofluorescence pattern of a basal cell papilloma incubated with FITC-labelled antihuman-beta-2-microglobulin, dilution 1:10, showing interepithelial fluorescence in the whole epidermis.

RESULTS

Skin biopsies from 21 patients with basal cell carcinoma and from 8 patients with basal cell papilloma were investigated. Of the basal cell carcinomas, 17 were solid growing (3 were rich in connective tissue), one was fibrosing (morphea-like) and 3 were superficial.

In an earlier study (4), normal skin biopsies and biopsies from lesions as well as seemingly normal skin from patients with cold urticaria, contact dermatitis, dermatitis herpetiformis, erythema multiforme, pemphigoid, psoriasis, and SLE all showed the same degree of reactivity to conjugated anti-beta-2-m—that is, a strong interepithelial fluorescence from the basal layer upwards at a titre of 1:10 (Table I) to 1:80.

Table 1. Immunofluorescence reactions of normal and pathological skin to FITC-conjugated anti-beta-2-microglobulin, showing a regular intercellular pattern at a conjugate dilution of 1:10

Diagnosis	Number	Regular intercellular pattern of FITC-conj. antihuman beta-2-m at a titre of 1:10
Normal skin	34	34
Basal cell papilloma	8	8
Miscellaneous dermatoses ^a	20	20
Basal cell carcinoma	21	1

^a See ref. 4.

The 8 basal cell papillomas in this study also exhibited strong interepithelial fluorescence in the whole epidermis at a titre of 1:80, but it was still detectable at a titre of 1:320 (Table II and Fig. 1).

In sharp contrast to the normal skin and non-malignant skin lesions, biopsies from 12 patients with solid growing basal cell carcinoma showed an interepithelial fluorescence only in the uppermost parts of the section—that is, in the normal epidermis—while in the carcinomatous parts no cell membrane-associated beta-2-m was found (Table II and Fig. 2). The fluorescence of the normal epidermis above the carcinomatous tissue, like that in the basal cell papillomas, was strong up to a titre of 1:80 and still detectable at 1:320. In 5 cases of solid basal cell carcinoma, including 3 rich in connective tissue, an irregular pattern of fluorescence was revealed: in certain parts of the carcinoma tissue there was brilliant intercellular staining, while most parts lacked detectable beta-2-m (Table II). In none of the 3 superficial basal cell carcinomas was any interepithelial fluorescence observed in the carcinoma tissue (Table II). The fibrosing basal cell carcinoma, which was extremely rich in dense hyalinised, fibrous stroma, showed thin strands of basal cell carcinoma, with intense interepithelial fluorescence as brilliant as in the normal epidermis and at the same titre (Table II).

Unconjugated rabbit antihuman beta-2-m serum used at a dilution of 1:10 inhibited the staining completely in normal epidermis of conjugated rabbit antihuman beta-2-m at a dilution of 1:80.

In 10 solid basal cell carcinomas examined, inter-

Table II. Immunofluorescence reactions of FTC-antibeta-2-microglobulin at various dilutions, showing an intercellular pattern. Various types of basal carcinomas are compared with basal cell papillomas and normal skin

Diagnosis	Number	Intercellular pattern of FTC-conjugated antihuman beta-2-m Titre					
		1:10	1:20	1:40	1:80	1:160	1:320
Normal skin	34	34	34	34	34	34	34
Basal cell papilloma	8	8	8	8	8	8	8
Superficial basal cell carcinoma	3	0	0	0	0	0	0
Solid basal cell carcinoma	14	2 ^a	1 ^a	1 ^a	1 ^a	0	0
Solid basal cell carcinoma rich in connective tissue	3	3 ^a	2 ^a	2 ^a	2 ^a	1 ^a	0
Fibrosing basal cell carcinoma	1	1	1	1	1	1	1

^a Irregular staining, see text.

cellular staining observed with Con A and pemphigus antibodies did not differ from that of normal skin.

DISCUSSION

Nilsson et al. (7) have studied the production and cell surface expression of beta-2-m in 49 human cell lines of varying histogenetic origin and in 21 short-term cultures of normal and malignant lymphoid cells. The presence of beta-2-m on the cell surface was determined by indirect immunofluorescence. All cell lines except the Daudi line were brightly stained. In carcinoma cell lines the secretion of beta-2-m was very high, but the beta-2-m density on the cell surface proved to be somewhat lower than in normal blood lymphocytes and lymphoblastoid

cells (7). Since many features of cellular organization are greatly affected by cultivation of cells in vitro, these findings do not necessarily reflect the situation in vivo.

In 15 of the 20 cases of solid and superficial basal cell carcinoma in the present study, immunoreactive beta-2-m appeared to be absent, while it was readily detected in all basal cell papillomas examined (Table II).

The failure to detect beta-2-m on the cell surface may have several plausible explanations.

1. These antigens, when present on the cell surface of the malignantly transformed cells, could become reorganized into patches instead of being distributed evenly. However, beta-2-m would then be detectable in certain sections. The failure of the

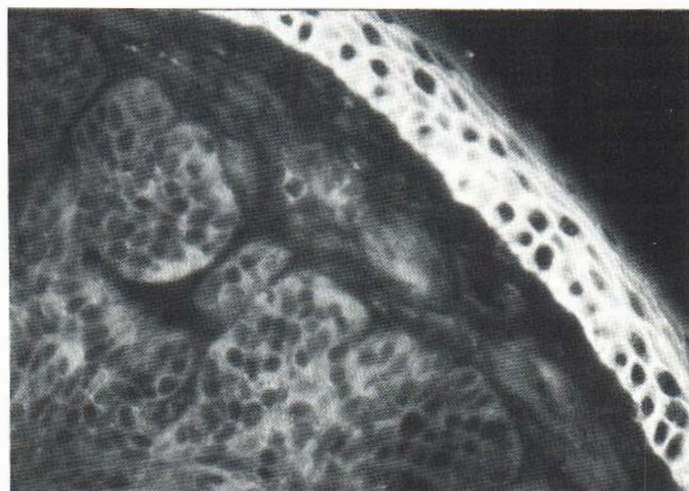

Fig. 2. Immunofluorescence pattern of a solid basal cell carcinoma incubated with FTC-labelled antihuman beta-2-microglobulin at a dilution of 1:10. The normal epidermis above the tumour shows an intense, interepithelial fluorescence, while the basal cell carcinoma tissue shows no fluorescence.

carcinoma tissue to show beta-2-m in any examined section of the 15 basal cell carcinomas mentioned above militates against this explanation.

2. The surface of the transformed cells could have lost all beta-2-m or else beta-2-m might be present in trace amounts only, not detectable with this method.

3. The cell surface might have been altered after malignant transformation in such a way that beta-2-m is no longer accessible to antibodies, or the beta-2-m peptide chain might have been modified slightly and thus no longer detectable with the specific antisera used.

That beta-2-m was found on the cell surface of the highly fibrosing basal cell carcinoma but not on most of the solid ones might simply mean that basal cell carcinomas are a heterogeneous group at the level of surface properties.

A conceivable explanation for the irregular pattern of fluorescence found in 5 of 17 solid basal cell carcinomas, is that normal cells might be intermingled with carcinoma tissue, either as an *in vivo* phenomenon or as a section artifact. The possibility of malignant transformation of a previously benign tumour must also be considered.

The absence or alteration of the antigenic expression of the cell surface beta-2-m as demonstrated in the present study might render these tumours increasingly unresponsive to controlling mechanisms involved in cell interactions and might reflect a disturbance of the gene regulation of beta-2-m on the cell surface of solid and superficial basal cell carcinomas.

ACKNOWLEDGEMENTS

Histopathological examinations were kindly carried out by Dr P. Westermark. The skilful technical assistance of Mrs J. Shull and Miss A. Westin is gratefully acknowledged.

This investigation was supported by grants from the Finsen Foundation and Edvard Welander Foundation.

REFERENCES

1. Cresswell, P., Springer, T., Strominger, J. L., Turner, M. J., Grey, H. M. & Kubo, R. T.: Immunological identity of the small subunit of HLA antigens and beta-2-microglobulin and its turnover on the cell membrane. *Proc Natl Acad Sci USA* 71: 2123, 1974.
2. Cresswell, P., Turner, M. J. & Strominger, J. L.: Papain-solubilized HLA antigens from cultured human lymphocytes contain two peptide fragments. *Proc Natl Acad Sci USA* 70: 1603, 1973.
3. Evrin, P. E. & Nilsson, K.: Beta-2-microglobulin production *in vitro* by human hematopoietic, mesenchymal and epithelial cells. *J Immunol* 112: 137, 1974.
4. Forsum, U. & Malmnäs Tjernlund, U.: Epidermal location of beta-2-microglobulin in human skin. *Acta Dermatovener (Stockholm)* 57: 121, 1977.
5. Grey, H. M., Kubo, R. T., Colon, S. M., Poulik, M. D., Cresswell, P., Springle, T. T., Turner, M. & Strominger, J. L.: The small subunit of HLA antigen is beta-2-microglobulin. *J Exp Med* 138: 1608, 1973.
6. Nakamuro, K., Tanigaki, N. & Pressman, D.: Multiple common properties of human beta-2-microglobulin and the common portion fragment derived from HLA-antigen molecules. *Proc Natl Acad Sci USA* 70: 2863, 1973.
7. Nilsson, K., Evrin, P. E. & Welsh, K. I.: Production of beta-2-microglobulin by normal and malignant human cell lines and peripheral lymphocytes. *Transplant Rev* 21: 53, 1974.
8. Peterson, P. A., Rask, L. & Lindblom, J. B.: Highly purified papain-solubilized HLA antigens contain beta-2-microglobulin. *Proc Natl Acad Sci USA* 71: 35, 1974.
9. Solheim, B. G., Rankin, B. & Holmboe, B.: Association of beta-2-microglobulin and HLA in the cell membrane. *Transplantation* 19: 281, 1975.
10. Tanigaki, N., Katagiri, M., Nakamuro, K., Kreiter, V. P. & Pressman, D.: Common antigenic structures of HLA antigens. *Immunology* 26: 155, 1974.
11. Östberg, L., Rask, L., Nilsson, K. & Peterson, P. A.: Independent expression of the two HLA antigen polypeptide chains. *Eur J Immunol* 5: 462, 1975.

Received December 6, 1976

U. Malmnäs Tjernlund, M.D.
Department of Dermatology
University Hospital
S-750 14 Uppsala
Sweden