

SHORT REPORTS

An Unusual Case of Benign Mucous Membrane Pemphigoid

Ch. I. Harrington and I. B. Sneddon

*The Rupert Hallam Department of Dermatology,
The Hallamshire Hospital, Sheffield, England*

Received February 21, 1977

Abstract. This case of benign mucous membrane pemphigoid (BMMP) is unusual in that blistering, scarring lesions were confined to the skin for 15 years before mucous membranes were involved. The onset of this disorder at the age of 38 is also unusual. Detailed immunological investigation was performed on this patient but the results in no way clarify the present confusion regarding the immunopathological processes in BMMP related to those operative in bullous pemphigoid.

Key words: Pemphigoid, cicatricial; Mucous membrane

CASE REPORT

This female patient developed recurrent blisters on the sides of the face in 1960 when aged 38 years. She was first seen in the Skin Department in 1966. The blistering and scarring lesions of the skin were typical of BMMP. A skin biopsy showed a subepidermal bulla with an acute inflammatory infiltrate. There were many eosinophils in the infiltrate and in the underlying dermis. She had no mucous membrane lesions. She was initially treated with Dapsone 50 mg twice a day but this produced no improvement. Prednisolone 15-30 mg was prescribed over the next year but again no benefit was achieved. In 1970 and 1971 skin grafts were performed over both temples and this produced freedom from blisters for 18 months.

In August 1972 blistering recurred and Azathioprine 150 mg daily was given, producing some improvement for 2 months. The patient then failed to attend. She reported to the clinic again in May 1973 having developed a gastric ulcer. All oral therapy was stopped and Metosyn® (ICI) cream was applied to the lesions. The patient again stopped attending.

She returned in August 1975 with a severe exacerbation of blisters on the face. In November 1975 she developed oral lesions and vulval erosions were noted in December 1975. On examination at that time there were bullae on the forehead, temples (Fig. 1), hard palate and vulva.

INVESTIGATIONS

Serum immunoglobulins: normal. C3 and C4 components of complement: normal. Desmosome and reticulin antibodies: negative. Basement membrane antibody not detected when using monkey oesophagus and normal human skin as substrates. Skin biopsy showed a subepidermal bulla containing extravasated red cells but no acantholytic epidermal cells. The dermis was oedematous and contained moderate numbers of inflammatory cells. Direct immunofluorescence performed on involved skin showed linear deposition of IgG and C3 along the basement membrane and when performed on uninvolved skin showed linear IgG staining along the basement membrane (Fig. 2).

Prednisolone 10 mg b.d. and Azathioprine 50 mg b.d. were given for 2 months but with no effect. The patient is currently applying Dermovate® (Glaxo) to the lesions and taking Azathioprine 50 mg three times a day.

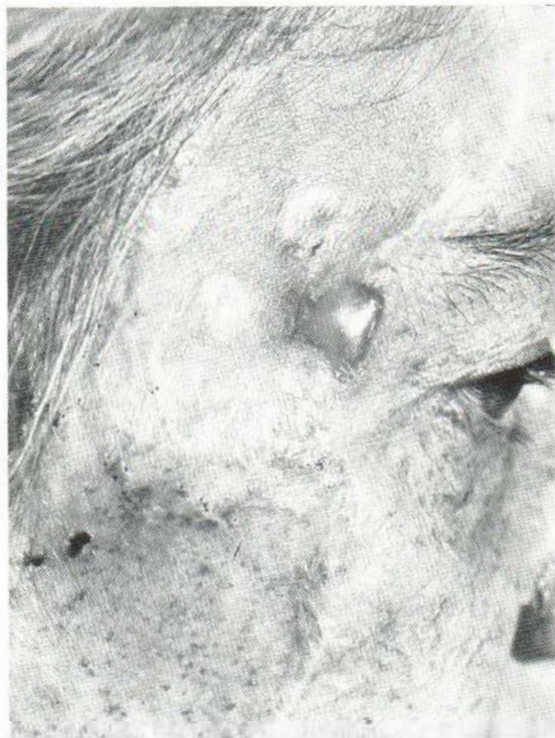

Fig. 1. Bullae and scarring on skin-grafted area of the right temple.

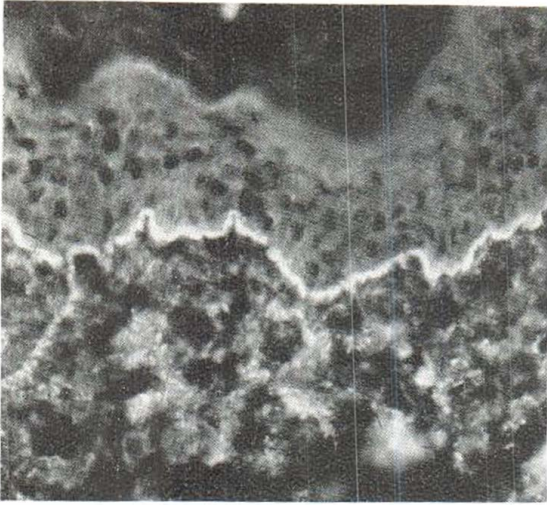


Fig. 2. Direct immunofluorescence using fluorescein-isothiocyanate conjugated rabbit antihuman antiserum for IgG on clinically normal skin, showing linear IgG deposition along the basement membrane. $\times 18$.

DISCUSSION

There are several unusual and interesting features in this patient. BMMP occurred at an unusually early age (7, 8). Skin lesions are not a common feature of this disorder (6, 7). In the rare event of skin lesions appearing first, the average duration before the onset of mucosal lesions is 3 years! There is, however, a group of patients who have the scarring skin lesions of BMMP but never develop mucous membrane lesions (2).

Until recently direct and indirect immunofluorescence in BMMP had been negative. This led to the suggestion that this disorder was distinct from bullous pemphigoid. However, it is now evident that circulating basement membrane antibody and basement membrane staining for IgG and sometimes C3 occur in BMMP (1, 3, 4, 5, 9).

In this patient direct immunofluorescence showed basement membrane staining for IgG and C3 in involved skin and for IgG in uninvolved skin. We were unable to demonstrate circulating basement membrane antibody and our intention to overcome the problem of species or tissue specificity by using the patient's serum against her own uninvolved skin was thwarted by finding IgG in her clinically normal skin. This finding stresses the importance of studying patients' uninvolved skin by direct immunofluorescence before using it for indirect immunofluorescence.

The finding of IgG basement membrane antibodies in uninvolved skin throws doubt on their role in blister formation but, conversely, C3 fixation in affected skin does suggest an auto-antibody pathogenesis. The 15-year history of lesions confined to the skin in this patient questions the theory that in BMMP auto-antibodies are directed predominantly against mucous membranes, with skin involvement occurring only when there is cross antigenicity.

There are two possibilities capable of explaining the sequence of events in this case. If the antibodies are auto-aggressive they are directed primarily against the skin, but loss of specificity after 15 years resulted in their also affecting mucous membranes. Alternatively, some non-immunological primary change in the skin may have rendered it antigenic, thus stimulating production of antibodies which eventually became aggressive to the mucous membranes.

REFERENCES

1. Bean, S. F.: Cicatricial pemphigoid. *Arch Dermatol* 110: 552, 1974.
2. Brunsting, L. A. & Perry, H. O.: Benign pemphigoid? *Arch Dermatol* 75: 489, 1957.
3. Dantzig, P.: Circulating antibodies in cicatricial pemphigoid. *Arch Dermatol* 108: 264, 1973.
4. Griffith, M. R., Fukuyama, K., Tuffanelli, D. & Silverman, S.: Immunofluorescent studies in mucous membrane pemphigoid. *Arch Dermatol* 109: 195, 1974.
5. Holubar, K., Honigsmann, H. & Wolff, K.: Cicatricial pemphigoid: immunofluorescent investigations. *Arch Dermatol* 108: 50, 1973.
6. McCarthy, P. L. & Shklar, G.: Benign mucous membrane pemphigus. *N Engl J Med* 258: 726, 1958.
7. Shklar, G. & McCarthy, P. L.: Oral lesions of mucous membrane pemphigoid: a study of 85 cases. *Arch Otolaryngol* 93: 354, 1971.
8. Sneddon, I. B.: Discussion on bullous conditions of the skin and conjunctiva. *Proc Roy Coll Med* 54: 107, 1961.
9. Tagami, H. & Imamura, S.: Benign mucous membrane pemphigoid: demonstration of circulating and tissue-bound membrane antibodies. *Arch Dermatol* 109: 711, 1974.