

THE NITROBLUE TETRAZOLIUM TEST IN ACNE VULGARIS

M. M. Roberts, S. G. Tan, W. J. Cunliffe and J. A. Cotterill

From the Department of Dermatology, The General Infirmary at Leeds, England

Abstract. The nitroblue tetrazolium (N.B.T.) test has been studied in 19 patients with moderate or severe acne vulgaris and 18 patients with subclinical or no acne. There was a significant elevation of the N.B.T. score in those patients with moderate or severe acne as compared with the control group. This is probably a result of the inflammatory reaction in and around the involved sebaceous gland follicles.

Key words: Nitroblue tetrazolium test; Neutrophil polymorph function; Acne vulgaris

The nitroblue tetrazolium (N.B.T.) test was first introduced by Park et al. in 1968 (6) as a laboratory aid to the diagnosis of bacterial infection. Since then, several workers have shown that this test may give elevated results in many non-bacterial conditions including various skin diseases (1, 2, 3, 8). Acne vulgaris is not generally considered to result from primary bacterial infection, although *Corynebacterium acnes*—and to a lesser extent *Staphylococcus epidermidis*—are likely to be implicated indirectly in the pathogenesis. However, in the inflammatory stages of acne, many polymorphs are present in the lesion and Juhlin (5) found an increase in basophil leukocytes in cantharidin-induced blisters in acne subjects. It seemed reasonable, therefore, to assess one aspect of neutrophil function in acne using the N.B.T. test.

METHOD

19 patients (13 females, 6 males; mean age 21.8 ± 1.0 years) with moderate or severe acne were compared with a control group of 18 patients (10 females, 8 males; mean age 20.6 ± 0.5 years) who had subclinical or no acne. Neither control subjects nor acne patients were receiving any systemic therapy during the 6 weeks prior to or during the study. The patients were assessed clinically by independent observers (W. J. C. and S. G. T.) and those with moderate or severe acne were seen on two occa-

sions. The severity of the acne was graded according to the percentage of inflammatory lesions present on the face, back and chest, namely: 0-24% = mild, 25-59% = moderate, 60-100% = severe. No subject had mild acne, 13 subjects were graded as having moderate acne and 19 subjects as having severe acne. The N.B.T. test was performed on samples of blood withdrawn at the time of clinical assessment. The method of Park et al. (6) as modified by Freeman & King (4) was used to calculate the percentage of formazan-positive neutrophil polymorphs.

RESULTS

The results are shown in Fig. 1. There was a highly significant difference between the N.B.T. score in those patients with moderate acne, compared with the control group ($p < 0.005$) and between the N.B.T. score in severe acne, compared with the

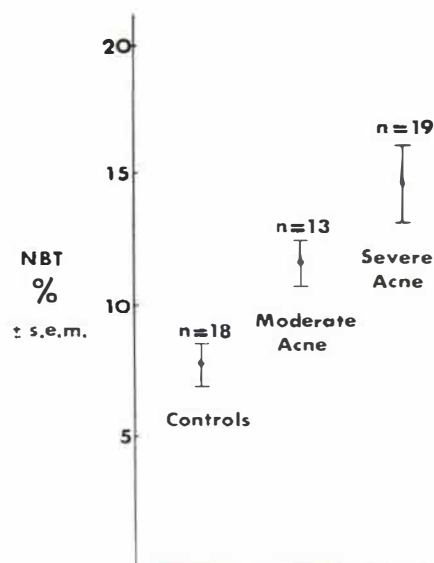


Fig. 1. The N.B.T. score in acne and control subjects (n = number of observations).

control group ($p < 0.001$). There was no significant difference between the groups of patients with moderate or severe skin involvement ($p < 0.1$).

DISCUSSION

Czarnetzki et al. (3) have investigated the N.B.T. test in various dermatological disorders and found that 5 of the 10 acne patients examined had an elevated N.B.T. score, but their data was not related to activity or severity of the acne.

We have shown that the N.B.T. score may be elevated in patients with moderate or severe acne and that the score is higher in those patients with the more severe grades of inflammatory skin involvement. Polymorph function has not been assessed in patients with acute febrile ulcerative conglobate acne who have shown a leukaemoid reaction (7). The N.B.T. test and other tests of white cell function could help to explain some of the features of this atypical form of acne.

Our data is further evidence that the N.B.T. test may give a false positive result in the presence of another dermatological condition, acne vulgaris, which is usually regarded as a non-disease by colleagues in other specialties and therefore likely to be overlooked. In this condition, the test is presumably elevated in response to the inflammatory process in and around the involved sebaceous gland follicles.

REFERENCES

1. Allen, H. B.: The nitroblue tetrazolium dye test in dermatological disorders. *Cutis* 12: 707, 1973.
2. Cotterill, J. A., Roberts, M. M., Freeman, R., King, B. & Mostoufi, K.: Aspects of polymorph function in psoriasis. *Proc Roy Soc Med* 67: 874, 1974.
3. Czarnetzki, B. M., Fountain, M. & Belcher, R. W.: The nitroblue tetrazolium test in dermatologic patients. *Arch Dermatol* 109: 36, 1974.
4. Freeman, R. & King, B.: Technique for the performance of the nitroblue tetrazolium (N.B.T.) test. *Clin Pathol* 25: 912, 1972.
5. Juhlin, L.: Basophil leukocytes in acne. *Invest Dermatol* 45: 22, 1965.
6. Park, B. H., Fikrig, S. M. & Smithwick, E. M.: Infection and nitroblue tetrazolium reduction by neutrophils—a diagnostic aid. *Lancet* II: 532, 1968.
7. Ström, S., Thyresson, N. & Boström, H.: Acute febrile ulcerative conglobate acne with leukemoid reaction. *Acta Dermatovener (Stockholm)* 53: 306, 1973.
8. Tan, C. V., Rosner, F. & Feldman, F.: Nitroblue tetrazolium dye reduction in various haematological disorders. *NY State J Med* 73: 952, 1973.

Received October 13, 1975

M. M. Roberts, M.B.
Department of Dermatology
The General Infirmary at Leeds
Leeds LS1 3EX
England